

# Emedastine Difumarate Inhibits Histamine-Induced Collagen Synthesis in Dermal Fibroblasts

H Murota,<sup>1</sup> S Bae,<sup>2</sup> Y Hamasaki,<sup>3</sup> R Maruyama,<sup>4</sup> I Katayama<sup>1</sup>

<sup>1</sup>Department of Dermatology, Course of Integrated Medicine, Osaka University School of Medicine, Osaka, Japan

<sup>2</sup>Department of Dermatology, Nagasaki University Graduate School of Biomedical Sciences, Nagasaki, Japan

<sup>3</sup>Department of Dermatology, Dokkyo University School of Medicine, Tochigi, Japan

<sup>4</sup>Maruyama Dermatology Clinic, Tokyo, Japan

## ■ Abstract

*Background:* Mast cell-derived histamine is known to act on dermal fibroblasts and contribute to formation of an intractable chronic allergic dermatitis. Although this fibrotic event may also occur in other organs such as the nasal mucosa, no direct evidence has been reported as to whether responsiveness to histamine by fibroblasts derived from different organs is of the same intensity. Furthermore, while type 1 histamine receptor (H1R) blockers have been shown to be effective for alleviation of the symptoms of allergic diseases, their ability to affect histamine-induced tissue remodeling has not yet been clarified.

*Objective:* Our aim was to study the effect of H1R-blockers on histamine-induced tissue remodeling.

*Methods:* A macroarray assay was used for a comprehensive analysis of histamine-induced gene expression by normal human fibroblasts. Fibroblasts derived from skin or nasal mucosa were cultured in the presence of various concentrations of histamine, and the synthesis of type 1 collagen was measured by means of semi-quantitative reverse-transcriptase polymerase chain reaction and enzyme-linked immunosorbent assay. To determine the effect of H1R blockers, diphenhydramine hydrochloride and emedastine difumarate were investigated in this assay.

*Results:* Histamine induced expression of various kinds of fibrogenic molecules in fibroblasts. Increased type 1 collagen expression was observed in fibroblasts treated with high-dose (0.1 mM to 1  $\mu$ M) and low-dose (1 pM) histamine. This histamine-induced type 1 collagen synthesis was effectively diminished by emedastine difumarate. While organ specificity seems to be involved, emedastine difumarate is considered to be an effective drug for reversal of such histamine-induced remodeling in the skin.

*Conclusions:* We found that the expression of fibroblast-derived genes is differentially regulated by different concentrations of histamine and that the robustness of the inhibitory action of H1R blockers is different for skin-derived and nasal mucosa-derived fibroblasts. We believe that our findings may contribute to a better understanding of the mechanisms of histamine-induced tissue remodeling and provide information useful for the management of refractory allergic dermatitis.

**Key words:** Histamine. Fibroblasts. Collagen. Antihistamines. Emedastine difumarate. Tissue remodeling. Atopic dermatitis.

## ■ Resumen

*Antecedentes:* Se ha constatado que la histamina derivada de los mastocitos actúa sobre los fibroblastos dérmicos y contribuye al desarrollo de dermatitis alérgica crónica resistente al tratamiento. Aunque este episodio fibrótico puede darse también en otros órganos como la mucosa nasal, no disponemos de ninguna evidencia directa de que la reactividad de los fibroblastos a la histamina derivada de distintos órganos sea de la misma intensidad. Además, mientras que se ha demostrado que los antagonistas de los receptores de la histamina de tipo 1 (RH1) resultan efectivos para el alivio de los síntomas de las enfermedades alérgicas, aun no se ha esclarecido su capacidad de influencia en los procesos de remodelación de los tejidos, inducidos por la histamina.

*Objetivo:* Nuestro objetivo fue estudiar el efecto de los antagonistas-RH1 en los procesos de remodelación del tejido inducidos por la histamina.

**Métodos:** Se utilizó una técnica de macroarray para analizar exhaustivamente la expresión génica inducida por la histamina de los fibroblastos humanos normales. Los fibroblastos derivados de la piel o de la mucosa nasal se cultivaron en presencia de diversas concentraciones de histamina y se calculó la síntesis del colágeno de tipo 1 mediante la reacción en cadena de la polimerasa retrotranscriptasa semicuantitativa y enzimoimmunoanálisis de adsorción. Para determinar el efecto de los antagonistas de los RH1, en este análisis se estudiaron el hidrocloreto de difenhidramina y el difumarato de emedastina.

**Resultados:** La histamina indujo la expresión de diversos tipos de moléculas fibrogénicas en los fibroblastos. Se observó un aumento de la expresión del colágeno de tipo 1 en los fibroblastos tratados con dosis elevadas (1  $\mu$ M hasta 0,1 mM) y dosis bajas (1 pM) de histamina. El difumarato de emedastina disminuyó de modo efectivo la síntesis de colágeno de tipo 1 inducida por la histamina. Mientras que la especificidad orgánica parece estar implicada, el difumarato de emedastina se considera un fármaco capaz de revertir dicho proceso de remodelación inducido por la histamina en la piel.

**Conclusiones:** Encontramos que la expresión de los genes derivados del fibroblasto se regula diferencialmente mediante diferentes concentraciones de histamina y que la potencia de la acción inhibitoria de los antagonistas de los RH1 no es igual para los fibroblastos derivados de la piel que para los que derivan de la mucosa nasal. Creemos que nuestras observaciones pueden contribuir a una mejor comprensión de los mecanismos de los procesos de remodelado de los tejidos inducidos por la histamina y pueden proporcionar una información interesante para el tratamiento de la dermatitis alérgica resistente al tratamiento.

**Palabras clave:** Histamina. Fibroblastos. Colágeno. Antihistamínico. Difumarato de emedastina. Procesos de remodelación de los tejidos. Dermatitis atópica.

## Introduction

The process known as tissue remodeling and repair is thought to be an underlying cause of refractory allergic diseases such as asthmatic diseases and atopic dermatitis (AD). Based on a generally accepted definition by the Global Initiative for Asthma, it has been proposed that tissue remodeling contributes to (1) reconstitution and repair of inflammatory tissue injuries, (2) irreversibility or intractability of the process, and (3) persistence of allergic inflammation [1]. In view of these considerations, tissue remodeling appears to participate in the prolongation of chronic allergic reactions rather than in repair of tissue damaged by allergic inflammation.

AD has been demonstrated to be a feature of the tissue remodeling process during the progression from acute to subacute and chronic inflammation. In the epidermis of lesional skin, inflammatory cell infiltration, spongiosis, and acanthosis are commonly observed [2], while marked characteristics of tissue remodeling have been identified in AD-associated skin lesions, especially in the dermis. Edematous changes and perivascular infiltration of lymphocytes, eosinophils, neutrophils, and basophils occur in the early stage of AD [3]. Prolonged inflammation leads to an increase in the number of dermal fibroblasts, mast cells, and collagen bundles, and a greater number of mast cells has been found in AD skin lesions than in nonlesional skin [4]. The mechanisms underlying these tissue reactions can be partly explained by the activating or proliferating effect of mast cell-derived chemical mediators such as histamine on fibroblasts.

Histamine has distinct effects on dermal fibroblasts, effects which are characterized by increased synthesis of type 1 collagen [5] and glycosaminoglycans [6], and augmentation of fibrogenic cytokine-induced fibroblast proliferation [7]. However, there has been little or no direct evidence as to whether the effects of histamine on fibroblasts derived from different tissues are expressed at the same level.

In this study, we analyzed histamine-induced gene expression in fibroblasts. We used reverse-transcriptase polymerase chain reaction (RT-PCR) and enzyme-linked immunosorbent assay (ELISA) to investigate the effects of various concentrations of histamine on the synthesis of type 1 collagen. We also examined the effect of inhibitors of the histamine H1 receptor (H1R) on histamine-induced gene expression.

## Materials and Methods

### Cell Culture

Normal human dermal fibroblasts (NHDFs) were cultured in Dulbecco's modified Eagle medium (DMEM) supplemented with 10% fetal calf serum at 37°C in 5% CO<sub>2</sub>.

### Primary Culture of Fibroblasts

For isolation of dermal fibroblasts, minced adult skin samples obtained with informed consent during surgical operations were treated with 0.2% collagenase (Sigma, St Louis, Missouri, USA) at 37°C for 1 hour. The isolated dermal fibroblasts were cultured in DMEM supplemented with 10% fetal calf serum at 37°C in 5% CO<sub>2</sub>. For isolation of nasal mucosa-derived fibroblasts, extirpated nasal polyps were used and cells were prepared in the same manner as for dermal fibroblasts.

### Treatment With H1R Blockers

Emedastine difumarate and diphenhydramine hydrochloride (gifts from Kowa Pharmaceutical Company, Tokyo, Japan) were dissolved in DMEM. The emedastine difumarate dosages were 0.1, 1, 10  $\mu$ g/mL and the diphenhydramine hydrochloride dosage was 1  $\mu$ g/mL. After 24 hours of culture with these compounds, conditioned medium and total RNA were harvested for ELISA and RT-PCR.

### Determination of the Number of Mast Cells

Paraffin sections from cases with various kinds of skin disease (atopic dermatitis, n=13; psoriasis vulgaris, n=9; prurigo nodularis, n=14; contact dermatitis, n=5; drug eruption, n=4) and from healthy control subjects (n=6) were stained with Giemsa. Mast cells in the upper dermis were counted as the number of cells per unit area with a depth of 450  $\mu$ m from the basement membrane and a width of 1 mm. Data were expressed as the mean (SD).

### Immunohistochemical Staining for Tryptase-Positive Mast Cells

A 4  $\mu$ m paraffin section from an atopic dermatitis skin lesion was deparaffinized and heated for antigen retrieval. The primary antibodies recognized tryptase (1:50; DAKO, Santa Fe, California, USA). Staining was done with the streptavidin-biotin amplification LSAB2 system (DAKO).

### Macroarray Assay

NHDFs were cultured on 10-cm culture dishes. At the subconfluent stage, they were incubated with or without 1  $\mu$ M histamine (Sigma) for 6 hours. Total RNA was isolated with the RNeasy kit (QIAGEN GmbH, Hilden, Germany). The PANORAMA human cytokine gene arrays (Sigma Genosys) assay was performed according to the manufacturer's instructions.  $^{32}$ P-labeled complementary DNA (cDNA) was prepared using the oligo(dT) primers provided. After purification of labeled cDNAs using spin columns, the cDNAs were hybridized to the PANORAMA gene array. Quantitation of gene expression signals was performed with a BAS5000 image analyzer (Fujifilm, Tokyo, Japan).

### RT-PCR

Total RNA was extracted with the RNeasy Mini kit (QIAGEN GmbH) according to the protocol supplied by the manufacturer. First-strand cDNA was synthesized with an RT-PCR kit (Stratagene, La Jolla, California, USA) using oligo-dT primers, followed by amplification of the cDNA for 25 cycles. The following oligonucleotide primers were used for RT-PCR: procollagen  $\alpha$ 1 (I), 5'-TAC AGC ACG CTT GTG GAT G-3' (sense) and 5'-TTG AGT TTG GGT TGT TGG TC-3' (antisense); glyceraldehyde-3-phosphate dehydrogenase (GAPDH), 5'-ACC ACAGTC CAT GCC ATC AC-3' (sense) and 5'-TCC ACC ACC CTG TTG CTG TA-3' (antisense). Relative gene expression levels were expressed as the ratio of procollagen  $\alpha$ 1 (I) to GAPDH (internal standard). Gene expression levels were calculated using ImageJ software (NIH, Bethesda, Maryland, USA).

### ELISA

The production of type I collagen was determined by ELISA, for which microtiter wells were coated with the samples dissolved in 50 mM carbonate buffer (pH 9.0) overnight at 4°C. The wells were then washed 3 times with 300  $\mu$ L of 0.05% Tween 20 in phosphate-buffered saline (PBS) and nonspecific binding sites were blocked with 1% bovine serum albumin in PBS for 1 hour. After washing, anti-human type I collagen antibody (Sigma), diluted 1:1000 in PBS containing

0.05% Tween 20, was added to the wells and incubated for 2 hours. This was followed by another wash and the addition of horseradish peroxidase-conjugated rabbit anti-mouse antibody (Dako, Glostrup, Denmark), diluted 1:1000 in PBS containing 0.05% Tween 20, to the wells and incubation for 1 hour. After washing, the reaction was developed with K-Blue Aqueous substrate (Neogen, Lexington, Kentucky, USA) for 20 minutes. After the reaction was terminated with 50  $\mu$ L of 1N HCl, absorbance was read at 450 nm. Next, a standard curve was constructed using purified human skin type I collagen (Calbiochem, Darmstadt, Germany) diluted in PBS ranging in concentration from 1 ng/mL to 1  $\mu$ g/mL.

### Statistical Analysis

Statistical analysis was performed with Prism4 software (GraphPad Software Inc, San Diego, California, USA). Multivariable comparisons of means were performed by Kruskal-Wallis nonparametric test. Subsequently, the comparisons of means between pairs of groups were performed by Dunn multiple comparison test.  $P < .05$  was considered statistically significant.

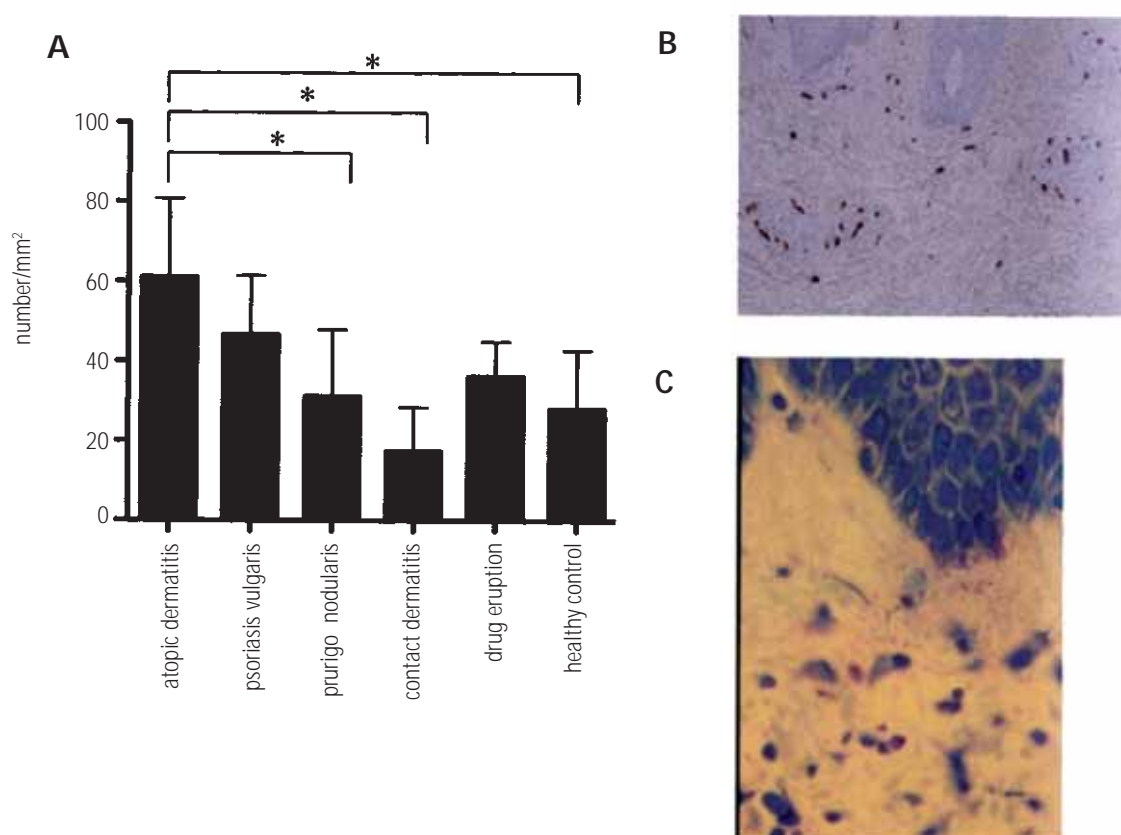
## Results

### Increase in Mast-Cell Number in Atopic Dermatitis Lesions

A comparison of the number of mast cells in various kinds of inflammatory skin disease is shown in Figure 1A. Skin lesions from atopic dermatitis, psoriasis vulgaris, prurigo nodularis, and drug eruption contained a larger number of mast cells than did skin sections from healthy controls. It is noteworthy that the number of mast cells was significantly increased in atopic dermatitis lesions compared with prurigo nodularis, contact dermatitis, and healthy controls ( $P < .05$ ), while contact dermatitis lesions contained even fewer mast cells than seen in healthy controls. In atopic dermatitis lesions, tryptase-positive cells and degranulated mast cells were frequently observed (Figure 1B, C). Since skin fibrosis is often observed in the chronic phase of atopic dermatitis, and it has been reported that excessive tissue remodeling contributes to the pathogenesis of atopic dermatitis, psoriasis vulgaris, and prurigo nodularis [8-10], our findings suggest that mast cell degranulation is actively involved in generating dermal fibrosis in these dermatoses.

### Comprehensive Analysis of Gene Expression in Histamine-Treated NHDF

To further analyze the role of mast-cell degranulation, we generated gene expression profiles in histamine-treated NHDF. The macroarray assay showed that various genes linked to tissue remodeling, such as FGF18, VEGFB, INHBA, BMP7, TGFBI, and TGFBR3, are transactivated in histamine-treated NHDF (Figure 2). Fibroblast growth factor (FGF) 18 and vascular endothelial growth factor (VEGF) B are known to act on endothelial cells and cause migratory activity and neoangiogenesis, respectively [11,12]. Activin A (encoded by the INHBA gene), transforming growth factor (TGF)  $\beta$ 1,



**Figure 1.** Accumulation of mast cells in atopic dermatitis skin lesions. A, Bars show mean values for the number of dermal mast cells in various skin diseases; whiskers show SD. Asterisks (\*) indicate  $P < .05$ . B, Immunohistochemistry for tryptase in atopic dermatitis skin lesion (original magnification,  $\times 200$ ). C, Giemsa stain showing accumulation of mast cells with dark blue granules in the upper dermis of a skin lesion of atopic dermatitis (original magnification,  $\times 400$ ).

		Control	HT
FGF-Family	FGF18		
Angiogenic Factor	VEGF-B		
TGF- $\beta$ Superfamily	Activin A		
	BMP-7		
	TGF- $\beta_1$		
	TGF- $\beta$ RIII		
House Keeping	$\beta$ actin		

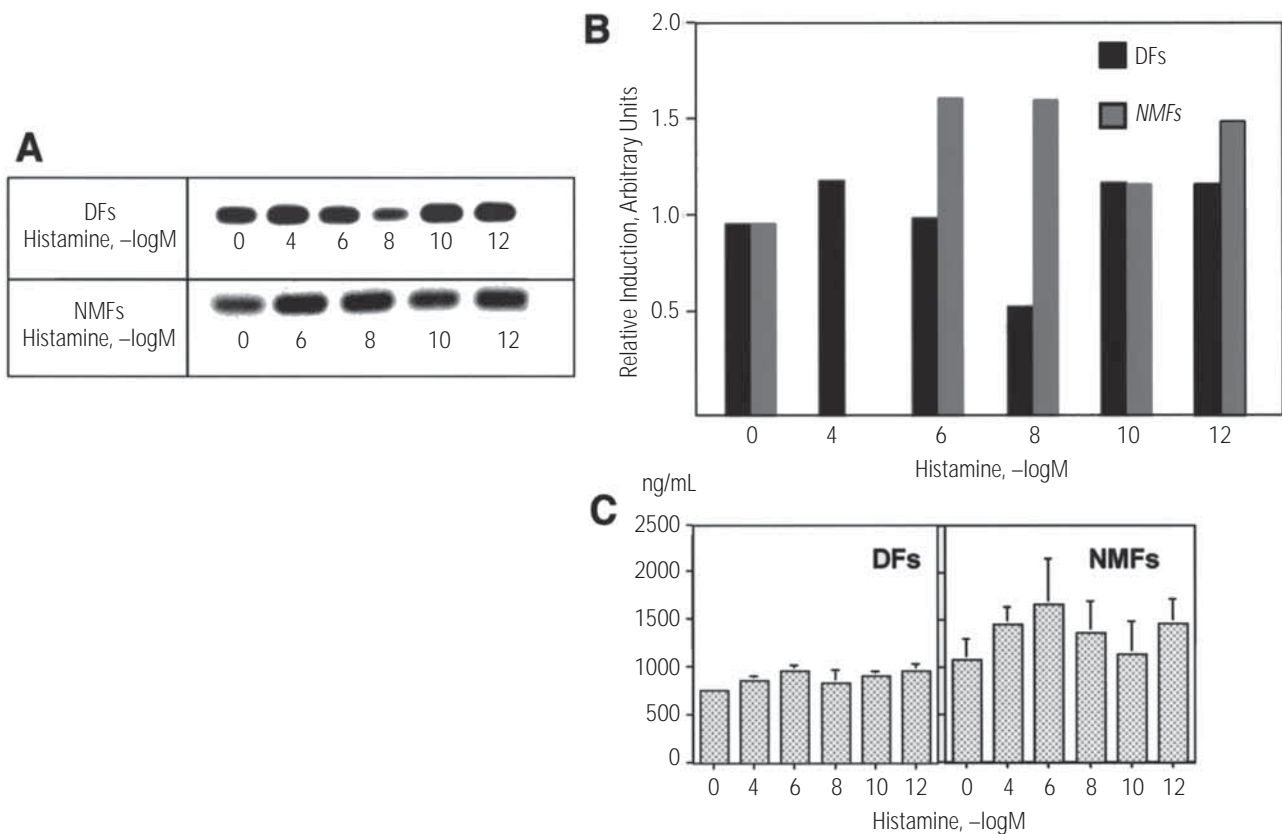
**Figure 2.** Expression of genes associated with tissue remodeling in histamine-treated normal human dermal fibroblasts. The results of macroarray analysis are shown. Each gene was arrayed in duplicate. BMP indicates bone morphogenetic protein; FGF, fibroblast growth factor; HT, histamine treated; TGF, transforming growth factor; TGF- $\beta$ RIII, TGF- $\beta$  receptor III; VEGF, vascular endothelial cell growth factor.

both members of the TGF $\beta$  superfamily, and TGF $\beta$  receptor III have long been recognized as major players in tissue repair, fibrosis, and inflammation [13,14], while bone morphogenetic protein (BMP) 7, also a member of the TGF- $\beta$  superfamily, was originally identified as an inducer of cartilage and bone formation [15]. In recent years, however, additional functions of BMP-7 have been discovered, including that of an inhibitor of hair follicle formation [16]. Thus, the expression of these genes in histamine-treated NHDF indicates that histamine may perform a variety of functions in the tissue remodeling process via activation of dermal fibroblasts.

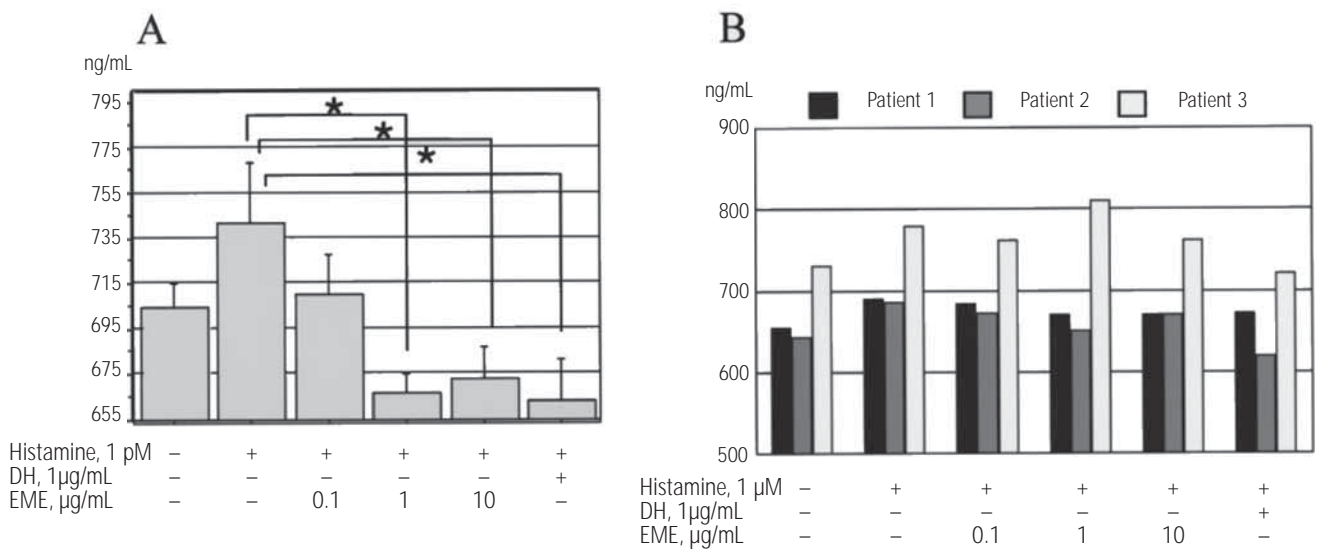
### Synthesis of Type 1 Collagen in Histamine-Treated Dermal Fibroblasts

As mentioned, type 1 collagen is synthesized by fibroblasts and is thought to play an important role in tissue remodeling and fibrosis. Histamine may induce type 1 collagen expression in fibroblasts via a direct or indirect pathway, including

production of fibrogenic cytokines, as shown in Figure 2. Next, we addressed whether histamine generates the same response in fibroblasts derived from different tissues. To this end, we used RT-PCR to analyze transcripts of procollagen  $\alpha 1$  (I) mRNA in dermal fibroblasts or nasal mucosa-derived fibroblasts following treatment with various concentrations (1 pM to 0.1  $\mu$ M) of histamine (Figure 3A, B). The response of type 1 collagen synthesis to histamine in nasal mucosa-derived fibroblasts was stronger than that observed in dermal fibroblasts but, interestingly, histamine induced an inverted bell-shaped dose-response curve for expression of procollagen  $\alpha 1$  (I) mRNA in both dermal fibroblasts and nasal mucosa-derived fibroblasts. Furthermore, ELISA confirmed the reproducibility of the outcomes of RT-PCR (Figure 3C). These findings indicate that, although histamine-induced responsiveness seems to be different for fibroblasts derived from different tissues, the response of type 1 collagen synthesis in both dermal and nasal mucosa-derived fibroblasts is similar for the same dose of histamine treatment.



**Figure 3.** In both dermal fibroblasts and nasal mucosa-derived fibroblasts, histamine induces type 1 collagen synthesis following an inverted bell-shaped dose-response curve. **A**, Results of reverse-transcriptase polymerase chain reaction for pro-collagen  $\alpha 1$  (I) mRNA at various concentrations of histamine. **B**, Comparison of pro-collagen  $\alpha 1$  (I) mRNA densities as assessed by densitometry. Treatment with 0.1  $\mu$ M histamine was not performed in nasal mucosa-derived fibroblasts. Bars indicate the mean of 3 cases for dermal fibroblasts and 2 cases for nasal mucosa-derived fibroblasts. **C**, Comparison of type 1 collagen production in 3 cases each of histamine-treated dermal fibroblasts and nasal mucosa-derived fibroblasts. Bars show mean values and whiskers SD. DF indicates dermal fibroblasts; NMF, nasal mucosa-derived fibroblasts.



**Figure 4.** Emedastine difumarate inhibits histamine-induced type 1 collagen synthesis in dermal fibroblasts. **A**, Comparison of type 1 collagen production in dermal fibroblasts treated with 1 pM histamine with or without histamine H1 receptor blockers. Experiments were performed on dermal fibroblasts obtained from 3 individuals. Bars shown mean values and whiskers indicate SD; asterisks (\*),  $P < .05$ . **B**, Comparison of type 1 collagen production in nasal mucosa-derived fibroblasts treated with 1 μM histamine with or without histamine H1 receptor blockers. Experiments were performed on nasal mucosa-derived fibroblasts obtained from 3 individuals. Values represent the concentrations of type 1 collagen from 3 different supernatants. DH indicates diphenhydramine hydrochloride; EME, emedastine difumarate.

### *Emedastine Difumarate Inhibits Histamine-Induced Synthesis of Type 1 Collagen in Dermal Fibroblasts*

To investigate the effect of H1R inhibitors on histamine-induced type 1 collagen synthesis in dermal fibroblasts and nasal mucosa-derived fibroblasts, histamine-treated cells were cultured with first-generation (diphenhydramine hydrochloride) or second-generation (emedastine difumarate) H1R inhibitors. In the case of dermal fibroblasts, ELISA for detection of type 1 collagen in conditioned medium showed that 0.1 μg/mL emedastine difumarate inhibited histamine-induced collagen synthesis to the same extent as observed in vehicle-treated cells. Addition of diphenhydramine hydrochloride or high concentrations of emedastine difumarate to the culture medium both led to statistically significant inhibition of type 1 collagen production (Figure 4A). In the case of nasal mucosa-derived fibroblasts, on the other hand, individual differences were observed in the effect of emedastine difumarate, while diphenhydramine hydrochloride suppressed histamine-induced type 1 collagen synthesis in 3 cases (Figure 4B). These results indicate that the effect of emedastine difumarate may be tissue specific, but not that of diphenhydramine hydrochloride.

## Discussion

The results of this study may provide insights into novel functional aspects of histamine in chronic allergic diseases. Histamine has been demonstrated to have multiple roles such as that of a chemical mediator in the immune response and

a neurotransmitter in gastric acid production [17] and in the maintenance of the blood-brain barrier, along with hormonal functions and roles in sleep, food intake, thermoregulation, and locomotor activity [18]. These findings indicate that histamine is essential for maintaining homeostasis in living organisms.

However, an excessive response to histamine has been shown to play an important role in the pathogenesis of chronic allergic diseases, including atopic dermatitis. Moreover, fibroblasts may be candidates for histamine-responsive cells and contribute to the development of chronic dermatitis. This possibility is supported by the observation that production of inflammatory chemokines such as eotaxin, a potent eosinophil-specific chemotactic factor, was found to be induced in fibroblasts in a dose-dependent fashion [19]. Furthermore, one study found that histamine enhanced fibroblast proliferation in a dose-dependent manner, with an optimum effect at a physiological concentration of 0.1 μM histamine [20]. In our study, dermal fibroblasts and nasal mucosa-derived fibroblasts were also stimulated at several concentrations (from 1 pM to 0.1 mM) of histamine. Unexpectedly, type 1 collagen was synthesized with a reverse bell-shaped dependence on histamine stimulus, showing a peak response at 0.1 mM, 1 μM, or 1 pM. ELISA with conditioned medium revealed a dose-dependent increase in the concentration of eotaxin in response to histamine treatment (data not shown). This dose-dependent action of histamine indicates that high concentrations of histamine may cause both inflammation and tissue remodeling, while lower concentrations may cause only tissue remodeling.

Our comprehensive study of gene expression in histamine-

treated NHDF revealed that histamine can induce the expression of various kinds of genes associated with the tissue remodeling process. Histamine is believed to play an important role in the wound-healing process, and indeed, disruption of histamine in histidine decarboxylase gene knockout mice resulted in delayed cutaneous wound healing, and the phenotype was rescued by exogenous histamine administration [21]. In that study, the mechanism underlying delayed wound healing was explained in terms of the impaired expression of histamine-activated basic fibroblast growth factor, which leads to angiogenesis and macrophage recruitment in the wound-healing process. The results of our study showed that genes encoding angiogenic factors such as VEGF-B and FGF18 were expressed by histamine-treated NHDF. Both VEGF-A and VEGF-B are known to be expressed in dermal fibroblasts and keratinocytes [22-24], and although fibroblasts treated with tumor necrosis factor  $\alpha$  or TGF $\beta$ , or irradiated with UV-A were found to be capable of releasing VEGF-A [22,23], these stimuli did not affect the expression of VEGF-B [24]. Taken together with the results of our study, these findings indicate that histamine could be a novel candidate for the previously unidentified factor inducing VEGF-B expression in fibroblasts. As VEGF is also known to function as a chemotactic factor for mast cells as well as endothelial cells [25], histamine-induced VEGF expression may be a contributing factor in allergic inflammation. On the other hand, little is known about the function of FGF18 in the skin, although a recent study found that FGF18 was strongly expressed during the anagen phase in the inner root sheath and during telogen in the hair follicles, and that subcutaneous injection of exogenous FGF18 resulted in vigorous hair growth [26]. In contrast, as mentioned earlier, BMP-7, an inhibitor of hair follicle formation, was also released from histamine-treated NHDF [16]. Taking all these findings into account, we predict that histamine may be important for the regulation of hair growth and maintenance of the skin. Moreover, we speculate that, if the balance between FGF18 and BMP-7 is altered, phenotypes such as hirsutism or hair loss (eg, the Hertoghe sign in atopic dermatitis) may appear in chronic allergic diseases. Further studies will be necessary to confirm this hypothesis.

Histamine-induced expression of type 1 collagen in dermal fibroblasts was dramatically inhibited by emedastine difumarate. The robustness of this inhibitory effect identifies it as the strongest drug among 5 different second-generation H1R-blockers (data not shown). For this reason, emedastine difumarate should be considered the most useful second-generation H1R-blocker for treating the scleroderma that is frequently observed in atopic dermatitis. Unexpectedly, the effect of emedastine difumarate was found to be different for dermal fibroblasts and nasal mucosa-derived fibroblasts. To the best of our knowledge, no reports have been published that discuss heterogeneity in the effect of H1R-blockers in these cell types. As nasal mucosa-derived fibroblasts are obtained from nasal polyps, it can be assumed that there are phenotypic differences between those cells and normal nasal mucosa-derived fibroblasts. At present, we have no explanation for this difference but further examination can be expected to yield some valuable information for tailor-made therapeutic strategies to treat allergic diseases.

## References

1. Global initiative for asthma. National Institute of Health Publication 95: 3569, 1995
2. Mihm MC Jr, Soter NA, Dvorak HF. The structure of normal skin and the morphology of atopic eczema. *J Invest Dermatol.* 1976;67:305-12.
3. Leung DY. Atopic dermatitis: the skin as a window into the pathogenesis of chronic allergic diseases. *J Allergy Clin Immunol.* 1995;96:302-18.
4. Damsgaard TE, Olesen AB, Sorensen FB, Thestrup-Pedersen K, Schiotz PO. Mast cells and atopic dermatitis. Stereological quantification of mast cells in atopic dermatitis and normal skin. *Arch Dermatol Res.* 1997;289:256-60.
5. Hatamochi A, Ueki H, Mauch C, Krieg T. Effect of histamine on collagen and collagen m-RNA production in human skin fibroblasts. *J Dermatol Sci.* 1991;2:407-12.
6. Abe M, Yokoyama Y, Amano H, Matsushima Y, Kan C, Ishikawa O. Effect of activated human mast cells and mast cell-derived mediators on proliferation, type 1 collagen production and glycosaminoglycans synthesis by human dermal fibroblasts. *Eur J Dermatol.* 2002;12:340-6.
7. Katayama I, Nishioka K. Substance P augments fibrogenic cytokine-induced fibroblast proliferation: possible involvement of neuropeptide in tissue fibrosis. *J Dermatol Sci.* 1997;15:201-6.
8. Leung DY. Atopic dermatitis: the skin as a window into the pathogenesis of chronic allergic diseases. *J Allergy Clin Immunol.* 1995;96:302-18.
9. Nickoloff BJ, Bonish BK, Marble DJ, Schriedel KA, Dipietro LA, Gordon KB, Lingen MW. Lessons learned from psoriatic plaques concerning mechanisms of tissue repair, remodeling, and inflammation. *J Invest Dermatol.* 2006;11(1):16-29.
10. Katoh N, Hirano S, Suehiro M, Ikenaga K, Yasuno H. Increased level of serum tissue inhibitor of metalloproteinase-1 but not metalloproteinase-3 in atopic dermatitis. *Clin Exp Immunol.* 2002;127:283-8.
11. Antoine M, Wira W, Tag CG, Gressner AM, Wycislo M, Muller R, Kiefer P. Fibroblast growth factor 16 and 18 are expressed in human cardiovascular tissues and induce on endothelial cells migration but not proliferation. *Biochem Biophys Res Commun.* 2006;346:224-33.
12. Olofsson B, Korpelainen E, Pepper MS, Mandriota SJ, Aase K, Kumar V, Gunji Y, Jeltsch MM, Shibuya M, Alitalo K, Eriksson U. Vascular endothelial growth factor B (VEGF-B) binds to VEGF receptor-1 and regulates plasminogen activator activity in endothelial cells. *Proc Natl Acad Sci USA.* 1998;95:11709-14.
13. Werner S, Alzheimer C. Roles of Activin in tissue repair, fibrosis, and inflammatory disease. *Cytokine Growth Factor Rev.* 2006;17:157-71.
14. Takehara K. Growth regulation of skin fibrosis. *J Dermatol Sci.* 2000;24 suppl:S70-7.
15. Wozney JM. Bone morphogenetic proteins. *Prog Growth Factor Res.* 1989;1:267-80.
16. Mou C, Jackson B, Schneider P, Overbeek PA, Headon DJ. Generation of the primary hair follicle pattern. *Proc Natl Acad Sci USA.* 2006;103:9075-80.
17. Rosiere CE, Grossman MI. An analog of histamine that stimulates gastric acid secretion without other actions of histamine. *Science.* 1951;113:651.

18. Panula P, Karlstedt K, Sallmen T, Peitsaro N, Kaslin J, Michelsen KA, Anichtchik O, Kukko-Lukjanov T, Lintunen M. The histaminergic system in the brain: structural characteristics and changes in hibernation. *J Chem Neuroanat.* 2000;18:65-74.
19. Sato E, Haniuda M, Numanami H, Ushiyama T, Tsukadaira A, Takashi S, Okubo Y, Koyama S. Histamine and serotonin stimulate eotaxin production by a human lung fibroblast cell line. *Int Arch Allergy Immunol.* 2002;128 suppl:S12-17.
20. Jordana M, Befus AD, Newhouse MT, Bienenstock J, Gauldie J. Effect of histamine on proliferation of normal human adult lung fibroblasts. *Thorax.* 1988;43:552-8.
21. Numata Y, Terui T, Okuyama R, Hirasawa N, Sugiura Y, Miyoshi I, Watanabe T, Kuramasu A, Tagami H, Ohtsu H. The acceleration effect of histamine on the cutaneous wound-healing process through the action of basic fibroblast growth factor. *J Invest Dermatol.* 2006;126:1403-9.
22. Flank S, Hubner G, Breier G, Longaker MT, Greenhalgh DG, Werner S. Regulation of vascular endothelial growth factor expression in cultured keratinocytes. *J Biol Chem.* 1995;270:12607-13.
23. Trompezinski S, Pernet I, Mayoux C, Schmitt D, Viac J. Transforming growth factor family member but not endothelin-1 in human dermal fibroblasts; *Br J Dermatol.* 2000; 143:539-45.
24. Trompezinski S, berthier-Vergnes O, Denis A, Schmitt D, Viac J. Comparative expression of vascular endothelial growth factor family members, VEGF-B, -C, and -D, by normal human keratinocytes and fibroblasts. *Exp Dermatol.* 2004;13:98-105.
25. De Palis A, Prevete N, Fiorentino I, Rossi FW, Staibano S, Montuori N, Ragno P, Longobardi A, Liccardo B, Genovese A, Ribatti D, Walls AF, Marone G; Expression and functions of the vascular endothelial growth factors and their receptors in human basophils. *J Immunol.* 2006;177:7322-31.
26. Kawano M, Komi-kuramochi A, Asada M, Suzuki M, Oki J, Jiang J, Imamura T. Comprehensive analysis of FGF and FGFR expression in skin: FGF18 is highly expressed in hair follicles and capable of inducing anagen from telogen stage hair follicles. *J Invest Dermatol.* 2005;124:877-85.

■ *Manuscript received June 14, 2007; accepted for publication August 22, 2007.*

■ **Hiroyuki Murota**

Department of Dermatology  
Osaka University School of Medicine  
2-2 Yamadaoka, Suita  
Osaka, Japan  
E-mail: h-murota@derma.med.osaka-u.ac.jp