

SUPPLEMENTARY MATERIAL

Figure 1.

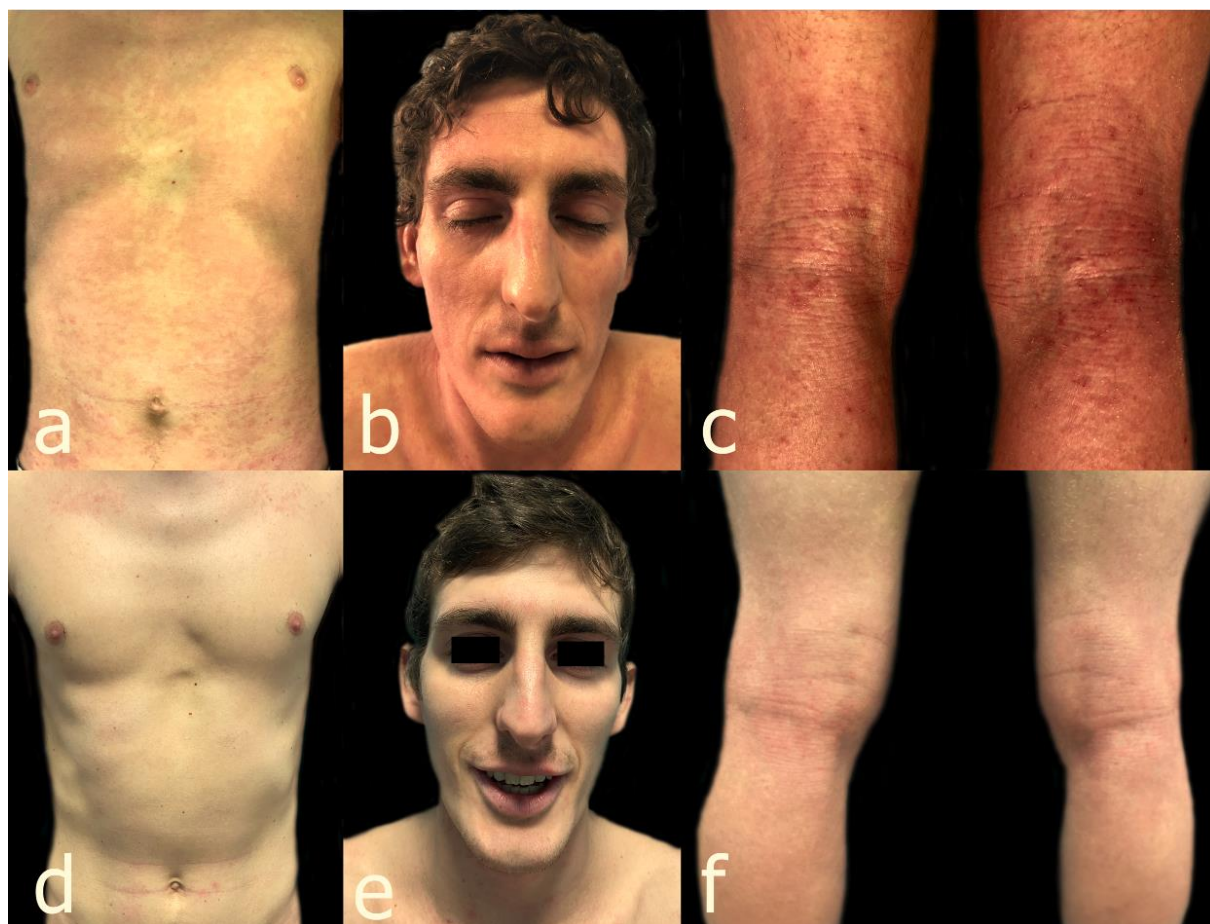


Figure 1 legend: (a), (b) and (c) At baseline suberythrodermic atopic dermatitis. (d), (e) and (f) Marked improvement of atopic dermatitis at 20-month follow-up under dupilumab therapy.