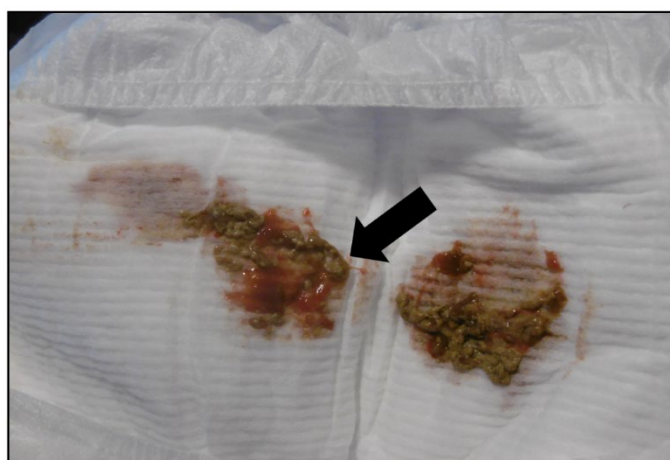

## Supplementary Material



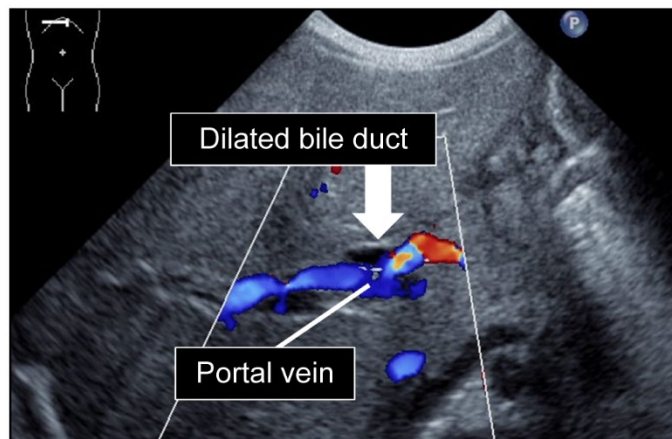
Patient 1 (day 7)

**Supplementary Figure S1** Acholic stool (arrow) of patient 1 at day 7



Patient 1 (day 8)

**Supplementary Figure S2** Bloody stool and diarrhea (arrow) of patient 1 at day 8



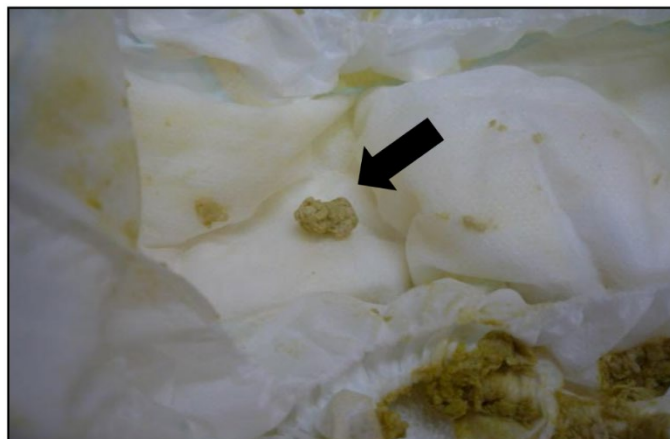Patient 1 (day 8)

**Supplementary Figure S3** Abdominal ultrasonography showing the dilated bile duct (arrow) of patient 1, in which there was no color signal. In normal newborns, the bile duct is undetectable by ultrasonography



Patient 2 (day 7)

**Supplementary Figure S4** Bloody stool and diarrhea (arrow) of patient 2 at day 7



Patient 2 (day 23)

**Supplementary Figure S5** Acholic stool (arrow) of patient 2 at day 23