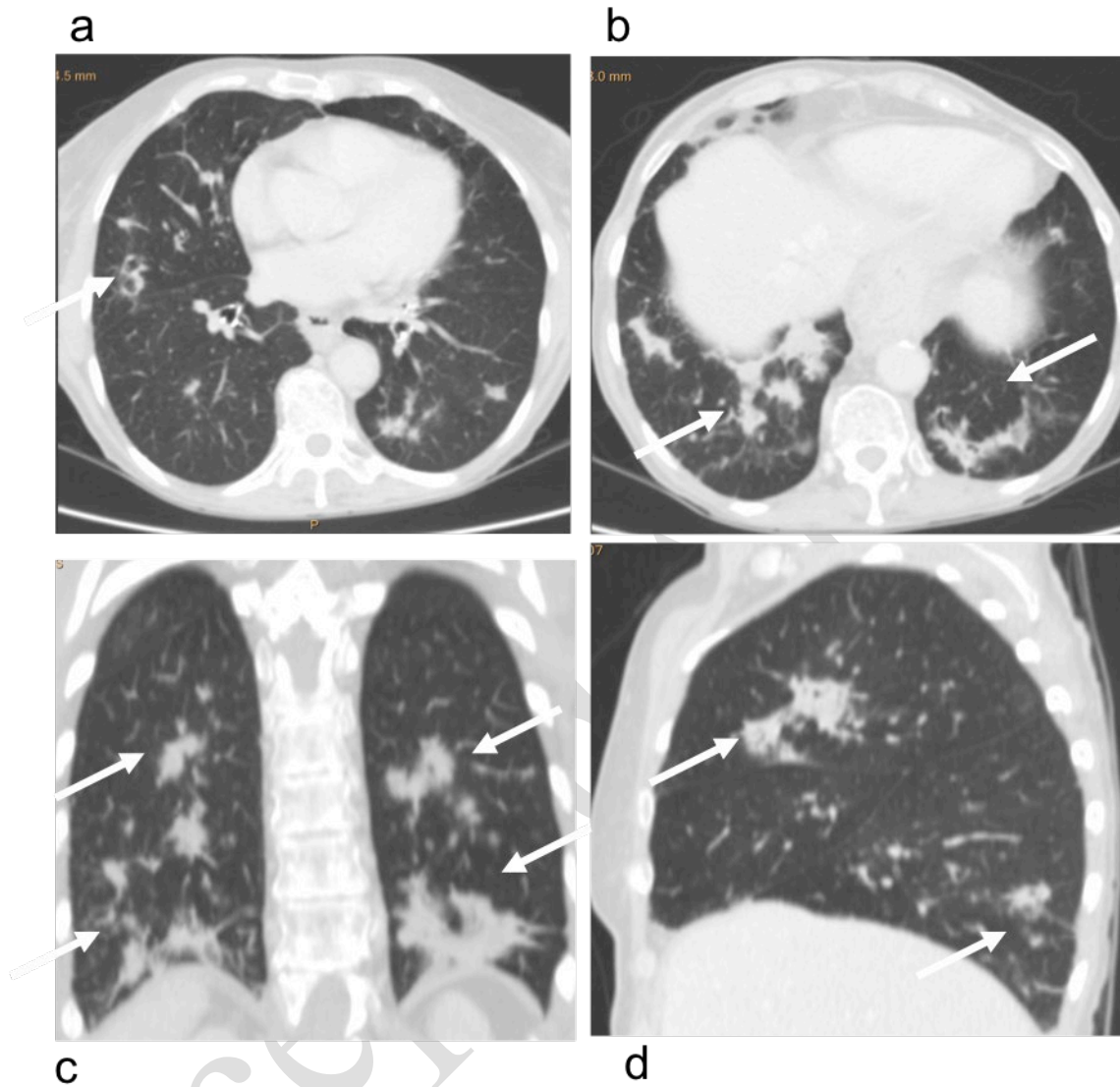


## Supplementary material

Table 1. Evolution of the symptoms and complementary blood values

	2016 Aug	2016 Nov	2017 Dec	2018 March
Total IgE (KU/l)	24.5	74.5	512	63.7
Specific IgE <i>Aspergillus fumigatus</i> (KUA/l)	0.56	1.3	4.12	1.25
IgG <i>Aspergillus fumigatus</i> (mgA/l)	51.9	68.8	103	72
Serum eosinophilia (cels/mL)	400	300	300	100
Neutrophils (cels/mL)	3500	4000	1300	2800
Symptoms	Fever, respiratory infections. Treated with voriconazole 2 months and changed for posaconazole 2 months.	None	Asthma exacerbation ABPA criteria and invasive aspergillosis image on tomography. Isavuconazole 4 months.	None

Figure 1. Computed Tomography (CT)-scan of the patient. Images compatible with Chronic Pulmonary Aspergillosis.



Legend: Lung window: a. Axial section, lung nodules in medial lobe with central cavitation. b. Axial section, multiple consolidations with air bronchogram. c. Coronal section, multiple and bilateral consolidations. d. Sagittal section, on upper right lobe and lower left lobe consolidations in patch.