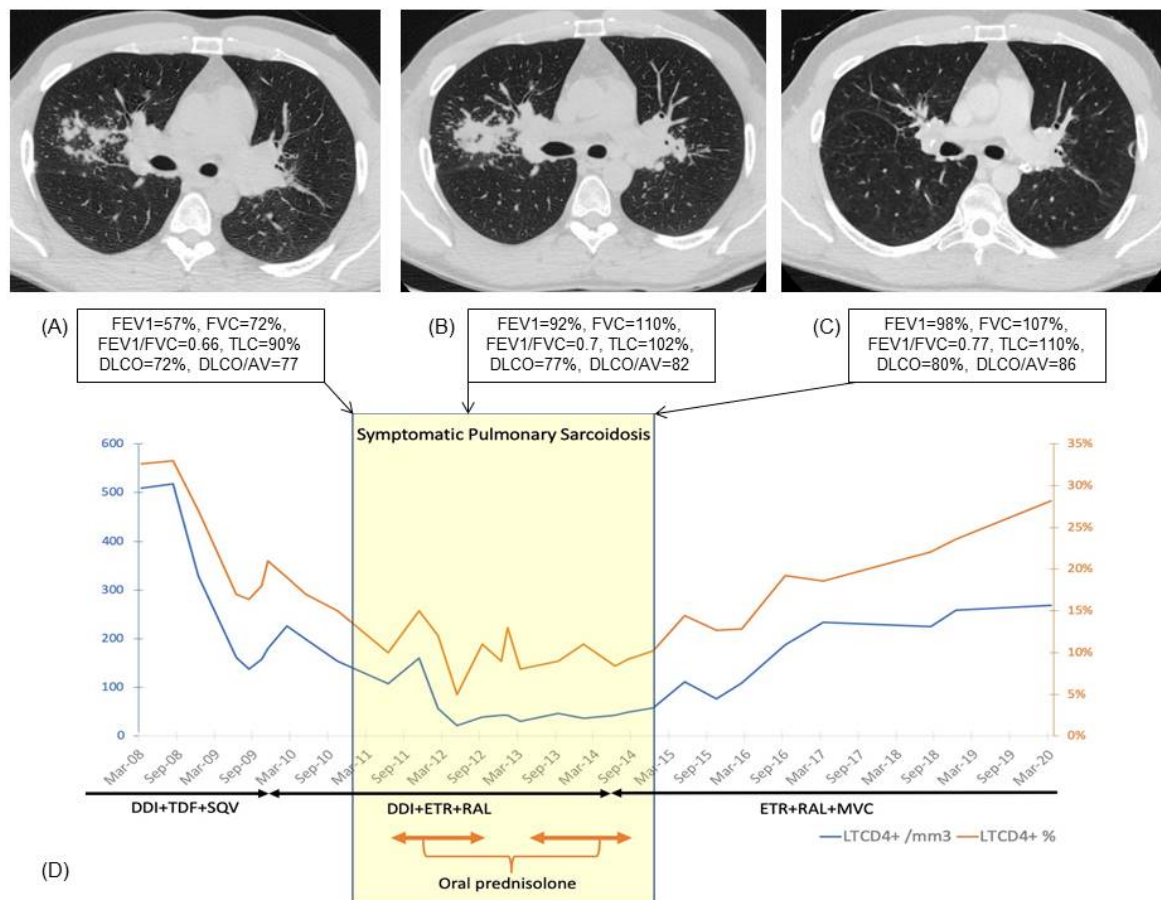


SUPPLEMENTARY MATERIAL

**Figure:**

(A): Chest CT scan, axial non contrast section, at baseline: typical bilateral symmetrical hilar adenopathy and subcarinal adenopathy with calcification in the right hilar lymph nodes, upper right lobe macronodules and micronodules with typical perilymphatic and peribronchovascular distribution

(B): Chest CT scan, axial non contrast section, after one year treatment by oral corticosteroids: pejorative evolution of lung sarcoidosis with consolidations with “galaxy sign”, global stability of adenopathies

(C): Chest CT scan, axial non contrast section, 6 months after the introduction of maraviroc: improvement of pulmonary involvement and decrease of lymph nodes size, with typical eggshell calcification in the left hilar lymph nodes, punctuate and nodular calcifications in the right hilar lymph nodes

(D): Evolution of the patient's immunological parameters, in parallel with the evolution of sarcoidosis-like granulomatosis, and therapeutic modifications. SQV = saquinavir, DDI = didanosin, TDF = tenofovir disoproxil, ETR = etravirin, RAL = raltegravir, MVC = maraviroc.

Lung function evaluated before and after both treatments FEV1: Forced expiratory volume in one seconde; FVC: Forced vital capacity; TLC: Total lung capacity; DLCO: Diffusing capacity for carbon monoxide; VA: Alveolar volume