

SUPPLEMENTARY MATERIAL

Figure 1. Electrocardiogram showing ST-segment elevation in inferior leads with second degree (Mobitz type I) atrioventricular block.

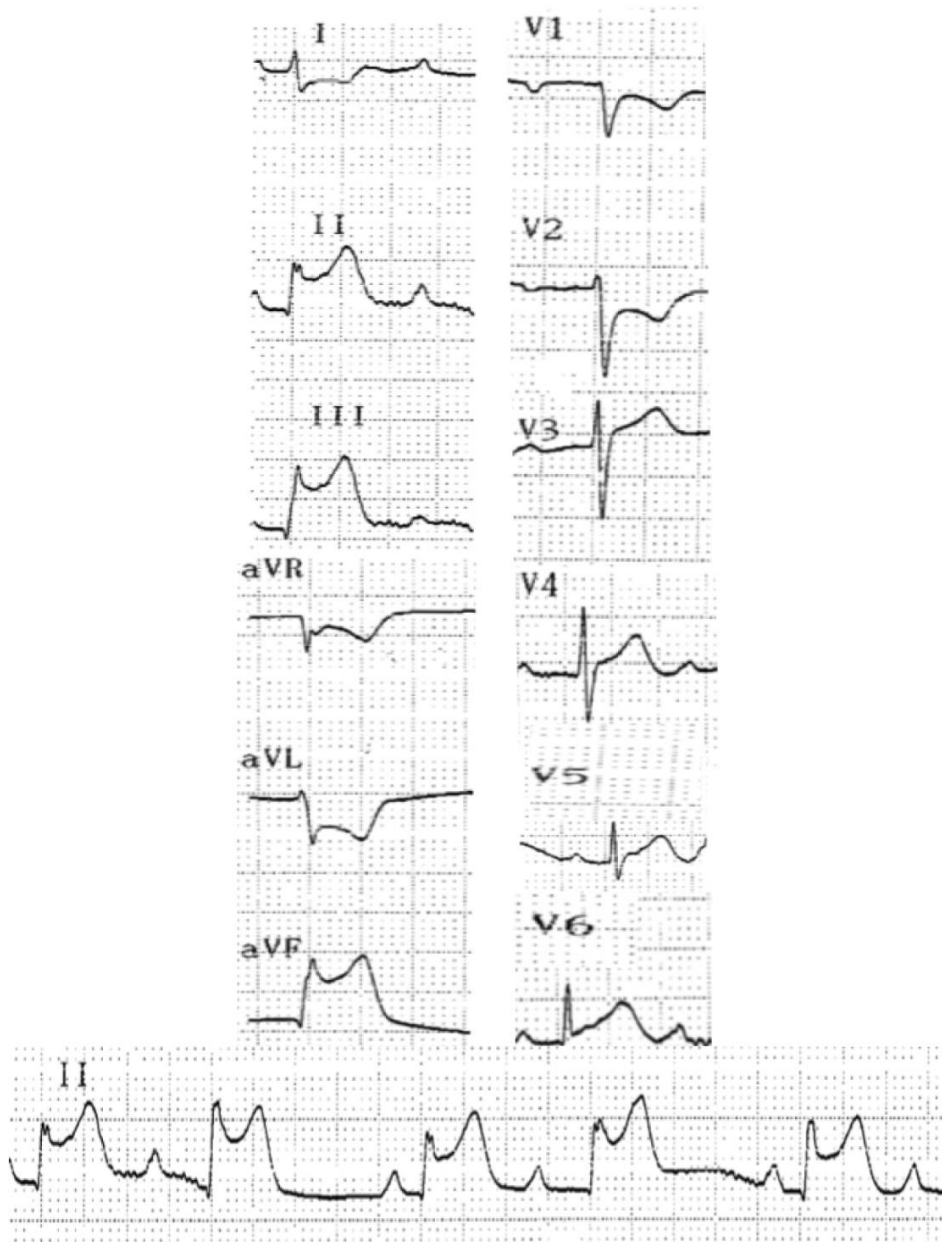


Figure 2. Computed tomography demonstrating diffuse ground-glass opacities and consolidations in both lungs

