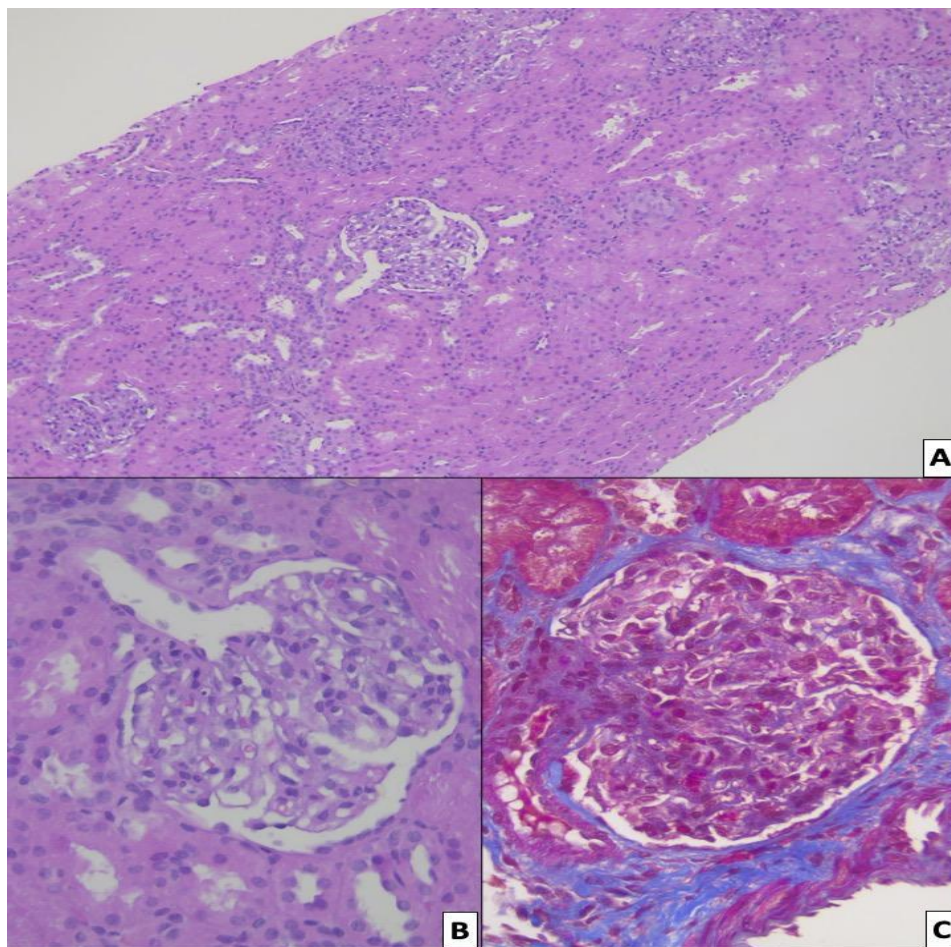


Figure 1 Supplementary



Histological sections of the kidney. A) Photomicrography (4x) showing the presence of glomeruli with mesangial hyperplasia. B) Photomicrography (40x) showing mesangial hyperplasia, which is made evident with Masson's stain (C).