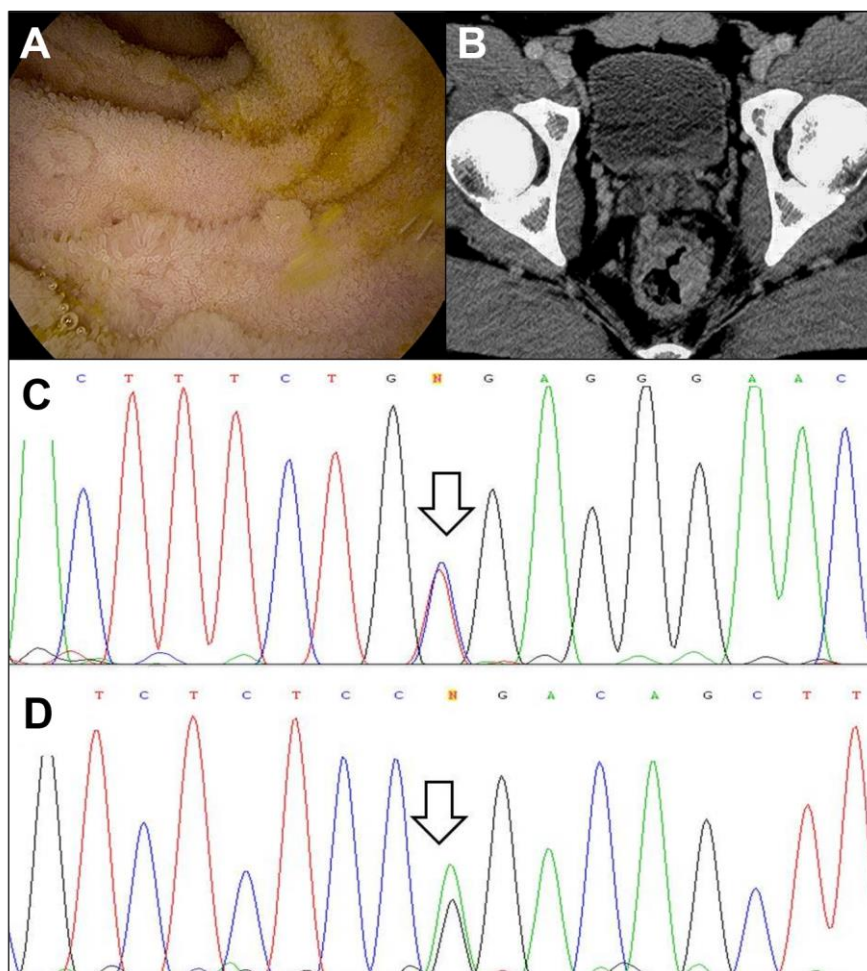


## SUPPLEMENTARY MATERIAL



**Supplementary Figure 1.** A) Several sessile lesions suggestive of lymphoid follicular hyperplasia are observed by ileoscopy. B) Axial contrast-enhanced pelvic CT image showing an asymmetric polypoid mural thickening in the rectum and several lymphadenopathies. C) and D) Electropherograms of exons 2 and 4 of the AICDA gene, showing the c.295C>T (C) and c.520A>G (D) mutations in heterozygosis, respectively.