

# Selective Immediate Hypersensitivity to Cefepime

E Moreno,<sup>1</sup> I Dávila,<sup>1</sup> E Laffond,<sup>1</sup> E Macías,<sup>1</sup> M Isidoro,<sup>1</sup> A Ruiz,<sup>1</sup> F Lorente<sup>1</sup>

<sup>1</sup> Department of Allergy, University Hospital of Salamanca, Spain

## ■ Abstract

Cefepime is a fourth-generation cephalosporin with a broad antimicrobial spectrum and good activity against both gram-positive and gram-negative organisms.

We present the case of a 61-year-old man who developed an immediate urticarial reaction after receiving a single dose of cefepime. Skin tests were positive to cefepime and negative to the other  $\beta$ -lactam antibiotics. Controlled administration of amoxicillin-clavulanic acid and ceftazidime was well tolerated by the patient. To the best of our knowledge, this is the first report of selective hypersensitivity to cefepime demonstrated by skin and challenge tests. Complete allergological studies, including challenge tests with other  $\beta$ -lactam antibiotics that produce a negative result in skin tests, should be considered in these patients.

**Key words:** Adverse reaction. Amoxicillin clavulanic acid. Cefepime. Ceftazidime. Cephalosporin. Hypersensitivity.

## ■ Resumen

La cefepima es una cefalosporina de cuarta generación con amplio espectro antimicrobiano y buena actividad tanto frente a bacterias gram-positivas como gram-negativas. Presentamos el caso de un varón de 61 años de edad que desarrolló una reacción urticarial inmediata tras recibir una única dosis de cefepima. En el estudio alergológico, las pruebas cutáneas fueron positivas con cefepima y negativas con otros betalactámicos. El paciente toleró, además, la administración controlada de amoxicilina-clavulánico y de ceftazidima. En nuestro conocimiento este es el primer caso de reacción selectiva a cefepima demostrado por pruebas cutáneas y pruebas de exposición controlada. El estudio alergológico completo, incluyendo la exposición controlada con antibióticos beta-lactámicos diferentes al que produjo la reacción y con un resultado negativo en las pruebas cutáneas, deberían ser considerados en estos pacientes.

**Palabras clave:** Reacción adversa. Amoxicilina-clavulánico. Cefepima. Ceftazidima. Cefalosporina. Hipersensibilidad.

## Introduction

Cefepime is a fourth-generation cephalosporin with a broad antimicrobial spectrum and good activity against both gram-positive organisms, (including *Staphylococcus aureus*), and gram-negative organisms, (including *Pseudomonas aeruginosa*) [1].

## Case Description

A 61-year-old man with multiple myeloma immunoglobulin (Ig) g Kappa in progression was admitted to hospital due to a 2-week long fever that did not respond to treatment with ciprofloxacin and amoxicillin clavulanic acid. The patient was

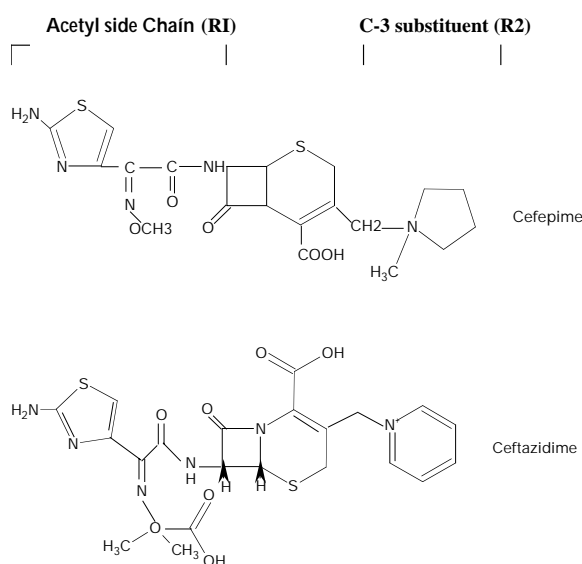
empirically treated with cefepime 2 g per day intravenously. Five minutes after the first dose, he presented generalized pruritus and urticaria, with dyspnea and wheezing. He rapidly recovered with intravenous methylprednisolone (60 mg) and dexchlorphenamine (5 mg). He had previously tolerated this antibiotic two years before. He had no previous history of drug allergy or atopy and no family history of allergic diseases.

Four weeks later, the patient underwent prick and intradermal skin testing with penicillin and cephalosporin reagents at the concentrations recommended by the European Academy of Allergology and Clinical Immunology Interest Group on Drug Hypersensitivity (table) [2]. Histamine was used as a positive control and normal saline as a negative control. Skin prick tests

Skin Tests With  $\beta$ -Lactam Antibiotics\*

Drugs	Concentrations (mg/mL)
PPL	$5 \times 10^{-5}$
MDM	$2 \times 10^{-5}$
Benzylpenicillin	10 000 IU
Amoxicillin	20 mg/mL
Cefazoline	2 mg/mL
Cefuroxime	2 mg/mL
Cefotaxime	2 mg/mL
Ceftriaxone	2 mg/mL
Ceftazidime	2 mg/mL
Cefepime	2 mg/mL

\* PPL indicates penicilloyl-polyllysine; MDM, minor determinant mixture



Chemical Structures of Cefepime and Ceftazidime.

were considered positive if the wheal diameter was greater than 3 mm and intradermal tests were considered positive if an increase greater than 3 mm to the diameter of the initial wheal appeared with erythema [3]. Skin tests with cephalosporins indicated in the table were also carried out in 20 healthy control subjects, 5 of whom had previously received treatment with cefepime with good tolerance.

In vitro assays (UniCAP Specific IgE; Pharmacia & Upjohn Diagnostics AB, Uppsala, Sweden) were performed according to the manufacturer's instructions for specific IgE to available  $\beta$ -lactams (penicilloyl G, penicilloyl V, ampicilloyl, amoxicilloyl and cefaclor). A positive result was defined as a value above 0.35 kU/L.

Single-blind, placebo-controlled challenges with oral amoxicillin clavulanic acid (500/125 mg) and intravenous ceftazidime (1 g) were performed on different days. Starting with 1/8 of the normal therapeutic dose, doses were increased under strict monitoring at 45-minute intervals until the therapeutic dose was administered.

The patient had a positive intradermal test to cefepime with a wheal of  $9 \times 10$  mm. No other reactions were observed, including to cephalosporins with a similar side chain such as ceftazidime (figure). None of the control subjects had positive skin tests to any of the reagents. Specific immunoglobulin (Ig) E antibodies to penicilloyl G, amoxicilloyl, ampicilloyl and cefaclor were not detected.

The patient tolerated both oral amoxicillin-clavulanic acid and intravenous ceftazidime at therapeutic doses.

## Discussion

The characteristics of reaction, the previous exposure to cefepime, and the positive intradermal test strongly suggest a type-I allergic reaction.

Cases of hypersensitivity to cefepime are rare. We have found only one case of IgE-mediated anaphylaxis to cefepime. In this case, intradermal skin tests were positive with cefepime and with cephalosporins with the same (ceftriaxone and cefotaxime) or similar (ceftazidime) acetyl side chain [4].

IgE mediated reactions to cephalosporins may be produced by at least three different patterns of immune recognition: cross-reactivity with penicillin, cross-reactivity among different cephalosporins, and a selective response to the specific drug that produced the reaction [5]. In recent studies, the R1 side chain seems to play a dominant role in determining the specificity of immunologic reactions to cephalosporins [6, 7]. In selective responses, recognition of the entire molecule has been suggested [8]. In our patient, the selective cutaneous response to cefepime and the tolerance to similar side chain cephalosporins, such as ceftazidime (figure), suggest a selective sensitization to cefepime without cross-reactivity to other  $\beta$ -lactam antibiotics. This sensitization probably occurred in the previous exposure to cefepime two years previously.

To our knowledge, this is the first case in which a selective response to cefepime has been demonstrated.

In the evaluation of immediate reactions to cephalosporins, it is crucial to test the drug responsible in addition to penicillin determinants [2, 5, 9]. Complete allergological studies, including challenge tests with other  $\beta$ -lactam antibiotics that produce a negative result in skin tests, should be considered in selected patients [5, 7, 9, 10]. Our patient, who had a neoplasm and repeated episodes of febrile neutropenia, may serve as an example. We selected amoxicillin-clavulanic acid and ceftazidime because they are good alternatives in the treatment of patients with febrile neutropenia due to haematological malignancy. These challenge tests were of crucial importance for our patient because, two weeks later, he developed a new episode of fever and neutropenia. He received a complete course of amoxicillin-clavulanic acid and he subsequently recovered.

## References

- Oster S, Edelstein H, Cassano K, McCabe R. Open trial of cefepime (BMY 28142) for infections in hospitalized patients. *Antimicrob Agents Chemother.* 1990;34(6):954-7.
- Torres MJ, Blanca M, Fernandez J, Romano A, Weck A, Aberer W,

- Brockow K, Pichler WJ, Demoly P; ENDA; EAACI Interest Group on Drug Hypersensitivity. Diagnosis of immediate allergic reactions to beta-lactam antibiotics. *Allergy*. 2003 Oct;58(10):961-72.
3. Brockow K, Romano A, Blanca M, Ring J, Pichler W, Demoly P. General considerations for skin test procedures in the diagnosis of drug hypersensitivity. *Allergy*. 2002;57(1):45-51.
  4. Orhan F, Odemis E, Yaris N, Okten A, Erduran E, Durmaz M, Yayla S. A case of IgE-mediated hypersensitivity to cefepime. *Allergy*. 2004;59:239-41.
  5. Romano A, Mayorga C, Torres MJ, Artesani MC, Suau R, Sánchez F, Pérez E, Venuti A, Blanca M. Immediate allergic reactions to cephalosporins: cross-reactivity and selective responses. *J Allergy Clin Immunol*. 2000;106:1177-83.
  6. Sanchez-Sancho F, Perez-Inestrosa E, Suau R, Montanez MI, Mayorga C, Torres MJ, Romano A, Blanca M. Synthesis, characterization and immunochemical evaluation of cephalosporin antigenic determinants. *J Mol Recognit*. 2003;16:148-56.
  7. Antunez C, Blanca-Lopez N, Torres MJ, Mayorga C, Perez-Inestrosa E, Montañés MI, Fernandez T, Blanca M. Immediate allergic reactions to cephalosporins: evaluation of cross-reactivity with a panel of penicillins and cephalosporins. *J Allergy Clin Immunol*. 2006;117:404-10.
  8. Baldo BA. Penicillins and cephalosporins as allergens--structural aspects of recognition and cross-reactions. *Clin Exp Allergy*. 1999;29:744-9.
  9. Romano A, Gueant-Rodriguez RM, Viola M, Amoghly F, Gaeta F, Nicolas JP, Gueant JL. Diagnosing immediate reactions to cephalosporins. *Clin Exp Allergy*. 2005;35:1234-42.
  10. Igea JM, Fraj J, Davila I, Cuevas M, Cuesta J, Hinojosa M. Allergy to cefazolin: study of in vivo cross reactivity with other betalactams. *Ann Allergy*. 1992;68:515-9.

■ *Manuscript received May 31, 2006; accepted for publication August 28, 2006*

■ **Esther Moreno**

Department of Allergy  
University Hospital of Salamanca  
Paseo de San Vicente 58-132  
Salamanca, SPAIN  
E-mail: emrodilla@ono.com