

Multidrug-Induced Erythema Multiforme

*SR Isik,¹ G Karakaya,¹ G Erkin,² AF Kalyoncu,¹

¹Department of Chest Diseases, Adult Allergy Unit, Hacettepe University School of Medicine, Sıhhiye, Ankara, Turkey

²Department of Dermatology, Hacettepe University School of Medicine, Sıhhiye, Ankara, Turkey

■ Abstract

Adverse skin reactions to drugs are frequent, with rates of reaction to many commonly used drugs exceeding 1%. We describe a 29-year-old woman admitted with a history of itching, rash, vesicles on her hands and soles, and edema on her tongue and oropharynx after trimethoprim–sulfamethoxazole, ciprofloxacin, methenamine anhydromethylene citrate, piroxicam, azithromycin, and ceftriaxone intake. Erythema multiforme (EM) was diagnosed by skin biopsy after oral challenge with piroxicam. EM lesions reappeared after oral challenge with levofloxacin. Although EM is quite common with trimethoprim–sulfamethoxazole and there are some reports of EM appearing after intake of ciprofloxacin, it has rarely been attributed to piroxicam and no reports have identified levofloxacin as a cause.

Key words: Erythema multiforme. Drug allergy. Analgesic intolerance. Ciprofloxacin. Piroxicam. Levofloxacin. Trimethoprim–sulfamethoxazole. Bronchoscopy.

■ Resumen

Las reacciones adversas cutáneas a fármacos son comunes, siendo las tasas de reacción a muchos fármacos de uso frecuente superiores a un 1%. Describimos el caso de una mujer de 29 años de edad ingresada por presentar prurito, eccema, vesículas en manos y plantas de los pies y edema en lengua y orofaringe, tras tomar trimetoprim–sulfametoxazol, ciprofloxacina, citrato de anhidrometileno de metenamina, piroxicam, acitromicina y ceftriaxona. Se le diagnosticó eritema multiforme (EM) mediante una biopsia cutánea que se realizó tras una prueba de provocación oral con piroxicam. Las lesiones del EM reaparecieron tras la provocación con levofloxacina. Aunque el EM es bastante común con el trimetoprim–sulfametoxazol y a pesar de que se han dado algunos casos de EM tras la toma de ciprofloxacina, rara vez se ha atribuido al piroxicam y no hay ningún estudio que presente la levofloxacina como desencadenante.

Palabras clave: Eritema multiforme. Alergia a fármacos. Intolerancia a los analgésicos. Ciprofloxacina. Piroxicam. Levofloxacina. Trimetoprim–sulfametoxazol.

Introduction

Adverse drug-related skin reactions that have a frequency above 1% are urticaria, angioedema, photosensitivity, fixed drug eruptions, erythema multiforme (EM), Stevens–Johnson syndrome, and toxic epidermal necrolysis [1]. EM is an acute mucocutaneous inflammatory and hypersensitivity reaction characterized by a skin eruption, with symmetric erythematous edematous or bullous lesions of the skin or mucous membranes [2,3]. More than half the cases have no known cause, while half are caused by medications, infections, immunotherapy, or illnesses [3-5]. Culprit drugs are antibiotics such as β -lactams (penicillins, cephalosporins) and non- β -

lactams (clindamycin, trimethoprim–sulfamethoxazole, ethambutol, tetracycline-like drugs, clindamycin, rifampicin), anticonvulsants (carbamazepine, phenytoin, phenylbutazone, phenothiazine-like drugs, barbiturates), allopurinol, nonsteroidal anti-inflammatory drugs (NSAIDs), oral antidiabetics (sulfonamides, chlorpropamide, tolbutamide), codeine, furosemide, gold, and protease inhibitors [3,4]. Herpes simplex infection is among the most commonly implicated infectious causes of EM, where infection by such pathogens as *Mycoplasma pneumoniae* are less commonly implicated [3]. Although EM is quite common after administration of trimethoprim–sulfamethoxazole, it is rarely caused by piroxicam [6].

Case Description

A 29-year-old woman with a history of itching rashes and vesicles on her interphalangeal parts of hands, palms, soles and edema on her tongue and oropharynx after taking trimethoprim–sulfamethoxazole, ciprofloxacin, methenamine anhydromethylene citrate, piroxicam, azithromycin and ceftriaxone was examined at our outpatient clinic. Her mother had a similar reaction with only trimethoprim–sulfamethoxazole. Because the patient had a history of recurrent urinary system infections, she had been using oral antibiotics frequently. She was hospitalized to perform the required tests.

Physical examination, blood cell count and liver enzymes were normal. As her mother had the same history, the HLA types of both women were examined. Common groups were HLA-A24, HLA-A18, HLA-C03, DRB1*11, and DQB1*03. She had no gynecologic abnormality to explain her recurrent dysuria and her urine culture was negative.

Skin prick and intradermal tests with penicillin G, ampicillins, amoxicillins and ceftriaxone were negative and there was no reaction after intramuscular challenge with ceftriaxone. Oral challenge tests were negative for penicillin V, methenamine anhydromethylene citrate and clarithromycin, but positive for

piroxicam. Circular, hyperemic lesions developed on her palm 2.5 hours after oral intake of piroxicam. The next day bullous lesions had developed on her tongue, oropharynx (confirmed by flexible bronchoscopy, Figure 1), palms (Figure 2) and soles; she was treated with short-acting antihistamines and methyl prednisolone. The pathology report after examination of the biopsy material from the lesion on one of the palms named an EM-type drug eruption. As the patient had recurrent urinary infections, an oral challenge test was performed with levofloxacin to determine a safe alternative antibiotic. Levofloxacin caused aggravation of the healing EM lesions that had appeared due to piroxicam a week earlier.

As the patient's history has disclosed that she could use diclofenac, flurbiprofen, and paracetamol safely, she was advised to use these drugs when she needed analgesics or NSAIDs.

Discussion

EM is a type of hypersensitivity reaction which is caused by various insults, often from an infectious agent or a drug. Antibiotics and NSAIDs may cause erythema multiforme [2,3]. Drugs and virus or bacteria can also cause EM [2], which has

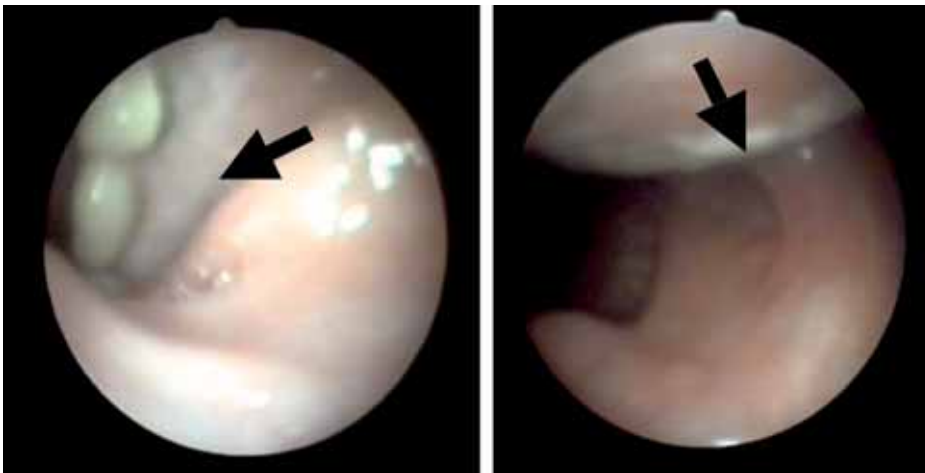


Figure 1. The bronchoscopic views of bullous oropharyngeal lesions.

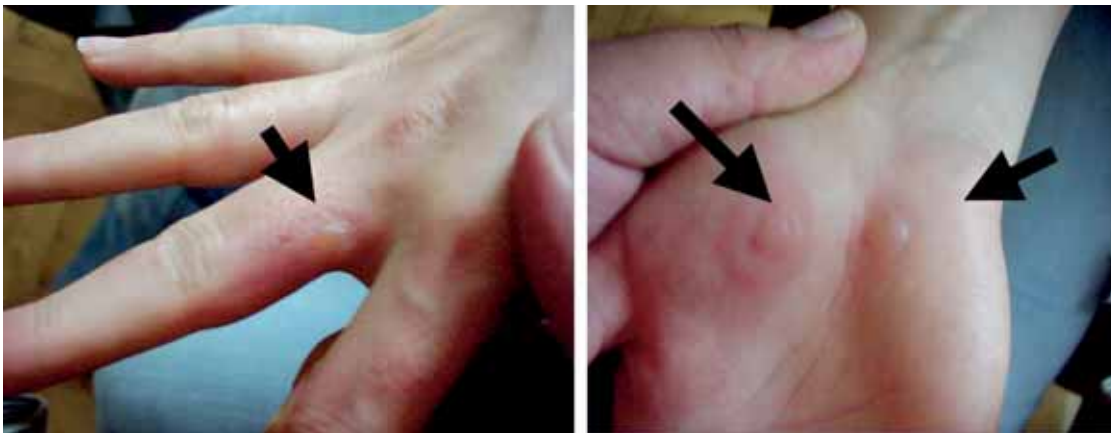

Figure 2. Bullous lesions on the palm and interphalangeal parts of hand.

been classified according to the degree of mucosal involvement and the nature and distribution of the skin lesions [3]. Thus, EM minor which typically affects a single mucosa is the most common form and may be associated with symmetrical target lesions on the extremities. EM major is more severe, typically involving 2 or more mucous membranes with more variable skin involvement. This feature is used to distinguish it from Stevens–Johnson syndrome, where there is extensive skin involvement, significant morbidity, and a mortality rate of 5% to 15% [3]. Although EM is more frequently seen in males, the incidence of drug-related EM is similar in males and females [3].

There is a genetic component of EM. It is linked to specific HLA types such as HLA-DQ3, HLA-B15 (B62), HLA-B35, HLA-A33, HLA-DR53 and HLADQB1*0301. Extensive mucosal involvement may be exceptionally associated with HLA allele DQB1*402 patients [3]. In our patient and her mother there was a DQB1*03 and DRB1*11 association.

Like many other drugs, trimethoprim–sulfamethoxazole can induce a large number of different skin reactions, mainly of allergic pathogenesis. The majority of these reactions—such as urticarial, purpuric, maculopapular, and pustular exanthemas as well as photoallergic reactions—generally do not endanger the life of the patient [7]. EM is the more localized form of Stevens–Johnson syndrome and may be caused by trimethoprim–sulfamethoxazole. Our patient had a history of EM with trimethoprim–sulfamethoxazole.

Although piroxicam can often cause urticaria, photosensitivity reactions, and fixed drug eruption, it rarely causes EM, Stevens–Johnson syndrome, or toxic epidermal necrolysis [6]. Diagnosis is usually clinical but skin biopsy may also be needed [1,2]. As skin biopsy is not enough to determine whether EM is drug-induced or not, skin tests or oral drug challenge tests are needed [1]. Piroxicam has been mentioned as a culprit only infrequently, usually in discussions of the clinical features of Stevens–Johnson syndrome, a more systemic reaction than EM. In 2 case reports of piroxicam-induced EM, the cause was confirmed with patch testing [6] or oral challenge [8].

EM lesions generally appear within a period of 72 hours and their locations are fixed [2]. EM developed within 24 to 48 hours after the oral challenge with piroxicam in our patient and the nature of the lesions was confirmed by biopsy. In severe cases, fibrinoid necrosis can occur in the stomach, trachea, and bronchi [3]; however, only bullous lesions were observed in our patient's oropharynx. None were observed in trachea or bronchi.

Although there are reports of EM appearing after use of ciprofloxacin [9], there are no reports specifically about EM caused by levofloxacin, yet our patient's healing piroxicam-induced EM lesions became aggravated after the oral challenge with levofloxacin. Quinolones have a high degree of cross-reactivity, and our patient had a history of reaction after ciprofloxacin use. Her reaction to levofloxacin might be a rare isolated reaction or one due to this cross-reactivity among quinolones [10–12].

In addition to trimethoprim–sulfamethoxazole and piroxicam, levofloxacin should be kept in mind as a possible cause of drug-induced EM.

References

1. Roujeau JC, Stern RS. Medical Progress: Severe adverse cutaneous reactions to drugs. *N Engl J Med*. 1994;331(19):1272–85.
2. Carder RK. Hypersensitivity reactions in neonates and infants. *Dermatol Ther*. 2005; 18:160–75.
3. Farthing P, Bagan JV, Scully C. Mucosal Disease Series. Number IV. Erythema multiforme. *Oral Dis*. 2005;11(5):261–7.
4. Zohdi-Mofid M, Horn TD. Acrosyringal concentration of necrotic keratinocytes in erythema multiforme: a clue to drug etiology. *Clinicopathologic review of 29 cases*. *J Cutan Pathol*. 1997;24(4):235–40.
5. Karakaya G, Sahin S, Kalyoncu AF. Erythema multiforme: as a complication of allergen-specific immunotherapy. *Allergol Immunopathol (Madr)*. 2001;29(6):276–8.
6. Prieto A, De Barrio M, Pérez C, Velloso A, Baeza ML and Herrero T. Piroxicam induced erythema multiforme. *Contact Dermatitis*. 2005;53:263.
7. Shopf E. Skin reactions to co-trimoxazole. *Infection*. 1987;15 Suppl 5:S254–8.
8. Katoh N, Kagawa K and Yasuno H. Piroxicam induced Stevens–Johnson syndrome. *J Dermatol*. 1995;22:677–80.
9. Hallgren J, Tengvall-Linder M, Persson M, Wahlgren CF. Stevens–Johnson syndrome associated with ciprofloxacin: a review of adverse cutaneous events reported in Sweden as associated with this drug. *J Am Acad Dermatol*. 2003; 49(5 Suppl):S267–9.
10. Campi P, Pichler WJ. Quinolone hypersensitivity. *Curr Opin Allergy Clin Immunol*. 2003;3(4):275–81.
11. Gonzalez I, Lobera T, Blasco A, del Pozo MD. Immediate hypersensitivity to quinolones; moxifloxacin cross-reactivity. *J Investig Allergol Clin Immunol*. 2005; 15(2):146–9.
12. Schmid DA, Depta JPH, Pichler WJ. T cell-mediated hypersensitivity to quinolones: mechanisms and cross-reactivity. *Clin Exp Allergy*. 2006;36:59–69.

■ *Manuscript received September 5, 2006; accepted for publication December 5, 2006.*

■ S Rana Isik

Hacettepe University School of Medicine
Department of Chest Diseases
Adult Allergy Unit
06100, Sıhhiye, Ankara, Turkey
E- Mail: ranaisik@hotmail.com