

Cyclical Hypereosinophilia With Skin Manifestations and a Clonal T Cell Population

P González Delgado,¹ ML de la Sen Fernández,² V Soriano Gomis,¹ M Pérez Crespo,¹ C Muñoz Ruiz,² E Niveiro Hernández¹

¹ Department of Allergology, University General Hospital of Alicante, Alicante, Spain

² Department of Immunology, University General Hospital of Alicante, Alicante, Spain

■ Abstract

Hypereosinophilia is a common biological finding in clinical practice, in some cases without an identifiable cause. We describe the case of a 59-year-old woman with recurrent attacks of facial angioedema, fever, pruritic cutaneous nodules, and eosinophilia that reached up to 12.7×10^9 cells/L during outbreaks. She had experienced 2 episodes every month for the last 12 years, and the episodes resolved with systemic corticosteroids. Other causes of eosinophilia were ruled out. The patient showed an aberrant T cell population with a CD3⁺CD4⁺TCR⁻ phenotype that accounted for up to 22% of circulating lymphocytes. Analysis of the T-cell receptor (TCR) gene showed evidence of clonal rearrangement. During the episodes, this cell population produced high levels of interleukin-5, which returned to normal levels between the outbreaks. However the aberrant T cell population remained unaffected after the treatment. We suggest that lymphocyte immunophenotyping analysis should be included in the diagnostic workup of patients with hypereosinophilic syndrome, including the variant type of episodic angioedema and eosinophilia (Gleich syndrome).

Key words: Hypereosinophilia. Cyclical angioedema. Gleich syndrome. Interleukin 5. CD3⁺CD4⁺ T cells.

■ Resumen

Antecedentes: La eosinofilia es un hallazgo relativamente frecuente en la práctica clínica, no hallándose en algunos casos una causa desencadenante. Describimos una paciente de 59 años de edad con episodios recidivantes de angioedema facial, fiebre, nódulos cutáneos pruriginosos y eosinofilia en sangre periférica que alcanzaba los $12,7 \times 10^9/L$ durante los episodios. Ha presentado una frecuencia media de dos episodios al mes los últimos 12 años, que se resolvían con corticoides sistémicos. Se excluyeron otras causa de eosinofilia. La paciente mostró una población aberrante de células T con un fenotipo CD3⁺CD4⁺TCR⁻ que representaba el 22% de los linfocitos circulantes. El estudio del reordenamiento del gen para el receptor T celular mostró evidencia de clonalidad. Esta población producía altos niveles de Interleucina-5 durante los episodios, que regresaba a valores normales intercrisis, si bien la población aberrante persistía. Se debe realizar estudio del inmunofenotipo linfocitario en pacientes con síndrome hipereosinofílico, incluso en la variante conocida como síndrome de Gleich que cursa con eosinofilia y angioedema cíclicos.

Palabras clave: Hipereosinofilia. Angioedema cíclico. Síndrome de Gleich. Interleucina-5.

Hypereosinophilia is a common biological finding in clinical practice and can be ascribed to an underlying disease in the majority of cases. Although parasitic diseases involving tissue-invasive helminths and atopy or allergic drug reactions account for most cases of hypereosinophilia, a number of less frequently encountered diseases may be implicated, including hematologic malignancies, solid tumors, connective tissue disorders, vasculitis, infectious diseases, and cutaneous disorders [1].

Hypereosinophilic syndromes are a heterogeneous group of uncommon disorders that are characterized by marked eosinophilia in the peripheral blood, tissues, or both, often without an identifiable cause [2]. Clinical manifestations and complications encountered in such patients are a direct result of eosinophil accumulations, as this leukocyte subset is known for its highly toxic content. In these disorders, the clinician's major task is to control eosinophil levels, which may represent a true challenge [1].

Case Description

A 59 year-old woman experienced recurrent attacks of facial angioedema, malaise, fever, and erythematous, pruriginous cutaneous nodules; the episodes began at the age of 38 years and had occurred twice monthly since then. The symptoms were treated successfully with 30 mg of prednisolone in a tapering dose regimen but reappeared every 15 days. The patient had no personal or family history of atopy.

The patient's eosinophil count during the episode reached 12.7×10^9 cells/L and returned to normal levels after the episode. Immunoglobulin levels were normal. Skin prick tests with a battery of commercial allergens were negative. Total serum immunoglobulin (Ig) E was less than 1 kU_A/L. No infections (anisakiasis, hookworm, ascariasis, strongyloidiasis, toxocariasis, or fascioliasis) were identified. Total hemolytic complement, concentrations of C3, C4, and C1 esterase inhibitor, serum protein electrophoresis, antinuclear antibody titer, serum vitamin B12, and folates were within normal limits. Serology for the human immunodeficiency virus was negative.

Biopsy of the skin lesions revealed extensive eosinophilia. Gastroscopy, colonoscopy, echocardiography, and computed tomography of the chest and abdomen showed no abnormalities. Karyotyping showed a normal 46 XX pattern, chromosomal analyses did not identify any abnormalities, and fluorescence in situ hybridization for BCR-ABL was negative. FIP1L1 gene fusion was not detected.

Bone marrow examination showed increased eosinophil precursors. Immunophenotyping of peripheral blood mononuclear cells by flow cytometry and direct staining with monoclonal antibodies revealed the presence of an aberrant T cell population with the following phenotype: CD3⁺ CD4⁺ CD5⁺ CD2⁺ CD7⁺ TCR⁺. This population represented 22% of

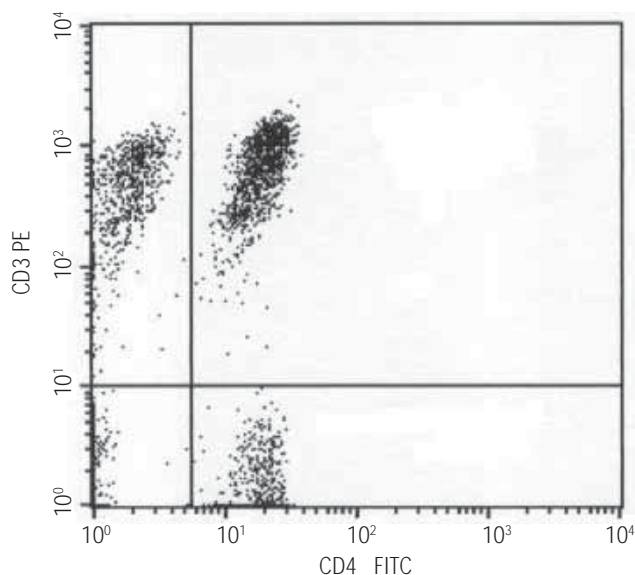


Figure. Identification of T cells with an aberrant immunophenotype in peripheral blood by fluorescence-activated cell sorting; 22% of total T lymphocytes were CD3⁺ CD4⁺.

circulating lymphocytes, persisted after the remission of the episodes, and remained unaffected after corticosteroid treatment (Figure). The serum level of interleukin (IL) 5 detected during an outbreak of the disease was 597 pg/mL (normal range, 0-8 pg/mL) but returned to normal levels after the attack.

T-cell receptor (TCR) γ chain gene rearrangement was studied by amplifying a selected fragment (VJ) in the hypervariable region of the TCR gene using a kit according to the manufacturer's instructions (Master Diagnostica, Granada, Spain), and a monoclonal rearrangement pattern was found.

After 12 years, the symptoms continue, with recurrent episodes of similar characteristics, but without evidence of major organ involvement, particularly cardiac, pulmonary, or neurologic disease. During the last year, the patient has had only 2 episodes, but these were more severe, with hypotension and cardiovascular collapse that necessitated admission to the intensive care unit.

Discussion

Acquired hypereosinophilias are currently classified as primary and secondary, and primary acquired hypereosinophilia is further classified as clonal or idiopathic [3]. The majority of patients with eosinophilia are found to have atopy or less often drug hypersensitivity, a skin disease, or parasitic infection. In these patients, hematopoietic cells are normal and eosinophilia emerges as the response to eosinophilopoietic cytokines such as IL-5, IL-3, and granulocyte/macrophage colony-stimulating factor, IL-5 being specific to the eosinophilic lineage, making it a prime target for therapeutic intervention [4].

In primary eosinophilia, there is an acquired abnormality of hematopoietic stem cells. A subset of patients has been reclassified as presenting clonal eosinophilia (chronic eosinophilic leukemia) based on identification of the Fip1-like 1/platelet-derived growth factor receptor alpha fusion transcript [5].

There are patients in whom no evidence of clonality can be demonstrated with currently available techniques, and they still have a disease that must be considered idiopathic [5].

Finally there is a subset of patients with an abnormal population of type 2 helper T (T_H2) cells that produce IL-5 and are detectable either by flow cytometry or polymerase chain reaction [5]. T cells display an aberrant surface phenotype in all reported cases, and CD3⁺ CD4⁺ cells represent the most frequently encountered subset in this setting. These patients exhibit a strikingly homogeneous clinical and biological profile. Cutaneous manifestations, including pruritus, eczema, urticaria and angioedema, are observed in virtually all patients reported in the literature. Very few patients develop endomyocardial fibrosis despite high eosinophil levels. Some patients present a clinical profile indistinguishable from that encountered in Gleich syndrome or episodic angioedema with eosinophilia, a disease characterized by spontaneously remitting episodes of angioedema, high serum IgM levels, and hypereosinophilia [1].

Our patient showed cyclical episodes of idiopathic hypereosinophilia with an underlying T cell disorder

characterized by expansion of an aberrant CD4⁺CD3⁻ T cell population producing high levels of IL-5 and with clonal features associated with cutaneous manifestations, fever, and malaise, similar to other patients previously described as having Gleich syndrome. Although this clinical entity has been considered as benign and patients do not usually require systemic therapy, our patient showed a different clinical course that necessitated high-dose systemic corticosteroids for many years and did not display a tendency toward remission. The presence of an aberrant population of lymphocytes may explain the persistence of the condition after 12 years.

In some cases of patients with eosinophilia, a CD3⁻CD4⁺ lymphocyte population has been detected before progression towards lymphoid malignancy [6]. Lymphocyte immunophenotyping should be included in the diagnostic workup of patients with hypereosinophilic syndrome, including the variant type of episodic angioedema and eosinophilia [7]. Rouffuse et al [8] confirmed that analysis of surface markers on peripheral blood lymphocytes is a critical step in the identification of hypereosinophilic patients with clonal T_H2 cells and indicates that particular attention should be paid to the presence of CD3⁻CD4⁺ T cells.

Corticosteroids remain useful for treatment of patients with an underlying T-cell disorder through their dual suppressive action on eosinophils and T-cell cytokine production [9]. In our patient the level of IL-5 declined after corticosteroid therapy but the aberrant T cell population remained unaffected, as has been described previously [8].

The efficacy of 2 monoclonal antibodies has been recently tested: mepolizumab, which targets IL-5, and alemtuzumab, which targets the CD52 antigen expressed by eosinophils [10-12]. Both showed promising effects, acting with equal efficacy in reducing the number of eosinophils, abolishing the symptoms, and improving quality of life, although there have been concerns as rebound eosinophilia has been noticed after treatment cessation [12]. Given the increasing intensity of the latest episodes, we have initiated the procedure to obtain permission for compassionate use of mepolizumab in our patient.

References

- Rouffosse F, Cogan E, Goldman M. Recent advances in pathogenesis and management of hypereosinophilic syndromes. *Allergy*. 2004;59:673-89.
- Klion AD, Bochner B, Gleich GJ, Nutman T, Rothenberg M, Simon HU, Echler M, Weller P. Approaches to the treatment of hypereosinophilic syndromes: A workshop summary report. *J Allergy Clin Immunol*. 2006;117:1292-302.
- Tefferi A, Patnaik MM, Pardanani A. Eosinophilia: secondary, clonal and idiopathic. *Br J Haematol*. 2006;133: 468-92.
- Sanderson CJ. Interleukin 5, eosinophils, and disease. *Blood*. 1992;79:3101-3109.
- Peròs-Golubicic T, Smojver-Jezek S. Hypereosinophilic syndrome: diagnosis and treatment. *Curr Opin Pulm Med*. 2007; 13:422-7.
- Simon HU, Plotz SG, Dummer R, Blaser K. Abnormal clones of T cells producing interleukin-5 in idiopathic eosinophilia. *N Engl J Med*. 1999;341:1112-20.
- Zenone T, Feldman P, Malcus C, Durieu I, Durand DV. Indolent course of a patient with hypereosinophilic syndrome associated with clonal T-cell proliferation. *Am J Med*. 1999;107:509-11.
- Rouffosse F, Schandené L, Sibille C, Willard_Gallo K, Kennes B, Efir A, Goldman M, Cogan E. Clonal Th2 lymphocytes in patients with the idiopathic hypereosinophilic syndrome. *Br J Hematol*. 2000;109: 540-8.
- Umland SP, Nahrebne DK, Razac S, Beavis A, Pennline KJ, Egan RW. The inhibitory effects of topically active glucocorticoids in IL-4, IL-5 and Interferon gamma productions by cultured primary CD4⁺ T cells. *J Allergy Clin Immunol*. 1997;100:511-9.
- Garret JK, Jameson SC, Thomson B, Collins M, Wagoner L, Freese D, Beck L, Boyce J, Filipovich A, Villanueva J, Boyce J, Rothenberg M. Anti-interleukin5 (mepolizumab) therapy for hypereosinophilic syndromes. *J Allergy Clin Immunol*. 2004;113:115-9.
- Sefcick A, Sowter D, DasGupta E, Russell E, Byrne JL. Alemtuzumab therapy for refractory hypereosinophilic syndrome. *Br J Hematol*. 2004;124:558-9.
- Kim YJ, Prussian C, Martin B, Law M, Haverty T, Nutman T, Klion A. Rebound eosinophilia after treatment of hypereosinophilic syndrome and eosinophilic gastroenteritis with monoclonal anti-IL-5 antibody SCH55700. *J Allergy Clin Immunol*. 2004;114:1449-55.

■ *Manuscript received January 2, 2008; accepted for publication January 30, 2008.*

■ Purificación González Delgado

Allergology Department
Maestro Alonso 109
03010 Alicante, Spain
E-mail: gonzalez_pur@gva.es