

Hypersensitivity Pneumonitis Following Intravesical Bacille Calmette-Guérin Immunotherapy for Superficial Bladder Cancer

S-J Um, S-K Lee, D-K Yang

Department of Internal Medicine, College of Medicine, Dong-A University, Busan, Korea

■ Abstract

Hypersensitivity pneumonitis (HP) can be caused by drugs administered via routes other than the airway. We report a case of HP caused by intravesical bacille Calmette-Guérin (BCG) administered for the treatment of bladder cancer. We attempt to identify the causative agents of HP.

A 60-year-old, nonsmoking homemaker was referred to our hospital with nonresolving pneumonia. The patient had dyspnea, cough, and fever that started after 3 weekly cycles of intravesical BCG. High-resolution computed tomography of the chest revealed multiple tiny nodules and ground-glass opacities on both lung fields. Pulmonary function tests revealed a restrictive ventilatory defect with decreased diffusion capacity. Histopathology of the transbronchial lung biopsy specimens showed immature noncaseating granulomata. Immunoblotting analysis of serum and BCG demonstrated more than 10 immunoglobulin G fractions binding to BCG. This case illustrates that HP can be caused by intravesical instillation of BCG.

Key words: Alveolitis. Extrinsic allergic. BCG vaccine.

■ Resumen

La neumonitis por hipersensibilidad (NH) puede ser causada por fármacos administrados por rutas distintas de las aéreas. Notificamos un caso de NH causado por la administración intravesical del bacilo Calmette-Guérin (BCG) para el tratamiento de cáncer vesical. Tratamos de identificar el agente causal de la NH.

Un empleado del hogar de 60 años de edad no fumador fue referido a nuestro hospital por neumonía no resuelta. El paciente tenía disnea, tos, y fiebre que empezó después de 3 ciclos semanales de BCG intravesical. La tomografía computarizada de alta resolución del tórax reveló múltiples diminutos nódulos y opacidades en vidrio deslustrado en ambos campos pulmonares. Los test de función pulmonar revelaron un defecto ventilatorio restrictivo con disminución de la capacidad de difusión. La histopatología de las muestras de biopsia pulmonar transbronquial mostraron granulomas inmaduros no caseificantes. El análisis por inmunoblot del suero y BCG demostraron más de 10 fracciones de inmunoglobulina G unidas a BCG. Este caso ilustra que la NH puede ser causada por la instilación intravesical de BCG.

Palabras clave: Alveolitis. Alergia extrínseca. Vacuna BCG.

Introduction

Hypersensitivity pneumonitis (HP) is an immunologically mediated lung disease caused by repeated inhalation of organic antigens, most often as a result of occupational exposure [1].

However, various unrelated classes of medications, none of which is inhaled, have been associated with cases of pulmonary disease resembling HP [2].

We report a case of HP caused by intravesical bacille Calmette-Guérin (BCG) administered to treat bladder cancer.

This is the first report of HP following intravesical BCG immunotherapy in which the underlying immunological mechanism was evaluated using immunoblotting.

Case Description

A 60-year-old nonsmoking homemaker was referred to our hospital with unresolved pneumonia. The patient complained of dyspnea, cough, and fever that started after her third weekly cycle of intravesical BCG. Empiric antibiotic treatment was started, but there was no improvement. The initial physical examination revealed inspiratory crackles at both lung bases. The leukocyte count was $8340/\text{mm}^3$ (neutrophils, 66.8%; lymphocytes, 24.6%; monocytes, 5.3%; eosinophils, 3.1%). Liver function tests revealed aspartate aminotransferase 16 IU/L (10-35 IU/L) and alanine aminotransferase 12 IU/L (0-35 IU/L). The chest radiograph revealed diffuse haziness on both lower lung fields. High-resolution computed tomography of the chest (Figure 1) revealed multiple tiny nodules and ground-glass opacities on both lung fields. Spirometry showed a forced vital capacity (FVC) of 1240 mL (44% predicted), forced expiratory volume in 1 second (FEV_1) of 1130 mL (54% predicted), an FEV_1/FVC ratio of 82%, and a carbon monoxide diffusing capacity of 12.7 mL/min/mm Hg (44% predicted). Serum immunoglobulin (Ig) G (1540 mg/dL), IgA (374 mg/dL), and IgM (498 mg/dL) were increased. A skin prick test with 50 common aeroallergens was negative. Total IgE by CAP (Phadia, Uppsala, Sweden) was 181 kU_A/L . Sputum staining for *Mycobacterium tuberculosis* was negative. The analysis of bronchoalveolar lavage fluid showed lymphocytosis (77%) with a high CD8^+ T-lymphocyte count (77.8%) and a low $\text{CD4}^+/\text{CD8}^+$ ratio (0.2). Histopathology of the specimens obtained by transbronchial lung biopsy showed immature noncaseating granuloma with no evidence of infection by bacteria or acid-fast bacilli (Figure 2). To identify the causative agent, immunoblot analysis with serum and BCG (Organon,

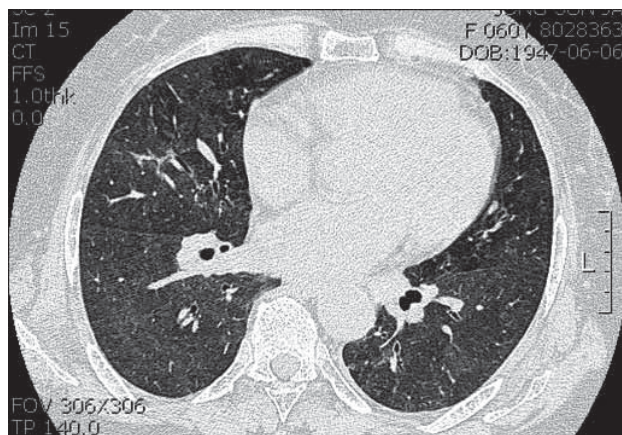


Figure 1. High-resolution chest computed tomography shows diffuse ground-glass opacity with ill-defined centrilobular or peribronchial nodules in both lung fields.

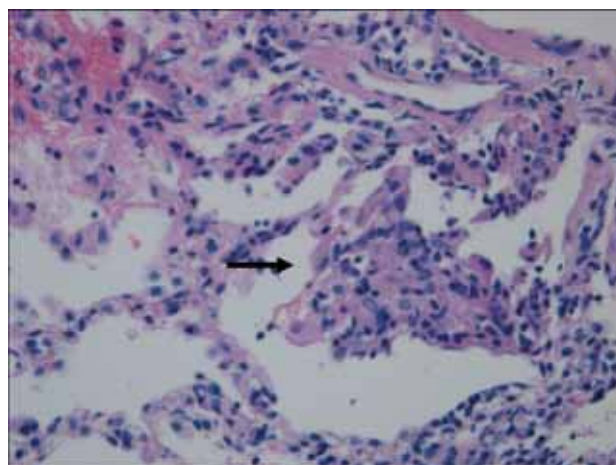


Figure 2. Microscopy of the transbronchial lung biopsy specimen shows a slightly thickened alveolar wall with lymphocytic infiltration and a poorly circumscribed small non-necrotizing granuloma composed of loosely aggregated histiocytes intermingled with lymphocytes (arrow) in the arteriolar interstitium (hematoxylin-eosin, $\times 400$).




Figure 3. IgG immunoblotting with sera from the patient (1) and controls (2-5). Controls 2 and 3 have no history of BCG vaccination. Numbers 4 and 5 have a history of BCG vaccination. Controls 3 and 5 have a history of pulmonary tuberculosis. Molecular size marker (M): multicolored standard (Novex, San Diego, California, USA); molecular weight: myosin (185 kDa), phosphorylase B (98 kDa), glutamic dehydrogenase (52 kDa), alcohol dehydrogenase (31 kDa), carbonic anhydrase (19 kDa), myoglobin (17 kDa), lysozyme (11 kDa), aprotinin (6 kDa), and insulin (3 kDa).

Oss, the Netherlands) was performed. Sodium dodecyl sulfate polyacrylamide gel electrophoresis (SDS-PAGE) was performed following the method of Laemmli [3]. The gel was then stained with Coomassie brilliant blue. There were more than 10 IgG fractions (41 kDa to 160 kDa) binding to BCG (Figure 3).

Once the diagnosis of HP had been confirmed, immunotherapy with BCG was discontinued and corticosteroids started. Clinical symptoms, abnormal findings on chest radiography, and spirometric abnormalities improved after 1 month of corticosteroids and avoiding exposure.

Discussion

The patient presented with dyspnea, cough, and fever after 3 weekly cycles of intravesical immunotherapy for superficial bladder carcinoma. The clinical, radiographic, physiologic, histopathologic, and immunologic findings were all compatible with HP caused by intravesical BCG.

BCG is an attenuated strain of bovine tuberculous bacterium and consists of living bacilli, dead microorganisms, and subcellular debris. Intravesical administration of BCG has proven effective against superficial bladder cancer [3]. Toxicity has been reported to be substantially greater with intensive regimens, although severe side effects have also been observed after only a few instillations [4]. Cases of HP following intravesical BCG immunotherapy are very rare. Furthermore, there are no immunological studies to suggest the association with BCG [5-7].

The diagnosis of HP must fulfill a series of clinical, radiographic, physiologic, histopathologic, and immunologic criteria—a single set is rarely sufficient. High-resolution computed tomography of the chest revealed ground-glass opacity, and spirometry showed restrictive ventilatory impairment with decreased diffusion capacity. Moreover, histopathology of a transbronchial lung biopsy specimen revealed noncaseating granulomas. All of these characteristics are consistent with the diagnosis of HP. Intravesical BCG could stimulate the production of specific antibodies.

Hematogenous spread of BCG during endoscopy may have favored sensitization in this patient. The presence of serum-specific IgG to BCG provided additional support for the diagnosis of HP. In Korea, the national BCG vaccination program began in 1964. However, our patient did not recall having received the BCG vaccination or antituberculosis treatment. Therefore, we thought that the IgG-binding components on the immunoblot represented proteins that had been sensitized as a result of intravesical BCG immunotherapy. Furthermore, we prescribed corticosteroids only and stopped further intravesical administration of BCG so that HP could be differentiated from disseminated BCG infection.

In our opinion, clinical findings are the most important aspect of the differential diagnosis between HP and disseminated BCG infection. There was subjective spontaneous improvement of symptoms after admission to hospital. However, in the case of disseminated BCG infection, the clinical course would deteriorate progressively. Radiography

also has an important diagnostic value in HP, and typically reveals ground-glass opacity. Histopathology usually reveals diffuse, temporally uniform chronic interstitial pneumonia with peribronchial accentuation. A focus of bronchiolitis obliterans with organizing pneumonia is observed in addition to the typical peribronchiolar chronic interstitial pneumonia. Granulomata point more to a hypersensitivity reaction than to dose-related toxicity.

Therefore, HP following intravesical BCG is a T lymphocyte-driven granulomatous reaction in response to a processed BCG protein. Further studies are required to evaluate the precise mechanism underlying HP caused by intravesical administration of BCG.

This manuscript was presented as a poster at the 2008 annual meeting of the KAAACI.

Acknowledgments

This paper was supported by Dong-A University research fund 2009.

References

1. Erkinjuntti-Pekannen R, Rytkonen H, Kokkarinen JI, Tukiainen HO, Pentonen K, Terho EO. Long-term risk of emphysema in patients with farmer's lung and matched control farmers. *Am J Respir Crit Care Med.* 1998;158:662-5.
2. Sandhu HS, Barnes PJ, Hernandez P. Hydroxyurea-induced hypersensitivity pneumonitis: a case report and literature review. *Can Respir J.* 2000;7:491-5.
3. Laemmle UK. Cleavage of structural proteins during the assembly of the head of bacteriophage T4. *Nature.* 1970;227:680-5.
4. Brosnan SA. Experience with bacillus Calmette-Guerin in patients with superficial bladder carcinoma. *J Urol.* 1982;128:27-30.
5. Lyons D, Miller I, Jeffers A. Systemic hypersensitivity reaction to intravesical BCG. *Scott Med J.* 1994; 39:49-50.
6. Reinert KU, Sybrecht GW. T helper cell alveolitis after bacillus Calmette-Guerin immunotherapy for superficial bladder tumor. *J Urol.* 1994;151:1634-7.
7. Molina JM, Rabian C, D'Agay MF, Modai J. Hypersensitivity systemic reaction following intravesical bacillus Calmette-Guerin: Successful treatment with steroids. *J Urol.* 1992;147:695-7.

■ *Manuscript received August 22, 2008; accepted for publication October 22, 2008.*

■ Soo-Keol Lee

3-1, Dongdaeshin-Dong, Seo-Gu, Busan
Republic of Korea 602-715
E-mail: skleeai@dau.ac.kr