
Late Reaction to Oral Nystatin: The Importance of Patch Testing

JM de la Borbolla, MJ Goikoetxea, P Cabrera-Freitag, G Gastaminza

Department of Allergology and Clinical Immunology, University Clinic of Navarra, Pamplona, Spain

Key words: Balsam of Peru. Cinnamic aldehyde. Late reaction. Nystatin.

Palabras clave: Bálsamo del Perú. Aldehído cinámico. Reacción tardía. Nistatina.

Serious complications can occur during the study of patients who develop allergic reactions while under treatment with multiple drugs. In such cases, it is necessary to conduct an exhaustive investigation of the drugs involved and comprehensive allergy tests with assessment of immediate and late reactions.

We present the cases of 2 patients that developed a late reaction to nystatin.

Case 1

A 63-year-old man with lung carcinoma and no history of contact dermatitis presented an intense erythematopapular eruption on his arms, back, and groin after a 3-day course of corticosteroids following chemotherapy. He had tolerated an initial chemotherapy cycle with paclitaxel and cisplatin well. The patient had received the following drugs: cisplatin, paclitaxel, granisetron, bemiparin, osmofundin, metoclopramide and was still under treatment with levothyroxine and nystatin (Mycostatin oral suspension). Nystatin was stopped and the lesions resolved within 7 days.

Patch tests performed with the European standard series of allergens and cisplatin, paclitaxel, granisetron, bemiparin, osmofundin, metoclopramide and Mycostatin oral suspension were positive only to balsam of Peru (+) at 48 and 96 hours. Interestingly, the patient tolerated the subsequent chemotherapy cycles with the same drugs except nystatin well.

Case 2

A 45-year-old woman, admitted to the psychiatry department of our hospital, presented pruriginous erythema on the face and neck that had appeared 3 days earlier. She had a history of contact dermatitis to metals. The patient was under treatment with amoxicillin and ibuprofen for a dental

treatment and nystatin (Mycostatin oral suspension) for an oral fungal infection related to the use of antibiotics. Amoxicillin and ibuprofen were discontinued but the skin eruption persisted for 1 month at other sites.

Six months later, the patient developed an erythematous reaction without hives on the face and neck several hours after being started on a course of nystatin (Mycostatin oral suspension) administered by error.

Patch tests performed with the European standard series of allergens, ibuprofen, amoxicillin and Mycostatin oral suspension, and the patient's perfume and bath gel were positive only for the fragrance mix (++++) at 96 hours.

Nystatin was replaced by fluconazole and the lesions showed progressive improvement over 7 to 10 days, with all symptoms disappearing within 1 month.

There was no apparent relationship between patch test positivity and the drugs administered in the 2 patients. On reviewing the composition of the drugs, we found that the commercial preparation of nystatin [1] (sodium saccharine, saccharose, ethanol, carboxymethyl cellulose, cinnamic aldehyde, peppermint essence, cherry flavor, disodium hydrogen phosphate, glycerin, methylparaben, and propylparaben) contained cinnamic aldehyde, which is also found in balsam of Peru and fragrance mix I.

We do not know why one of the patients had a positive reaction to balsam of Peru or why the other had a positive reaction to the fragrance mix, and we were unable to perform a specific patch test to confirm cinnamic aldehyde sensitization because the patients do not live in our city.

False negative results are common in patch testing with drugs [2]. In our patients, we believe that the concentration of cinnamic aldehyde in the nystatin preparation might be lower than that needed to yield a positive test reaction [3]. The concentration of cinnamic aldehyde in Mycostatin, however, is unknown. There are several reports of systemic contact dermatitis after the ingestion of cinnamic aldehyde [4], an ingredient used in products such as soft drinks, toothpaste, cinnamon oil, chewing gum, and chocolate. The patients involved had positive patch test reactions to balsam of Peru, fragrance mix, or cinnamic aldehyde. In our patients, we were unable to obtain direct evidence of cinnamic aldehyde sensitization because this compound was not evaluated in the patch tests performed.

In conclusion, we wish to highlight the importance of carefully evaluating allergy test results even in the absence of a clear cause-effect relationship.

References

1. Villas Martínez F, Muñoz Pamplona MP, Compes García E, GardeUrzaiz A. Delayed hypersensitivity to oral Nystatin. *Contact Dermatitis*. 2007;57:200-1.
2. Barbaud A, Reichert-Penetrat S, Tréchet P, Jacquin-Petit MA, Ehlinger A, Noirez V, Faure GC, Schmutz JL, Béné MC. The use of skin testing in the investigation of cutaneous adverse drug reactions. *Br J Dermatol*. 1998;139:49-58
3. Barranco R, Tornero P, de Barrio M, de Frutos C, Rodríguez A, Rubio M. Type IV hypersensitivity to oral nystatin. *Contact Dermatitis*. 2001;45:60.

4. Salam TN, Fowler JF Jr. Balsam-related systemic contact dermatitis. *J Am Acad Dermatol.* 2001;45:377-81

■ Manuscript received January 22, 2009; accepted for publication, February 11, 2009.

Juan Mariano de la Borbolla
 Department of Allergology and Clinical
 Immunology
 University Clinic of Navarra,
 Apartado 4209
 31008 Pamplona, Spain
 E-mail: delaborbolla@hotmail.com

Fixed Drug Eruption Induced By Phenylephrine: A Case of Polysensitivity

R López Abad, P Iriarte Sotés, M Castro Murga, M^aT Gracia Bara, P Sesma Sánchez
Allergy Unit, Department of Internal Medicine, Hospital Arquitecto Marcide, Ferrol, A Coruña, Spain

Key words: Fixed drug eruption. Phenylephrine. Sympathomimetic drugs. Cross-reactivity. Polysensitivity.

Palabras clave: Exantema fijo medicamentoso. Fenilefrina. Fármacos simpaticomiméticos. Reactividad cruzada. Polisensibilidad.

Fixed drug eruption (FDE) is a well-known entity that can be caused by a variety of drugs. In many cases, a single drug is responsible for FDE but in some patients, FDE lesions can develop following the administration of multiple drugs with common chemical structures. This is different from a phenomenon known as polysensitivity, where drugs or other agents with totally different chemical structures can cause exacerbations similar to those caused by the inducing drug [1,2].

A 22-year-old woman was referred for evaluation of an allergic reaction to Couldina (acetylsalicylic acid, chlorpheniramine, phenylephrine and ascorbic acid) on 3 occasions a month apart. Each reaction consisted of an identical eruption at the same place on the left forearm. These eruptions, which consisted of an itchy dusky-red macule, appeared within 12 to 24 hours of taking an initial dose of Couldina, a drug used to treat colds without fever. The drug was discontinued and the lesion improved within 5 days, leaving a residual hyperpigmented lesion for some weeks. Two months later, an identical lesion appeared in the same place when the patient took paracetamol for a headache.

She subsequently tolerated Rino-ebastel (ebastine and pseudoephedrine), a combination drug that the patient occasionally uses to treat rhinitis, on several occasions.

Patch tests were performed with acetylsalicylic acid (10% in petrolatum), paracetamol (20% in petrolatum) phenylephrine (1% in aqueous solution), adrenaline (undiluted), and

ephedrine and pseudoephedrine (1% in aqueous solution and petrolatum). The patches were applied to the patient's back and a residual lesion using Curatest (Lohmann, Marti Tor, Barcelona, Spain) and removed after 48 hours. Readings were carried out at 48 and 96 hours, as recommended by the International Contact Dermatitis Research Group [3]. All the results were negative except for phenylephrine on the residual lesion at 96 hours (Figure).

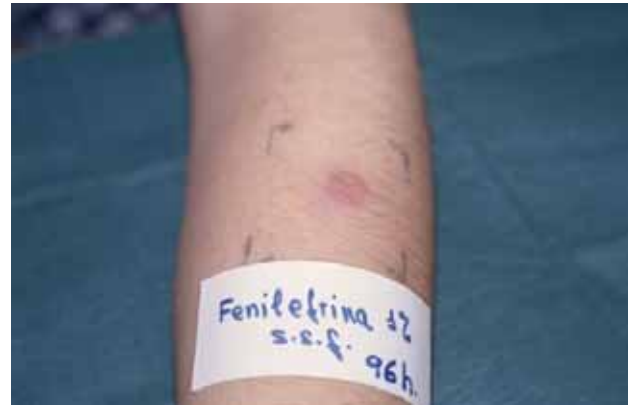

Figure. Reaction to patch test with phenylephrine on residual lesion at 96 hours.

In an oral challenge test, the patient showed good tolerance to acetylsalicylic acid but developed a positive reaction to paracetamol. The reaction consisted of the appearance of an identical erythematous violaceous macule in exactly the same place as the other lesions 8 hours after a dose of 500 mg of paracetamol.

Phenylephrine hydrochloride is a sympathomimetic drug used in ophthalmology and otorhinolaryngology for its mydriatic and vasoconstrictive properties. It is found in many drug products and is typically administered orally and locally, although it has been used parenterally in the treatment of hypotensive states.

We expected to find cross-reactivity between phenylephrine and other sympathomimetic drugs belonging to the phenylamine family but this is a controversial issue [4,5]. Ephedrine and pseudoephedrine are derived from a phenylpropanolamine skeleton, while phenylephrine and epinephrine are modified forms of phenylethanolamine and differ in terms of substitutions in the aromatic part of the molecule. These differences in chemical structures might explain the absence of cross-reactivity, although another explanation, proposed by Barranco et al [5], could be the insufficient standardization of diagnostic methods.

The drug concentrations and vehicles used to perform the patch tests on our patient were recommended by the pharmacy department at our hospital on the basis of concentrations found in commercial preparations.

The literature contains many reports of contact dermatitis to phenylephrine [6,7] and other sympathomimetic agents [8,9] but to the best of our knowledge, this is the first report of an

FDE to phenylephrine. Paracetamol-induced FDEs, in contrast, are more common [10,11].

Our clinical and patch test findings suggest that our patient might have been specifically sensitized to phenylephrine. Moreover, this is a case of FDE induced by 2 unrelated chemical substances, paracetamol and phenylephrine.

References

1. Shiohara T, Mizukawa Y. Fixed drug eruption: a disease mediated by self-inflicted responses of intraepidermal T cells. *Eur J Dermatol*. 2007;17(3):201-8.
2. Sehgal VN, Srivastava G. Fixed drug eruption (FDE): changing scenario of incriminating drugs. *Int J of Dermatol*. 2006;45(8):897-908.
3. Barbaud A, Goncalo M, Bruynzeel D, Bircher A; European Society of Contact Dermatitis. Guidelines for performing skin test with drugs in the investigation of cutaneous adverse drug reactions. *Contact Dermatitis* 2001;45:321-28
4. Gonzalo-Garrido MA, Pérez-Calderón R, de Argila D, Rodríguez-Nevado I. Erythrodermia to pseudoephedrine in a patient with contact allergy to phenylephrine. *Allergol Immunopathol (Madr)*. 2002;30(4):239-42.
5. Barranco R, Rodríguez A, de Barrio M, Trujillo MJ, de Frutos C, Matheu V, Tornero P, Herrero P. Sympathomimetic drug allergy: cross-reactivity study by patch test. *Am J Clin Dermatol*. 2004;5(5):351-5.
6. Barber KA. Allergic contact eczema to phenylephrine. *Contact Dermatitis* 1983;9(4):274-7. Akita H, Akamatsu H, Matsugana K. Allergic contact dermatitis due to phenylephrine hydrochloride, with an unusual patch test reaction. *Contact Dermatitis*. 2003; 49(5):232-5.
7. Akita H, Akamatsu H, Matsugana K. Allergic contact dermatitis due to phenylephrine hydrochloride, with an unusual patch test reaction. *Contact Dermatitis*. 2003; 49(5):232-5.
8. Garcia Ortiz JC, Terron M, Bellido J. Nonpigmenting fixed exanthema from ephedrine and pseudoephedrine. *Allergy*. 1997;52(2):229-0.
9. Vidal C, Prieto A, Perez Carral C, Armisen M. Nonpigmenting fixed drug eruption due to pseudoephedrine. *Ann Allergy Asthma Immunol*. 1998;80(4):309-10.
10. Morelli JP, Tay YK, Rogers M, Halbert A, Krafchik B, Weston WL. Fixed drug eruptions in children. *Journal of Pediatrics*. 1999;134(3):365-67.
11. Duhra P, Porter DI. Paracetamol-induced fixed drug eruption with positive immunofluorescence findings. *Clin Exp Dermatol*. 1990;15(4):293-5

■ Manuscript received November 8, 2008; accepted for publication, February 13, 2009.

M^a Teresa Gracia Bara,
Unidad de Alergia
Servicio de Medicina Interna
Hospital Arquitecto Marcide
C/ San Pedro de Leixa s/n
15004 Ferrol, A Coruña, Spain
E-mail: graciabaramayte@yahoo.es

Presence of Domestic Mites at an Extremely High Altitude (4800 m) in Andean Ecuador

R Valdivieso,¹ V Iraola,² H Pinto²

¹Allergy and Dermatology Center, Meditropoli Medical Center, Quito, Ecuador

²LETI, SL, laboratories, Tres Cantos, Madrid, Spain

Key words: Dust mites. High altitude. Los Andes. Ecuador.

Palabras clave: Ácaros del polvo. Grandes alturas. Los Andes. Ecuador

Studies conducted in Europe have demonstrated that house dust in mountainous areas contains very few or no domestic mites [1]. In Ecuador, in contrast, recent studies of domestic mite fauna in high-altitude cities (2500-2800 m) revealed the frequent and abundant presence of mites and their allergens in house dust samples [2]. These discrepancies between high-altitude areas in Europe and the Andean regions of South America might be due to climatic differences and particularly differences in ambient humidity.

Little is known, however, about the presence of domestic mites in altitudes above 3000 m in Andean regions. The shortage of dwellings and practical sampling difficulties make the collection of samples in this environment quite difficult.

We present the results of an analysis of dust samples collected in May 2006 at the Cotopaxi volcano mountain refuge José Ribas. The volcano lies 75 km south of the equator in Ecuador (78°26'W 00°39'S 5897 m) and is considered by many to be the highest active volcano in the world. It experiences sudden changes in weather and a daily variation in temperature from -5°C to -20°C. The mean relative humidity is ±75% but humidity levels fluctuate from less than 20% to saturation.

The mountain refuge is located at an altitude of 4800 m; the 2-floor structure holds over 100 climbers, who usually stay overnight before starting their ascent. The first floor contains a social area and a basic kitchen and the second floor is used exclusively for sleeping purposes. There is no wall or floor humidity, and no carpets, vegetables, or other stored materials. The restroom area is located outside the main house.

Because there was no electric power to run a vacuum cleaner, dust samples were collected by sweeping the floor of the bunk bed area. Ten samples were collected, each from an area measuring 1 m². All the samples were frozen for at least 48 hours to prevent the possible proliferation of mites. Dust samples were weighed and logged and 20-mg aliquots were suspended in a saturated saline solution and analyzed under a stereoscope. All the mites in each sample were collected using a fine needle and placed in 2 drops of Hoyer's medium on a microscope slide. Afterwards, the slide was covered and allowed to dry at 50°C for 24 hours. The slides were inspected under a microscope and the mite species identified in accordance with international identification keys and then counted. The frequency and abundance of mite species is shown in the Table. Both adult and immature forms of *Glyciphagus domesticus* were found, suggesting that this species is able to complete its life cycle in this habitat.

Only adults of *Dermatophagoides pteronyssinus* were found, however, indicating the possibility of passive transport via human clothing, as has been suggested for mite allergens found in high-altitude refuges in Switzerland [3].

Table. Frequency and Abundance of Mite Species in 10 Samples Collected at the Cotopaxi Volcano Refuge (Altitude, 4800 m)

	No. of Positive Samples	Geometric Mean (mites/g)	Range (mites/g)
Total mites	8	12.7	57.4-4.6
<i>Glycyphagus domesticus</i>	5	11.1	38.2-4.6
<i>Dermatophagoides pteronyssinus</i>	3	5.6	6.4-4.6
<i>Tydeidae species</i>	2	5.4	6.4-4.6
<i>Glycyphagus fusca</i>	1	6.4	
<i>Tarsonemus species</i>	1	47.8	

No detectable levels of Der p1 or Der f1 allergens were observed in the samples using enzyme-linked immunosorbent assay (Indoor Biotechnologies, Charlottesville, Virginia, USA) but we must emphasize the presence of allergenic mites, albeit at low levels, in a relatively high number of samples, despite the fact that the floor is not the favorite habitat for these species. Their presence in this extreme habitat highlights their ability to adapt to human environments and should be taken into account in environmental control programs. The 5 species found are constituents of domestic mite fauna described as present in mattress dust collected in cities of Ecuador. Additionally, *G domesticus* has been described as a cosensitizer for 11% of asthmatic and rhinitic residents of Quito (2800 m), and as an exclusive sensitizer in 0.5% of these [2].

References

1. Vervloet D, Penaud A, Razzouk H, Senft M, Arnaud A, Boutin C, Charpin J. Altitude and house dust mites. *J Allergy Clin Immunol*. 1982;69:290-96.
2. Valdivieso R, Iraola V, Estupiñán M, Fernández-Caldas E. Sensitization and exposure to house dust and storage mites in high-altitude areas of Ecuador. *Ann Allergy Asthma Immunol*. 2006;97:532-8.
3. Walliser M, Stadler BM. House dust mite allergen import into a naturally mite-free environment. *J Allergy Clin Immunol*. 1994;94:1073-4.

■ Manuscript received February 21, 2009. Accepted for publication, March 3, 2009.

Rommel Valdivieso

Allergy and Dermatology Center
Meditropoli Medical Center
Av Mariana de Jesús y Occidental
Quito, Ecuador
E-mail: rommelva@andinanet.net

Allergy to Dry Fermented Sausage

I Bobolea, P Barranco, J Jurado-Palomo, M Pedrosa, S Quirce
Department of Allergology, Hospital Universitario La Paz, Madrid, Spain

Key words: Food allergy. Labial challenge. Molds. Meat allergy. Dry sausage.

Palabras clave: Alergia a alimentos. Provocación labial. Hongos. Alergia a carnes. Fuet.

It is common practice to add flavor-enhancing molds to traditional foods such as dry sausage, salami, Spanish ham, and French cheese in Central and Southern Europe [1]. In Northern Europe, where the addition of molds to meat products is not permitted, there are studies that have demonstrated considerable levels of contamination by *Penicillium*, *Cladosporium*, and *Eurotium* molds in equipment and raw materials used during the manufacture of meat products [2]. Occupational respiratory diseases due to prolonged or repeated exposure to organic dust containing molds (rhinoconjunctivitis, asthma, hypersensitivity pneumonitis, and organic dust toxic syndrome) among food industry workers is also well documented [3]. Nevertheless, food allergy to mold proteins is rare [4], with very few reports in the literature [5].

We report the case of a 24-year-old man diagnosed with rhinoconjunctivitis and asthma due to allergy to pollens, mites, and molds at the age of 9 years. In the past year he had experienced 2 episodes of facial angioedema immediately upon ingestion of a few slices of dry sausage, which he had tolerated previously on many occasions. The symptoms subsided spontaneously in under 6 hours. He had avoided the sausage since and tolerated all other types of meat products.

We performed skin prick tests to common aeroallergens, meats (pork, beef, veal, chicken, and rabbit) and other common foodstuffs (egg, cow's milk, pepper, garlic, peanut, and nut), as well as prick-by-prick tests with the outer skin and the meat of the suspect sausage. Total serum immunoglobulin (Ig) E and specific IgE determinations were performed using the CAP system (Phadia, Uppsala, Sweden). A microbiological analysis and culture of the sausage skin was carried out in order to identify possible contaminants.

After obtaining the results of the aforementioned tests, we performed a labial food challenge in which the outer skin of the sausage was placed in brief contact with the patient's external lower lip.

Skin prick tests were positive for grass pollen, house dust mites, and molds (*Alternaria alternata*, *Penicillium notatum*, *Mucor racemosus*, and *Pullularia*, *Stemphylium*, *Helminthosporium*, and *Fusarium* spp.), and negative for all the food allergens tested. The prick-by-prick was positive for the outer sausage skin (7x7-mm wheal) and negative for the sausage meat.

Total serum IgE was 1513 kU/L. Specific IgE determinations were positive for *Alternaria alternata* (58 kU/L), *Mucor*

racemosus (2.67 kU/L), and *Penicillium notatum* (3.03 kU/L). The microbiologists isolated *Penicillium* and *Mucor* spp. in the sausage skin. The colonies can be seen in the Figure.

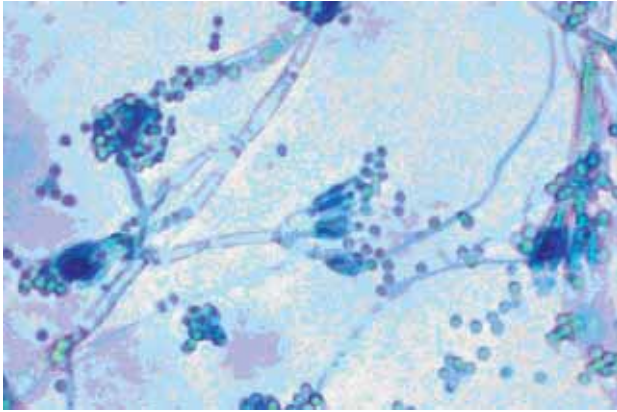


Figure. Colonies of *Penicillium* spp. isolated in the sausage skin.

The labial challenge test yielded a positive result, with onset of angioedema of the lips, tongue, and uvula within 5 minutes. The symptoms were treated with intravenous methylprednisolone and dexchlorpheniramine and subsided in 2 hours.

The diagnosis was facial angioedema after dry sausage ingestion due to IgE-mediated allergy to *Penicillium* and *Mucor* spp. The patient was advised to avoid all products commonly contaminated with molds such as dry fermented sausages, Spanish ham, foie gras, and French cheeses such as Roquefort and Camembert.

We believe that, though rare, molds should be considered a potential cause of food allergy in patients who have ingested fermented sausage or cheese. This is particularly relevant in asthmatic patients sensitized to molds by inhalation. It is also important to always try to determine the cause of a patient's allergy in order to prevent potentially severe reactions in the future.

We have reported one of the few cases of food allergy to *Penicillium* and *Mucor* spp. in the skin of dry Spanish sausage. We demonstrated that IgE-mediated hypersensitivity to the isolated molds was responsible for the patient's reaction and consider that primary sensitization probably occurred by the respiratory route as our patient was an asthmatic previously sensitized to molds.

References

1. López-Díaz TM, Santos JA, García-López ML, Otero A. Surface mycoflora of a Spanish fermented meat sausage and toxigenity of *Penicillium* isolates. *Int J Food Microbiol*. 2001;68:69-74.
2. Sorensen LM, Jacobsen T, Nielsen PV, Koch AG. Mycobiota in the processing areas of two different meat products. *Int J Food Microbiol*. 2008;124:58-64.
3. Rouzaud P, Soulat JM, Trela C, Lauque D. Symptoms and serum precipitins in workers exposed to dry sausage mould;

consequences of exposure to sausage mould. *Int Arch Occup Environ Health*. 2001;74:371-4.

4. Katona SJ, Kaminski ER. Sensitivity to Quorn Mycoprotein (*Fusarium venenatum*) in a mould allergic patient. *J Clin Pathol*. 2002; 55(11): 876-7.
5. Morisset M, Parisot L, Kanny G, Moneret-Vautrin DA. Food allergy to moulds: two cases observed after dry fermented sausage ingestion. *Allergy*. 2003;58:1203-4.

■ Manuscript received March 5, 2009. Accepted for publication, November 30, 2009.

Irina Bobolea
Allergology Department,
Hospital Universitario La Paz
Paseo de la Castellana 261
24806, Madrid, Spain

Drug Rash with Eosinophilia and Systemic Symptoms After Penicillin V Administration in a Patient with Acquired C1 Inhibitor Acquired Deficiency

I Doña,¹ P Chaves,² E Gómez,² M^aJ Torres,¹ Cantó G,³ M Blanca¹

¹Allergy Service, Carlos Haya Hospital, Málaga, Spain

²Research Unit for Allergic Diseases, Carlos Haya Hospital, Málaga, Spain

³Allergy Service, Infanta Leonor Hospital, Madrid, Spain

Key words: DRESS. Penicillin V. T-cell. Nonimmediate reaction. Lymphocyte transformation test.

Palabras clave: Penicilina V. Célula T. Reacción no inmediata. Test de transformación linfocitaria.

Nonimmediate allergic reactions to β -lactams can appear within an hour of drug intake but onset is usually after 24 to 48 hours. Typical symptoms are maculopapular exanthema and late-onset urticaria. The most common β -lactams involved in nonimmediate allergic reactions are aminopenicillins [1,2], although cephalosporins are gaining importance [3]. A T cell-mediated effector response has been shown to be involved [4], although the exact mechanisms are not completely understood [5,6]. We report the case of a patient with acquired C1 inhibitor deficiency who developed drug rash with eosinophilia and systemic symptoms (DRESS) after penicillin V administration.

The patient, a 44-year-old man, had developed acute facial and laryngeal angioedema requiring tracheotomy. We detected low antigenic (2 mg/dL) and functional C1 inhibitor levels (40% of normal values) as well as a decrease in C4 (1 mg/dL) and C1q (70 mg/L) levels. An abdominal ultrasound showed giant splenomegaly (>30 cm). The patient was diagnosed with acquired C1 inhibitor deficiency secondary to non-Hodgkin lymphoma. The spleen was excised and penicillin V treatment was initiated at 800 mg/day for pneumococcal

prophylaxis. Five days after the start of treatment, the patient developed a maculopapular exanthema on the trunk and arms with fever (39°C). Treatment was continued for 2 days but the lesions spread and the patient continued with persistent fever and considerable malaise. Penicillin V was replaced by levofloxacin and sulfonamides, and the fever and malaise subsided 3 days later. The maculopapular exanthema persisted for 1 week, however, but then began to disappear progressively until it had fully cleared by day 15. Serology was negative for *Toxoplasma gondii*, *Treponema pallidum*, Rubeola, parvovirus B19, cytomegalovirus, Epstein-Barr virus, human herpes virus 6, and hepatitis B and C virus.

A skin biopsy was processed for hematoxylin-eosin and immunohistochemical staining [3] using the following polyclonal antibodies: CD4 (Novocastra Laboratory, Newcastle upon Tyne, UK), CD8, CD45RO, and HLA-DR (Dako, Ely, Cambridgeshire, UK) and CLA (BD Pharmingen, San Diego, California, USA). There was a high T-cell infiltrate, with a predominant expression of CD8⁺ cells compared to CD4, CLA and HLA-DR cells at the perivascular site and the dermal-epidermal junction. All of these markers were also found, but to a lesser extent, in the epidermis, where moderate keratinocyte death was observed with hematoxylin-eosin.

The patient was observed from day 2 after onset of the reaction until day 30, with determination of eosinophils, liver enzymes (aspartate aminotransferase [AST] and alanine

aminotransferase [ALT]), T-cell subpopulations (CD4⁺, CD8⁺, and natural killer [NK] cells), and activation (HLA-DR) and cytotoxic markers (perforin and granzyme) in peripheral blood mononuclear cells [4] with the following monoclonal antibodies: CD3-PerCP, CD4-APC, CD8-APC, HLA-DR-PE, CD16-FITC, perforin-FITC and granzyme B-PE (Becton-Dickinson, San Jose, California, USA). There was a parallel increase in eosinophil cell counts and liver enzymes that peaked on day 7 with 1457.92 eosinophils/mL, 795 IU/L ALT, and 210 IU/L AST. An increase was also seen in the percentage of activated CD8⁺ T cells (HLA-DR) and cytotoxic marker levels (granzyme and perforin). The increase in NK cells was lower and there was a marked decrease in CD4⁺ T cells (Figure).

One month after the reaction subsided, patch testing [6] using major and minor determinants of benzylpenicillin (Diater, Madrid, Spain), amoxicillin (GSK, Madrid, Spain) and penicillin V (ERN, Barcelona, Spain) was negative at 48, 72, 96 hours. Lymphocyte transformation tests (LTT) with penicillin V, amoxicillin, and benzylpenicillin at different concentrations (100, 50 and 10 µg/mL) were positive in all cases (stimulation index [SI], >2), with a maximum SI of 3.5 at the highest penicillin V concentration.

We have presented the case of a patient who developed a nonimmediate reaction to penicillin V, confirmed by LTT. Monitoring acute response indicated a preferential participation of CD8⁺ T cells and cytotoxic mechanisms. To the best of

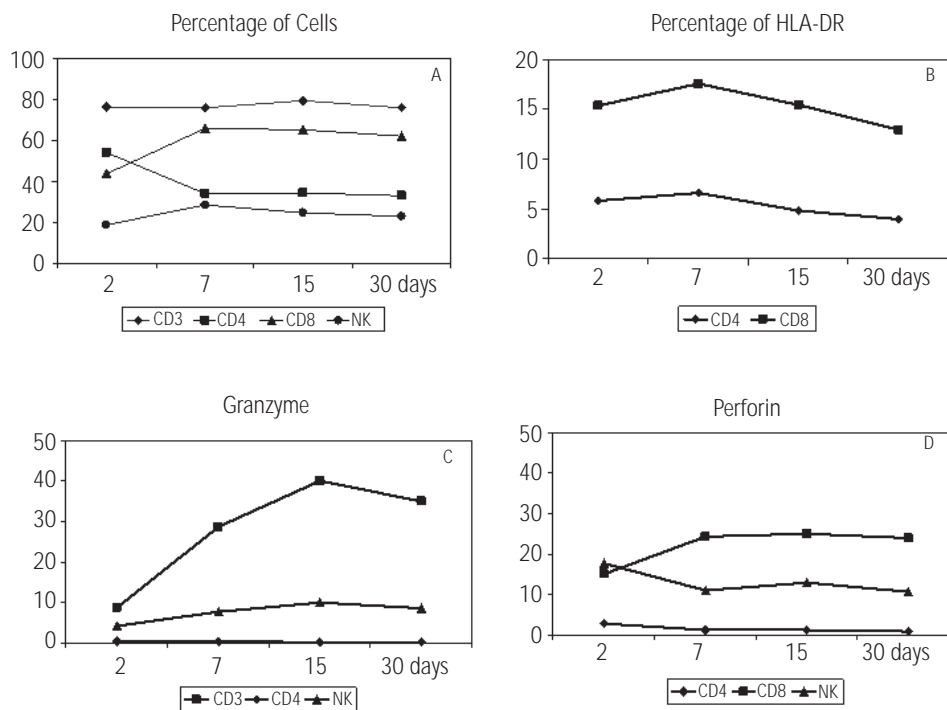


Figure. Percentage of T cells expressing different markers at different time points. A, CD3, CD4, CD8 and CD16 expression. B, HLA-DR expression in CD4 and CD8 subpopulations. C, granzyme B expression in CD4, CD8 and natural killer (NK) subpopulations. D, perforin expression in CD4, CD8, and NK subpopulations.

our knowledge, this is the first report of DRESS induced by penicillin V with detailed monitoring of allergic response. This is of note because such reactions are usually caused by aminopenicillins. It is not known whether or not the patient's immunological status might have contributed to the induction of the reaction.

Sources of Funding

This study was supported by grant Rdo7/0064 from the Adverse Allergen and Drug Reactions Drugs Research Network (RIRAAF) as part of the Spanish Health Research Fund FIS.

References

1. Romano A, Di Fonso M, Papa G, Pietroantonio F, Federico F, Fabrizi G, Venuti A. Evaluation of adverse cutaneous reactions to aminopenicillins with emphasis on those manifested by maculopapular rashes. *Allergy*. 1995;50:113-8.
2. Terrados S, Blanca M, Garcia J, Vega JM, Torres MJ, Carmona MJ, Miranda A, Moya M, Juarez C, Fernandez J. Non-immediate reactions to betalactams: prevalence and role of the different penicillins. *Allergy*. 1995;50:563-7.
3. Padial A, Antunez C, Blanca-Lopez N, Fernandez TD, Cornejo-Garcia JA, Mayorga C, Torres MJ, Blanca M. Non-immediate reactions to beta-lactams: diagnostic value of skin testing and drug provocation test. *Clin Exp Allergy*. 2008;38:822-8.
4. Mayorga C, Pena RR, Blanca-López N, López S, Martín E, Torres MJ. Monitoring the acute phase response in non-immediate allergic drug reactions. *Curr Opin Allergy Clin Immunol*. 2006;6:249-57.
5. Romano A, Blanca M, Torres MJ, Bircher A, Aberer W, Brockow K, Pichler WJ, Demoly P; ENDA; EAACI. Diagnosis of nonimmediate reactions to beta-lactam antibiotics. *Allergy*. 2004;59:1153-60.
6. Torres MJ, Sánchez-Sabaté E, Alvarez J, Mayorga C, Fernández J, Padial A, Cornejo-García JA, Bellón T, Blanca M. Skin test evaluation in nonimmediate allergic reactions to penicillins. *Allergy*. 2004;59:219-24.

■ Manuscript received November 12, 2008. Accepted for publication, March 5, 2009.

Inmaculada Doña Díaz
Servicio de Alergología,
Hospital Carlos Haya
Pl. Hospital Civil, 29009 Malaga, Spain
E-mail: inmadd@hotmail.com

Hereditary Angioedema and Chronic Urticaria: Is there a Possible Association?

A Smith Jorge, S Duarte Dortas Junior, S Oliveira Rodrigues Valle, A Tavares França
Clinical Immunology Department, University Hospital Clementino Fraga Filho (HUCFF-UFRJ), Rio de Janeiro, Brazil

Key words: Hereditary angioedema. Urticaria. Dermatographism. Delayed pressure urticaria.

Palabras clave: Angioedema hereditario. Urticaria. Dermografismo. Urticaria retardada por presión.

Hereditary angioedema (HAE) is a rare genetic disease with an autosomal dominant inheritance pattern caused by C1 inhibitor (C1INH) deficiency [1]. Urticaria is not typically associated with HAE but it can occur in some patients, although in mild forms and for short periods of time [2].

A 22-year-old female Brazilian student diagnosed with HAE 13 years earlier was admitted to the Rio de Janeiro Federal University Hospital in January 2006. Her history revealed angioedema attacks once or twice a year. These episodes became more frequent (once weekly) when she started to use oral contraceptives. The episodes disappeared when she stopped using the contraceptives and started to take ϵ -aminocaproic acid (3 g daily).

Five months later, during a routine visit, the patient complained of foot pruritus and pain that appeared after a couple of hours of walking, as well as edema and pain caused by pressure on the skin (when carrying a heavy bag, for example). These symptoms improved after 4 to 6 hours. She also reported wheal and flare around lesions that had started 8 weeks earlier, mostly affecting her legs and feet and worsening after scratching. These reactions generally lasted about 1 to 4 hours.

Her family history was remarkable for HAE in her mother and in 2 cousins, who had both developed fatal laryngeal edema.

Laboratory tests included serum tests, physical urticaria challenge tests, and an autologous serum skin test (ASST). Serum test results were within normal limits except for C1INH (5 mg/dL) and C4 (4 mg/dL), confirming the diagnosis of HAE. The ASST, delayed pressure urticaria, and dermatographism challenge tests were positive (Figure).

The patient was advised to avoid situations that could cause delayed pressure urticaria. She was also prescribed hydroxyzine at 25 mg/d to control autoimmune chronic urticaria (AICU) and dermatographism.

The estimated prevalence of HAE is 1 case per 150 000 population [1]. Age of onset is variable, and the condition may present before the age of 1 year [3]. HAE is characterized by recurrent nonhealing and nonpruritic swelling, which typically affects the face, the extremities, and the genitals and lasts for 2 to 5 days. Recurrent abdominal pain is reported in 70% to 80% of patients. It is a life-threatening disease



Figure. Dermatographism lesions on the patient's back.

because if the swelling affects the larynx, it can cause death by asphyxia [2]. Symptoms often worsen with estrogen-containing birth control pills or hormone replacement therapy [4].

Our patient had long-lasting physical urticaria and a positive ASST and was diagnosed with delayed pressure urticaria after being submitted to the Warin test [5]. However, it is important to point out that microtrauma can cause edema in patients with HAE. In such cases, however, lesions appear immediately after the trauma, and pain and redness of the skin are usually mild or even absent. In delayed pressure urticaria, lesions appear between 30 minutes and 9 hours after trauma and they are usually painful and/or characterized by a local burning sensation and erythema.

Kinins probably play a role in delayed pressure urticaria. One possible explanation would be that the pressure reduces tissue oxygenation, generating local acidosis, which would decrease kininase function, and in turn increase kinin levels, causing local edema [6].

The present case shows a rarely described association. It is well known that patients with HAE do not typically have concomitant urticaria. Our patient had been diagnosed with HAE in childhood and in her early twenties had started to complain of urticaria attacks, mainly after pressure was applied to her skin.

We believe that the concomitance of HAE and delayed pressure urticaria in this patient might be explained by the participation of kinin peptides in both conditions.

References

1. Bowen T, Cicardi M, Bork K, Zuraw B, Frank M, Ritchie B, et al. Hereditary angioedema: a current state-of-the-art review, VII: Canadian Hungarian 2007 International Consensus Algorithm for the Diagnosis, Therapy, and Management of Hereditary Angioedema. *Ann Allergy Asthma Immunol.* 2008;100(Suppl 2):S30-S40.
2. Agostoni A, A-Pürsün E, Binkley KE, Blanch A, Bork K, Bouillet L, et al. L. Hereditary and acquired angioedema: Problems and progress: Proceedings of the third C1 esterase inhibitor deficiency workshop and beyond. *J Allergy Clin Immunol.* 2004; 114:S51-131.
3. Bork K, Meng G, Staubach P, Hardt J. Hereditary Angioedema: New findings concerning symptoms, affected organs and course. *Am J Med.* 2006;119:267-74.
4. Zuraw BL. Diagnosis and management of hereditary angioedema: an American approach. *Transfus Apher Sci.* 2003;29:239-45.
5. Warin Test: Warin RP. Clinical observations on delayed pressure urticaria. *Br J Dermatol* 1989 Aug; 121 (2): 225-8.
6. Guimarães PV, Reis FAA, Valle SOR, de la Reza D, Abe AT, França AT. Angioedema Hereditário. In: *Urticária e Angioedema - Diagnóstico e Tratamento.* 2. ed. Rio de Janeiro: Revinter, 2006:177-97.

■ Manuscript received November 13, 2009. Accepted for publication, March 16, 2009.

Adriana Smith Jorge

S122/202 Rua Aníbal de Mendonça
Ipanema, Rio de Janeiro
22410-050 Brazil
Email: rodriguesvalle@terra.com.br

Are Selective COX-2 Inhibitors a Safe Option in Patients With Intolerance to Nonsteroidal Antiinflammatory Drugs?

M^a Dolores Quiñones Estévez

Departamento de Alergología, Hospital Monte Naranco, Oviedo, Spain

Key words: Alternatives. Cox-2 inhibitors. Intolerance. Nonsteroidal antiinflammatory drugs (NSAIDs).

Palabras clave: Alternativas. Inhibidores de la cox-2. Intolerancia. Anti-inflamatorios no esteroideos (AINEs).

Nonsteroidal antiinflammatory drugs (NSAIDs) have antiinflammatory, analgesic, and antipyretic effects and are among the drugs that most commonly cause adverse reactions. The main mechanism underlying the antiinflammatory action of these drugs is inhibition of the enzyme cyclooxygenase (COX), which has 2 known isoforms: the constitutive COX-1 isoform and the inducible COX-2 isoform, each with different characteristics.

Intolerance reactions to NSAIDs are common and caused by inhibition of the COX-1 enzyme. Selective COX-2 NSAIDs have been associated with a lower frequency of side effects than nonselective NSAIDs and may therefore be a safe alternative for use in patients with NSAID intolerance.

Selective COX-2 inhibitors are currently classified as preferential or specific. The first group includes "preferably" selective COX-2 inhibitors such as nimesulide (withdrawn from the market) and meloxicam, which are both significantly better inhibitors of COX-2 than of COX-1. This selectivity for COX-2, however, decreases with increasing doses. The second group encompasses drugs such as celecoxib, etoricoxib and rofecoxib (withdrawn) that are much more selective in terms of inhibiting COX, even with increasing doses.

We retrospectively evaluated data from 8 patients found to have COX-2 inhibitor intolerance on referral to our department for evaluation of NSAID intolerance.

In patients in whom more than 1 family of NSAIDs was involved in the reactions, paracetamol and COX-2 inhibitors were tested, and in patients in whom only 1 NSAID was involved and tolerance to other NSAID families had not been previously tested, the implicated NSAID was tested first except when the patient preferred to start with an alternative.

Single-blind placebo-controlled oral challenge tests were performed with paracetamol (cumulative dose, 1 g), meloxicam (cumulative dose, 22.5 mg), celecoxib (cumulative dose, 400 mg) and/or etoricoxib (cumulative dose, 90 mg). The clinical characteristics of each patient and the results of the challenge tests performed are shown in the Table.

Meloxicam and celecoxib were tested in all patients and etoricoxib was tested in all patients but 3. All of the patients reacted to meloxicam (angioedema or cutaneous rash), 2 patients tolerated etoricoxib but not celecoxib, and 1 patient tolerated celecoxib and not etoricoxib. Four patients tolerated paracetamol but only 1 of these tolerated the 1-g dose. Finally, the only 2 patients that tolerated celecoxib also tolerated paracetamol.

Although our series was small, it is striking that all of the patients were women, that a large percentage were also allergic to other drugs, and that they all had mucosal or cutaneous involvement.

Numerous safety and tolerance studies have been conducted in patients with NSAID intolerance since COX-2 inhibitors became available [1-3] and selective COX-2 inhibition has been implicated in the symptoms of bronchial asthma induced by acetylsalicylic acid [4].

Table. Clinical Characteristics of Patients and Results of Challenge Tests

Patient	1	2	3	4	5	6	7	8
Sex	Woman	Woman	Woman	Woman	Woman	Woman	Woman	Woman
Age, y	50	55	64	38	70	26	42	49
History of atopy	No	Asthma due to dust mites	No	Rhinitis and asthma due to dust mites	No	No	No	No
Drugs involved in NSAID intolerance reaction	Ibuprofen	Acetylsalicylic acid, paracetamol, diclofenac	Ibuprofen diclofenac, aceclofenac, piroxicam	Ibuprofen diclofenac, paracetamol 1 g	Aceclofenac diclofenac, ibuprofen, indomethacin, piroxicam, paracetamol, etoricoxib	Ibuprofen	Naproxen	Ibuprofen Paracetamol 1 g
Symptoms	Dyspnea (uvula edema)	Palm itch and generalized urticaria	Undefined cutaneous rash	Generalized cutaneous rash and dyspnea	Eyelid and facial edema	Itchy rash on the trunk	Generalized cutaneous rash	Eyelid angioedema
Paracetamol	Not tested; tolerance to 650 mg at home	Not tested: (involved in intolerance reaction)	Tolerance to 500 mg, positive reaction to 1 g	Positive reaction to doses of less than 500 mg	Positive	Positive	Tolerance to 1 g	Tolerance to 500 mg
Meloxicam	Positive	Positive	Positive	Positive	Positive	Positive	Positive	Positive
Etoricoxib	Not tested	Tolerated (90 mg)	Not tested	Tolerated (60 mg)	Positive	Positive	Positive	Not tested
Celecoxib	Positive	Positive	Positive	Positive	Positive	Positive	Tolerated	Tolerated
Other drug allergies	β -lactams	β -lactams, lidocaine	β -lactams	β -lactams	No	β -lactams	No	No

Apart from the role that these drugs may play in NSAID intolerance, a variety of adverse reactions have been described for COX-2 inhibitors [5-9]. The existence of genetic polymorphisms postulated by some authors [10] might explain the differences detected in terms of tolerance to etoricoxib and celecoxib, but these differences might also be related to the different inhibitory potency of these drugs (half maximal inhibitory concentration [IC50] COX-2:IC50 COX-1 ratio of 30 for celecoxib and 344 for etoricoxib).

The variability of reported results has led to the recommendation that COX-2 inhibitors should be tested by an experienced allergist before being used in patients with analgesic intolerance [4-9]. More studies are needed to assess possible risk factors for intolerance to COX-2 inhibitors, as well as possible cross-reactions.

References

- González Pérez R, Poza Guedes P, Vives R, Canto G. Revisión: Antiinflamatorios inhibidores selectivos de la ciclooxigenasa-2 (COX-2). *Alergol Inmunol Clin*. 2002;17:247-54.
- Tobias Bernd Weberschock, Sylke-Monina Müller, Sandra Boehncke, and Wolf-Henning Boehncke. Tolerance to coxibs in patients with intolerance to non-steroidal anti-inflammatory drugs (NSAIDs): a systematic structured review of the literature. *Arch Dermatol Res*. 2007;299(4):169-75.
- Vázquez-Cortés S, Vázquez-Fuertes L, Rodríguez-Alvarez M, Reig Rincón de Arellano I, Martínez-Cócera C. Tolerance to celecoxib and meloxicam in patients with intolerance to nonsteroidal anti-inflammatory drugs. *Anales de Medicina interna* 2008 Apr, 25(4): 163-7.
- Szczeklik A, Nizankowska E, Bochenek G, Nagraba K, Mejza F, Swierczynska M. Safety of a specific COX-2 inhibitor in aspirin-induced asthma. *Clin Exp Allergy*. 2001; 31: 219-25.
- Feliú A, Lozoya C, Jiménez A, Canto G. Reacción adversa a inhibidores de la COX-2: a propósito de 3 casos. *Alergol Inmunol Clin* (in press).
- Levy MB, Fink JN. Anaphylaxis to celecoxib. *Ann Allergy Asthma Immunol*. 2001;87:72-3.
- Verbeiren S, Morant C, Charlanne H, Ajebbar K, Cazon J, Modiano P. Celecoxib-induced toxiderma with positive patch test. *Ann Dermatol Venereol*. 2002;129:203.
- Fye KH, Crowley E, Berger TG, LeBoit PE, Connolly MK. Celecoxib-induced Sweet's syndrome. *J Am Acad Dermatol*. 2001;45:300-2.
- Schneider F, Meziani F, Chartier C, Alt M, Jaeger A. Fatal allergic vasculitis associated with celecoxib. *Lancet*. 2002;359:852-3.
- Mastalerz L, Sanak M, Gawlewicz A, Gielicz A, Faber J, Szczeklik A. Different eicosanoid profile of the hypersensitivity reactions triggered by aspirin and celecoxib in a patient with sinusitis, asthma, and urticaria. *J Allergy Clin Immunol*. 2006;118(4):957-8.

■ Manuscript received December 16, 2008; accepted for publication March 18, 2009.

M^a Dolores Quiñones Estévez
Hospital Monte Naranco
Avda. Dres Fernández Vega, 107
33012 Oviedo, Spain
E-mail: quinonesd@orange.es

Severe Immunoglobulin E-Mediated Anaphylaxis to Intravenous Methylprednisolone Succinate in a Patient Who Tolerated Oral Methylprednisolone

N Koutsostathis, V Vovolis

Department of Allergy and Clinical Immunology, Laiko General Hospital, Athens, Greece

Key words: Methylprednisolone succinate. Methylprednisolone. Corticosteroids. Allergy. Anaphylaxis.

Palabras clave: Succinato de metilprednisolona. Metilprednisolona. Corticoesteroides. Alergia. Anafilaxia.

A 26-year-old woman was hospitalized for a dental operation. Before discharge, she received intravenous methylprednisolone succinate (MP-SS), omeprazole, and parecoxib consecutively. She experienced generalized itching, facial angioedema, bronchospasm, and shock within 5 minutes of administration. The patient recovered after receiving adrenaline and intravenous fluids.

She had no other chronic diseases or previous exposure to systemic corticosteroids. In the past, she had occasionally used ocular and cutaneous corticosteroids (dexamethazone) because of infectious conjunctivitis and finger warts. Using NaCl 0.9%, we prepared dilutions of MP-SS (initial solution, 62.5 mg/mL) and hydrocortisone succinate (HC-SS) (initial solution, 125 mg/mL) ranging from 1:1 to 1:10 000.

We performed a skin prick test (SPT) with 3 different dilutions (1:1, 1:10, and 1:100) and an intradermal test (IDT) with both MP-SS and HC-SS at a dilution of 1:10 000 (Table), and the results for both were positive. The results were negative for 5 healthy control patients. The results of specific immunoglobulin (IgE) determination in serum (CAP-fluoroenzyme immunoassay, Phadia Laboratories, Uppsala, Sweden) were negative for MP-SS.

We also performed SPT and IDT with injectable omeprazole and injectable parecoxib, and the results were negative. The results of SPT at a dilution of 1:1 dilutions and IDT at 1:10 to 1:1000 dilutions using injectable prednisolone (25 mg/mL), dexamethazone phosphate (4 mg/mL), betamethasone acetate (3 mg/mL), methylprednisolone acetate (20 mg/mL), chloramphenicol succinate (100 mg/mL), and MP-SS preservative were all negative. SPT with a hydrocortisone tablet (20 mg) and methylprednisolone tablet (16 mg) were also negative. All SPT with aeroallergens, food allergens, and latex were negative. The serum tryptase level was normal (4.20 µg/L).

The results of oral challenge with methylprednisolone tablets (16 mg/tab), prednisolone (20 mg/tab), dexamethazone (1 mg/tab), and omeprazole (20 mg/caps), and intravenous challenge with parecoxib (40 mg/vial) were negative. All challenges were single-blind placebo-controlled and were graded using incremental doses (1:100, 1:30, 1:10, 1:3, and 1:1) of 1 tablet or 1 vial of drug every 30 minutes. Challenges with MP-SS and HC-SS were not performed for ethical reasons.

Although corticosteroids are widely used, anaphylactic reactions to these agents are infrequent. However, they can be

Table 1. Patient Characteristics^a

Drug	SPT	IDT	Challenge
Methylprednisolone succinate	+ 62.5 mg/mL (1:1) 10×5 mm	+ 0.00625 mg/mL (1:10.000) 10×13 mm	ND
	+ 62.5 mg/mL (1:10) 6×4 mm		
	+ 0.625 mg/mL (1:100) 5.5×3mm		
Hydrocortisone succinate	+ 125 mg/mL (1:1) 6×5 mm	+ 0.0125 mg/mL (1:10.000) 9×8.5 mm	ND
	+ 12.5 mg/mL (1:10) 5×4 mm		
	+ 1.25 mg/mL (1:100) 4×4 mm		
Chloramphenicol succinate	–	–	ND
Methylprednisolone acetate	–	–	ND
Methylprednisolone	–	–	Negative
Hydrocortisone	–	–	ND
Dexamethazone phosphate	–	–	Negative
Betamethasone acetate	–	–	ND
Prednisolone	–	–	Negative
Methylprednisolone succinate preservatives	–	–	ND

^a Positive results are shown with the dilution used and wheal dimensions. Abbreviations: IDT, intradermal test; ND, not determined; SPT, skin prick test.

life-threatening or fatal [1-3]. The most commonly involved agents seem to be MP-SS and HC-SS, because of their high affinity to serum proteins [4-6].

In the case we report, injectable MP-SS was responsible for anaphylaxis, as revealed by positive skin test results with MP-SS and negative challenge results with omeprazole and parecoxib. In addition, IgE antibodies showed high epitope specificity against the succinate moiety of injectable methylprednisolone, because skin testing revealed cross-reactivity only with HC-SS and not with other pure or acetate corticosteroid preparations (eg, methylprednisolone acetate). Moreover, our patient tolerated an oral challenge with a methylprednisolone tablet. Therefore, the succinate part was necessary for this reaction to occur and the pure corticosteroid molecule was not able to induce the reaction [6]. These IgE antibodies did not react with the same succinate salt of noncorticosteroid reagents, such as chloramphenicol succinate, indicating that a part of the corticosteroid molecule participated in the conformation of the responsible epitope.

Our results confirm data from previous studies that reported positive skin test results with corticosteroid succinate salts but not with pure or acetate salts [5-9]. We conclude that the reaction in our case was caused by IgE antibodies targeting an epitope consisting of the succinate salt and a stereochemical part of methylprednisolone. A similar epitope on HC-SS might explain the positive skin test result to HC-SS.

Contrary to data in the medical literature, our patient had no predisposing risk factors such as hypersensitivity to nonsteroidal anti-inflammatory drugs or previous significant exposure to parenteral corticosteroids [2,3,5-10]. Clinicians should be aware that severe anaphylactic reactions to corticosteroids can occur in any individual, even in the absence of predisposing factors. Skin testing with corticosteroids seems to be a safe way to reveal sensitization to injectable corticosteroids and to find an alternative corticosteroid preparation, as verified by challenge tests.

Acknowledgments

The authors declare no conflicts of interest.

References

- Vervloet D, Pradal M, Castelain M. Corticosteroids In: Drug Allergy, 3rd ed., Pharmacia & Upjohn, 1999.
- Saito R, Moroi S, Okuno H, Ogawa O. Anaphylaxis following administration of intravenous methylprednisolone sodium succinate in a renal transplant recipient. *Int J Urol*. 2004 Mar;11(3):171-4.
- Mansfield LE, Ting S, Haverly RW. Anaphylaxis caused by the sodium succinate ester of hydrocortisone and methylprednisolone. *J Asthma*. 1986;23(2):81-3.

4. Freedman MD, Shocket AL, Chapel N, Gerber JG. Anaphylaxis after intravenous methylprednisolone administration. *J Am Med Assoc.* 1981;245:607-8.
5. Ventura MT, Calogiuri GF, Matino MG, Dagnello M, Buquicchio R, Foti C, Corato R.DI. Alternative glucocorticoids for use in cases of adverse reaction to systemic glucocorticoids: a study on 10 patients. *Br J Dermatol.* 2003;148:139-41.
6. Caimmi S, Caimmi P, Bousquet J and Demoly P. Succinate as opposed to glucocorticoid itself allergy. *Allergy.* 2008;63:1641-3.
7. Burgdorff T, Venemalm L, Vogt T, Landthaler M, Stolz W. IgE-mediated anaphylactic reaction induced by succinate ester of methylprednisolone. *Ann Allergy Asthma Immunol.* 2002 Oct;89(4):425-8.
8. Peces R, Gorostidi M, Azofra J, Sanchez L, Alvarez J. Anaphylaxis following intravenous methylprednisolone sodium succinate in a renal transplant recipient. *Nephron.* 1991;59(3):497-8.
9. Doezeza D. Anaphylaxis following administration of intravenous methylprednisolone sodium succinate. *Am J Emerg Med.* 1987 Jan;5(1):42-4.
10. Schonwald S. Methylprednisolone anaphylaxis. *Am J Emerg Med.* 1999 Oct;17(6):583-5.

■ Manuscript received November 20, 2008; accepted for publication March 25, 2009.

Vasilios Vovolis, MD, PhD

Department of Allergy and Clinical Immunology
Laiko General Hospital,
Agiou Thoma 17
Goudi, Athens, Greece
vasvovolis@gmail.com

Allergy to Chinchilla

B Fernández-Parra,¹ C Bisson,² S Vatini,² A Conti,² A Cisteró Bahima³

¹ Allergy Department, Hospital el Bierzo, Ponferrada, Spain

² CNR-ISPATorino c/o Bioindustry Park, Italy

³ Instituto Universitario Dexeus, Barcelona, Spain

Key words: Chinchilla. Epithelium. Lipocalin allergen.

Palabras clave: Chinchilla. Epitelio. Alérgeno de lipocalina.

Animal allergens are a common cause of both acute and chronic allergic disease. Pelt, urine, and saliva from some mammals are well-known sources of allergens. Chinchilla (*Chinchilla lanigera*, order Rodentia, family Chinchillidae) is used in the fur industry and in certain laboratory experiments; therefore, it is considered an occupational source of aeroallergens [1]. However, keeping this animal as a pet could make it a potential source of allergens in the general population.

We present the case of a 43-year-old woman who experienced contact urticaria, rhinoconjunctivitis, and persistent asthma as a result of exposure to her pet chinchilla. She complained of symptoms when in the presence of the animal, although the symptoms disappeared during her vacation, when she was not exposed.

The patient underwent a skin prick test with common aeroallergens and a battery of animal epithelium extracts (cat,

dog, rat, mouse, rabbit, guinea pig, hamster, gerbil, horse, and cow). The result was negative for all extracts except chinchilla pelt, which produced a wheal measuring 6×6 mm.

Peak flow monitoring values were 380–400 L/min during the 15 days of her vacation (no exposure). When an exposure challenge was performed at the owner's home after the vacation, these values fell to 280–300 L/min, and when she spent 15 minutes in the room where the animal was kept, her peak flow decreased to 100 L/min. She also experienced respiratory symptoms and contact urticaria.

Total immunoglobulin (Ig) E, determined using ImmunoCAP (Phadia AB, Uppsala, Sweden), was 79 kU_A/L. Specific IgE was determined using the enzyme allergosorbent test (EAST) inhibition procedure (HY-TEC assay, HYCOR, Garden Grove, California, USA). The solid phase was obtained by coupling the extract solution (1 mg/mL) to a 6-mm diameter cyanogen bromide paper-activated carrier and the EAST inhibition procedure (HYCOR) was performed in accordance with the manufacturer's instructions (Specific IgE was undetectable for hair extracts from cow, cat, dog, and squirrel, and for pelt and urine extracts from rat, mouse, guinea pig, hamster, gerbil, and rabbit [2]. Specific IgE to chinchilla urine and chinchilla pelt extracts were 7.3 kU_A/L (class 3) and 5 kU_A/L (class 3), respectively.

We prefractionated the whole chinchilla pelt extract by preparative isoelectric focusing and collected the proteins in the chamber at pH 4.6–5.4. These proteins were then separated by 2-dimensional electrophoresis using a strip at pH 4.7–5.9 in the first dimension. In the second dimension, the sodium dodecyl sulfate gel had a 4–12% polyacrylamide gradient. After immunodetection, we observed 2 spots, both weighing 21 kDa, (Figure), and we identified the same 2 proteins in both spots: 14-3-3 protein kinase C inhibitor-1 isoform and α 2-u-globulin L type, which is known as the major rat allergen Rat n 1 and belongs to the lipocalin superfamily.

Kelso et al [1] recently reported the allergenic character of hair and urine from chinchilla. The most widely reported mammal and rodent allergens are serum albumin and lipocalins, whose molecular masses range from 62 kDa to 69 kDa and 7 kDa to 23 kDa, respectively [2–4]. One of the possibly immunoreactive proteins detected here belongs to the lipocalin family.

In our case, as the skin prick test and EAST inhibition results showed, no cross-reactivity was found between chinchilla allergens and those from the other animal epithelia and urines




Figure. Two-dimensional electrophoresis map of chinchilla epithelium extract. We observed 2 spots (1 and 2, both weighing 21 kDa).

tested. Due to their pheromonal character and function, the expression of urine lipocalins in mice and rats is sex-dependent, and their amount in urine is about 6 times higher in males than females [5]. Therefore, urine from male rodents—the patient's chinchilla was male—could be considered a stronger potential allergen source than urine from female rodents.

We describe a case of nonoccupational allergy to chinchilla. Current knowledge on rodent allergens and the results of the present case lead us to believe that the allergen involved was chinchilla lipocalin.

References

1. Kelso JM, Jones RT, Yunginger JW. Allergy to chinchilla. *J Allergy Clin Immunol*. 2002;109:S342.
2. Walls AF, Newman Taylor AJ, Longbottom JL. Allergy to guinea pigs: I Allergenic activities of extracts derived from pelt, saliva, urine, and other sources. *Clin Allergy*. 1985;15:241-51.
3. Spitzauer S. Allergy to mammalian proteins: at the borderline between foreign and self? *Int Arch Allergy Immunol*. 1999;120:259-69.
4. Siraganian RP, Sandberg AL. Characterization of mouse allergens. *J Allergy Clin Immunol*. 1979;63:435-42.
5. Cavaggioni A, Mucignat-Caretta C. Major urinary proteins, α_2 -globulins and aphrodisin. *Biochim Biophys Acta*. 2000;1482:218-28.

■ Manuscript received August 19, 2008; accepted for publication March 25, 2009.

Beatriz Fernández-Parra
Hospital el Bierzo
Servicio de Alergología
C/Alcón, 33, 3ªA
24400 Ponferrada, Spain
E-mail: beaferpa@yahoo.es

Therapeutic Alternatives in a Patient With DRESS Syndrome Induced by Allopurinol

GF Calogiuri,¹ F Satriano,¹ L Muratore,² A Valacca,³
E Nettis,⁴ E Di Leo,⁴ A Vacca⁴

¹Fourth Pneumology Department, Pneumologic Hospital A. Galateo, San Cesario di Lecce, Italy

²Allergy and Clinical Immunology Service, Vito Fazzi Hospital, Lecce, Italy

³Department of Hematology and Internal Medicine, Vito Fazzi Hospital, Lecce, Italy

⁴Section of Allergology and Clinical Immunology, Department of Internal Medicine and Infectious Diseases, University of Bari, Bari, Italy

Key words: Allopurinol. DRESS syndrome. Potassium-sodium-hydrogen citrate. Patch test.

Palabras clave: Alopurinol. Síndrome DRESS. Citrato de potasio-sodio-hidrógeno. Prueba epicutánea.

Allopurinol hypersensitivity syndrome (AHS) is characterized by rash, impaired renal function, and acute hepatic toxicity (major criteria) in association with fever, leukocytosis, and eosinophilia (minor criteria) [1]. Patients taking diuretics for chronic renal failure present a high risk of drug rash with eosinophilia and systemic symptoms (DRESS) syndrome after taking allopurinol [1]. Taking allopurinol irregularly seems to be a risk factor [1].

A 70-year-old man with gout, hypertension, obesity, diabetes mellitus, chronic obstructive pulmonary disease, and chronic renal failure (stage 1) developed a DRESS syndrome after taking oral allopurinol (300 mg). He had previously taken allopurinol for 1 month to treat symptomatic hyperuricemia. When the drug was reintroduced, it induced a widespread erythematous itching rash, asthenia, dyspnea, facial angioedema, and fever (38.5°C-39°C) 12 hours after the third tablet was taken. The patient was admitted to hospital. His clinical history revealed previous hypersensitivity reactions to aspirin and pyrazolone. When the adverse reaction occurred, he was also taking glibenclamide, digoxin, losartan, furosemide, and formoterol/budesonide. All drugs were stopped during hospitalization (Table).

The laboratory workup revealed kidney failure, severe dyspnea, and mild mixed acidosis. He was treated with oxygen therapy, corticosteroids, antihistamines, 5% glucose solution, insulin, and inhaled salmeterol.

Blood pressure, blood glucose level, and renal function were closely monitored. The results of serology testing for viruses and bacteria were negative. The results of a dermatology workup enabled us to make a diagnosis of DRESS syndrome induced by allopurinol, but the patient refused to undergo a skin biopsy. He was discharged and prescribed the drugs he was taking before hospitalization (except allopurinol) and a hyperuricemia-specific diet. The patient did not adhere to the diet and developed hyperuricemia (11.5 mg/dL) 1 month later. Sulfinpyrazone was avoided due to

Table. Laboratory Findings

	Patient's Values	Reference Range
Leukocytes	12 200/mm ³	4000-10 000/mm ³
Eosinophils	1260/mm ³	≤350/mm ³
Blood glucose	190 mg/dL	55-110 mg/dL
Plasma urea	108 mg/dL	10-50 mg/dL
Serum creatinine	2.6 mg/dL	0.6-1.4 mg/dL
Uricemia	13.2 mg/dL	≤7.5 mg/dL
AST	76 IU/L	20-45 IU/L
ALT	63 IU/L	25-40 IU/L
Pco ₂	50 mm Hg	35-45 mm Hg
Po ₂	56 mm Hg	80-90 mm Hg
Blood pH	7.36	7.37-7.43
Total serum IgE	265 kU _A /L	≤120 kU _A /L
ESR	42 mm at 1 hour	≤15 mm at 1 hour

Abbreviations: ALT, alanine aminotransferase; AST, aspartate aminotransferase; Ig, immunoglobulin; ESR, erythrocyte sedimentation rate.

the patient's hypersensitivity to nonsteroidal anti-inflammatory drugs. Desensitization was not performed because of the previous severe adverse cutaneous reaction. The patient refused colchicine because he feared experiencing adverse events. Since cutaneous lesions were still present 45 days after the acute episode, no skin tests were performed [2]. A rapid single-dose oral challenge test with potassium-sodium-hydrogen citrate (Rottapharm-Madaus, srl, Padova, Italy) was performed as described elsewhere [3]. The patient tolerated this drug well, and was prescribed a 10-day regimen (200 mg bid) to reduce his uricemia (7.2 mg/dL).

Two months later, when the skin lesions had faded completely, he underwent a patch test with allopurinol 10% and 5% in petrolatum [2] according to the guidelines of the European Academy of Allergology and Clinical Immunology [4]. The results at 48, 72, and 96 hours, and a scratch-patch test gave doubtful results after 24 hours. The patient again refused to undergo a skin biopsy.

Positive skin test results to allopurinol are infrequent. Emmerson et al [5] studied a group of 9 patients with AHS: only 2 showed positive responses to intradermal tests at 0.1 µg/mL of allopurinol and oxypurinol in glycerol. There are no reports of positive patch test results with allopurinol in the literature [2].

Recently, rasburicase (produced by genetic engineering of *Aspergillus flavus* uricase) has been proposed as an alternative in patients with gout [6]. It could also prove useful in patients with gout and AHS, although its disadvantages include parenteral administration, risk of anaphylactic reaction, high cost, and absence of validated treatment schedules. These limitations and the patient's poor adherence history prevented us from prescribing rasburicase to our patient.

In patients with AHS, we recommend a short course of potassium-sodium-hydrogen citrate while awaiting approval for the new safer molecules (febuxostat) that are now available in the USA [7].

References

1. Arellano F, Sancristan JA. The allopurinol hypersensitivity syndrome: a review. *Ann Pharmacother.* 1993;27:337-43.
2. Pérez A, Cabrerizo S, de Barrio M, Diaz MP, Herrero T, Tornero P, Baeza ML. Erythema multiform-like from amoxicillin and allopurinol. *Contact Dermatitis.* 2001;44:113-4.
3. Passalacqua G, Milanese M, Mincarini M, Ciprandi G, Guerra L, Scordamaglia A, Canonica GW. Single-dose oral tolerance test with alternative compounds for the management of adverse reactions to drugs. *Int Arch Allergy Immunol.* 2002;129:43-7.
4. Brockow K, Romano A, Blanca M, Pichler WJ, Demoly P. General considerations for skin tests procedures in the diagnosis of drug hypersensitivity. *Allergy.* 2002;56:45-51.
5. Emmerson BT, Hazelton RA, Frazer H. Some adverse reactions to allopurinol may be mediated by lymphocyte reactivity to oxypurinol. *Arthritis Rheum.* 1988;31:436-40.
6. Vogt B. Urate oxidase (rasburicase) for treatment of severe tophaceous gout. *Nephrol Dial Transplant.* 2005;20:431-3.
7. Becker MA, Schumacher R Jr, Wortmann RL, McDonald PA, Eustace D, Palo AW, Streit J, Joseph-Ridge N. Febuxostat

compared with allopurinol in patients with hyperuricemia and gout. *N Engl J Med.* 2005;353:2450-61.

■ Manuscript received September 25, 2008; accepted for publication March 27, 2009.

Eustachio Nettis, MD

Cattedra di Allergologia ed Immunologia
Clinica
Università degli Studi di Bari
Policlinico, Piazza Giulio Cesare, 11
70124 Bari, Italy
E-mail: e.nettis@allergy.uniba.it

Dimenhydrinate-Induced Fixed Drug Eruption in a Patient Who Tolerated Other Antihistamines

B Rodríguez-Jiménez, J Domínguez-Ortega, JM González-García, C Kindelan-Recarte
Allergy Unit, Hospital Universitario de Getafe, Madrid, Spain

Key words: Antihistamine allergy. Dimenhydrinate. Fixed drug eruption. Patch test.

Palabras clave: Alergia a antihistaminicos. Dimenhidrinato. Exantema fijo medicamentoso. Pruebas epicutáneas.

Dimenhydrinate is an H₁ antihistamine of the ethanolamine group with important anticholinergic, antiserotonergic, and sedative properties. Ethanolamine compounds have been used to treat dizziness, nausea, vomiting, anxiety, and cold symptoms. Diphenhydramine, from which dimenhydrinate, doxylamine, carbinoxamine, and clemastine derive, also belongs to this group.

We present the case of a 17-year-old woman who presented several times during a 1-year period with 2 round erythematous macules on the abdomen and right gluteus after taking combined dimenhydrinate and acetaminophen for dysmenorrhea. The lesions disappeared after 6-7 days, leaving a hyperpigmented residual lesion. The patient later tolerated acetaminophen.

Patch testing was performed with dimenhydrinate and acetaminophen and dimenhydrinate 10% in petroleum jelly on the affected areas and on areas of healthy skin. Readings were taken at 48 and 96 hours. The results were positive for dimenhydrinate on the right gluteus (Figure) and for the combination on the abdomen at 48 and 96 hours. The results of patch testing on 10 controls with dimenhydrinate at the same concentration were negative. The results of patch testing with antihistamines from other groups—cetirizine, rupatadine, and dexchlorpheniramine—were negative.

Given the patient's history and the patch test results to dimenhydrinate, an oral challenge with this drug was considered unnecessary.

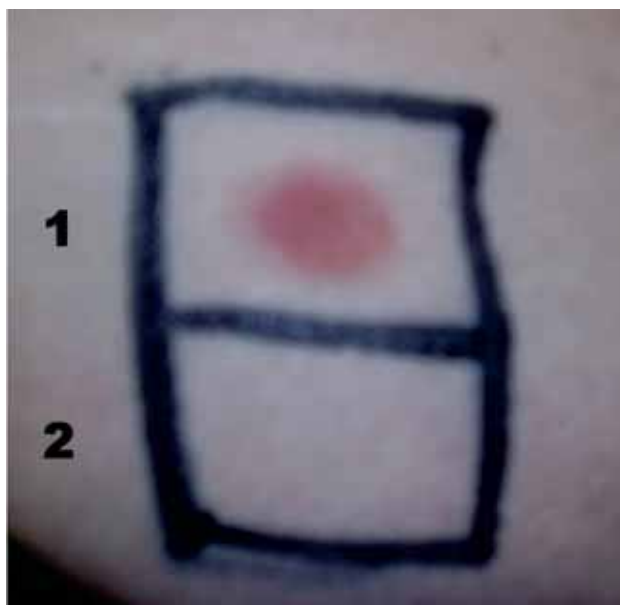


Figure. Patch test on previously affected skin (right gluteus): 1. Dimenhydrinate, 2. Negative control.

Controlled oral exposure to cetirizine, rupatadine, and dexchlorpheniramine was well tolerated. The patient also applied treatment at home with each of these medications for 5 days with no skin reaction. Fixed drug eruption (FDE) is a rash characterized by one or more well-delimited erythematous lesions that appear shortly after ingesting the causal agent and typically recur in the same location when the agent is reintroduced. A hyperpigmented area sometimes remains after the symptoms have subsided. Sulphonamides, nonsteroidal anti-inflammatory drugs, β -lactam antibiotics, barbiturates, and tetracyclines are the most common causal agents [1]. With respect to antihistamines, cases of FDE due to loratadine [2], cetirizine [3], hydroxyzine [3], levocetirizine [4], and diphenhydramine [5] have been reported. There are few known cases of dimenhydrinate-induced FDE [6-8], and none in which tolerance of other antihistamines was confirmed by oral challenge.

Our patient had a positive reaction when the medication was tested on previously affected skin. This supports the idea that patch testing should be performed on areas of residual lesions in FDE, thus obviating oral challenge tests, which are not exempt from risks. Our patient tolerated antihistamines from other groups (cetirizine, rupatadine, and dexchlorpheniramine), indicating that there was no cross-reactivity with the antihistamines tested.

Acknowledgments

No external funding was required for the present study.

References

1. Mahboob A, Haroon TS. Drugs causing fixed eruptions: a study of 450 cases. *Int J Dermatol*. 1998;37:833-8.

2. Pionetti CH, Kien MC, Alonso A. Fixed drug eruption due to loratadine. *Allergol Immunopathol*. 2003;31:291-3.
3. Assouère MN, Mazereeuw-Hautier J, Bonafé JL. Cutaneous drug eruption with two antihistaminic drugs of a same chemical family: cetirizine and hydroxyzine. *Ann Dermatol Venereol*. 2002;129:1295-8.
4. Gupta SD, Prabhakar SM, Sacchidanand S. Fixed drug eruption due to levocetirizine. *Indian J Dermatol Venereol Leprol*. 2005;71:361-2.
5. Dwyer CM, Dick D. Fixed drug eruption caused by diphenhydramine. *J Am Acad Dermatol*. 1993;29:496-7.
6. Saenz de San Pedro B, Quiralte J, Florido JF. Fixed drug eruption caused by dimenhydrinate. *Allergy*. 2000;55:297.
7. Smola H, Kruppa A, Hunzelmann N, Krieg T, Scharffetter-Kochanek K. Identification of dimenhydrinate as the causative agent in fixed drug eruption using patch-testing in previously affected skin. *Br J Dermatol*. 1998;138:920-1.
8. Gonzalo-Garijo MA, Revenga-Arranz F. Fixed drug eruption due to dimenhydrinate. *Br J Dermatol*. 1996;135:661-2.

Manuscript received October 30, 2008; accepted for publication March 27, 2009.

Beatriz Rodríguez Jiménez

Allergy Unit

Hospital Universitario de Getafe

Carretera de Toledo, Km 12,500

28905 Getafe (Madrid), Spain

E-mail: alergologia.hugf@salud.madrid.org

Presence of Hypogammaglobulinemia in a Patient With Fanconi Anemia: A Case Report

UN Sarwar,¹ R Hamadeh²

¹Department of Internal Medicine, NYU School of Medicine, New York, USA

²Department of Infectious Diseases and Immunology, NYU School of Medicine, New York, USA

Key words: Fanconi anemia. Immunodeficiency. Hypogammaglobulinemia.

Palabras clave: Anemia de Fanconi. Inmunodeficiencia. Hipogammaglobulinemia.

Fanconi anemia is an autosomal recessive disease characterized by cellular hypersensitivity to DNA cross-linking agents and progressive bone marrow failure. Patients with this condition often present with recurrent infections resulting from immunodeficiencies. Immunologic abnormalities that have been described in patients with Fanconi anemia include reduced natural killer cell activity [1,2], low levels of production of interleukin 6 [3], and high plasma levels of tumor necrosis factor alpha- α [1,4]. In addition, selective immunoglobulin (Ig) A deficiency has been described in a case report [5]. In our review of the literature, we came across only 1 study that addressed humoral immunity in patients with Fanconi anemia, and there have been no reports of accompanying hypogammaglobulinemia. We discuss a patient with Fanconi anemia and hypogammaglobulinemia.

A 35-year-old male with Fanconi anemia and squamous cell carcinoma of the larynx complicated by multiple neck dissections presented with fever and chest pain. He was diagnosed with bacterial pericarditis caused by methicillin-susceptible *Staphylococcus aureus* and subsequently developed bilateral pneumonia. Upon admission his leukocyte count was $6.2 \times 10^9/L$ and his hematocrit 32%. His course was complicated by constrictive pericarditis and he underwent emergency pericardiectomy. He subsequently developed ventilator-associated pneumonia and a surgical wound infection at the site of his chest incision leading to bacteremia. Given these recurrent infections in the absence of neutropenia, Ig levels were determined, and he was found to have low titers in all Ig groups (Table). He received replacement intravenous immunoglobulin and responded well. Two months later he was readmitted with cellulitis and neutropenia. Despite appropriate antimicrobial therapy and concomitant granulocyte colony-stimulating factor therapy, his fever did not remit. He was treated with intravenous immune serum globulin after his titers were again found to be low (Table), and his fever subsequently fell. He underwent surgery for recurrent left neck carcinoma and had an unremarkable postoperative course.

Recurrent infections in patients with Fanconi anemia have been attributed to the presence of pancytopenia, particularly neutropenia. Immunologic abnormalities described elsewhere point towards a defect in cell-mediated immunity. Humoral immunity has been evaluated by determination of Ig levels in a small number of cases and was reported to be normal [3,6,7].

Our patient was initially diagnosed with Fanconi anemia at age 21. He later developed squamous cell carcinoma of the neck and underwent several surgical interventions. He reported postoperative complications in the past, although his hematological data and medical records from that time were unavailable to us. He initially presented at our hospital with pericarditis, and despite being on appropriate antimicrobial therapy, he developed several repeated infections over a short period, leading us to investigate further the risk factors for infection.

Our rationale in determining Ig levels was based on a study by Roxo et al [3], who recorded serum Ig levels in 12 patients with Fanconi anemia and their response to vaccination. The Ig levels measured were normal except for subclass IgG4, which was undetectable in 2 out of 12 patients.

It could be argued that our patient's recurring infections during his second hospitalization could in fact be from the

concomitant presence of neutropenia. However, he was not neutropenic during his first admission. The etiology of his hypogammaglobulinemia is unclear and its development over time could not be determined. However, he had a strong clinical response after administration of intravenous Ig. To conclude, we describe a case of hypogammaglobulinemia as a possible cause of immunodeficiency in Fanconi anemia. Future studies should examine the role of humoral immunity in patients with this condition.

References

1. Fagerlie S, Bagby, Grover C. Immune defects in Fanconi anemia. *Crit Rev Immunol*. 2006;26(1):81-96.
2. Froom P, Aghai E, Dombinsky J, Quitt M, Lahat N. Reduced natural killer activity in patients with Fanconi's anemia and in family members. *Leuk Res*. 1987;11:197-9.
3. Roxo P, Arruda L, Nagao A, Carneiro-Sampaio M, Ferriani V. Allergic and immunologic Parameters in patients with Fanconi's Anemia. *Int Arch Allergy Immunol*. 2001;125:349-55.
4. Rosselli F, Sanceau J, Wietzerbin J, Moustacchi E. Abnormal lymphokine production: A novel feature of the genetic disease Fanconi anemia. In vitro and in vivo spontaneous overproduction of tumor necrosis factor alpha. *Blood*. 1994;83:1216-25.
5. Standen G, Hughes I, Geddes A, Jones BM, Wardrop C. Myelodysplastic syndrome with trisomy 8 in an adolescent with Fanconi anaemia and selective IgA deficiency. *Am J Hematol*. 1989;31:280-3.
6. Hersey P, Edwards A, Lewis R, Kemp A, McInnes J. Deficient natural killer cell activity in a patient with Fanconi's anaemia and squamous cell carcinoma. Association with defect in interferon release. *Clin Exp Immunology*. 1982;48:205-12.
7. Petridou M, Barrett AJ. Physical and laboratory characteristics of heterozygote carriers of the Fanconi aplasia gene. *Acta Paediatr Scand*. 1990;79:1069-74.
8. Rosselli F, Sanceau J, Wietzerbin J, Moustacchi E. Abnormal lymphokine production: a novel feature of the genetic disease Fanconi anemia. I. Involvement of interleukin-6. *Hum Genet*. 1992;89:42-8.
9. Schultz J, Shahidi NT. Tumor necrosis factor-alpha overproduction in Fanconi's anemia. *Am J Hematol*. 1993;42:196-201.
10. Pederson FK, Hertz H, Lundsteen C, Platz P, Thomsen M. Indication of primary immune deficiency in Fanconi's anemia. *Acta Paediatr Scand*. 1977;66:745-51.

■ Manuscript received December 10, 2008; accepted for publication March 28, 2009.

Uzma Nikhat Sarwar

401 East 34th street, Apartment # N9M

New York, NY 10016

Email: sarwau01@nyumc.org,

zigma9@hotmail.com

Table. Immunoglobulin Levels

Immunoglobulin		Patient Levels in mg/dL	Reference Range in mg/dL
Immunoglobulin levels during hospitalization 1	IgG	224	650-1750
	IgM	18	37-250
Immunoglobulin levels during hospitalization 2	IgG	488	650-1750
	IgM	19	37-250
	IgA	83	60-240

A Case of Food-Dependent Exercise-Induced Anaphylaxis Due to Ingestion of Peach

S Sato,^{1,2} R Nagao,² T Hujioaka,² K Suzuki,² K Tsuyuki,² A Hoshika¹

¹Department of Pediatrics, Tokyo Medical University, Tokyo, Japan

²Division of Pediatrics, Tokyo Medical University Hachioji Medical Center, Tokyo, Japan

Key words: FDEIA. Allergy. Peach. Anaphylaxis. Fruit.

Palabras clave: AIEDA. Alergia. Melocotón. Anafilaxia. Fruta.

Food-dependent exercise-induced anaphylaxis (FDEIA) is characterized by anaphylactic symptoms after exercise preceded by ingestion of a food allergen. It was first described in 1979 in a patient who experienced exercise-induced anaphylaxis after eating shellfish [1]. FDEIA has been associated with wheat, seafood, peanut, eggs, milk, vegetables, and fruit [2]. We present a case of FDEIA induced by peach.

An 11-year-old boy experienced anaphylactic symptoms (dyspnea, pruritus, diffuse erythematous rash) after eating curry, yogurt, cabbage, onion, carrot, potato, green peas, rice, and peach for lunch. He ate the peach approximately 2 hours before playing football. Two months previously, he had experienced similar symptoms closely related to exercise 2.5 hours after eating peach, but exercise alone had never generated a reaction. He had a history of allergic rhinitis, but no food allergy. His father also had a history of allergic rhinitis. On admission, 3 months after the initial anaphylaxis, physical examination revealed no significant findings. He did not have eosinophilia, but he did have high serum immunoglobulin (Ig) E (1070 U/mL) titers and peach-specific IgE was 8.08 kU_A/mL. Latex-specific IgE testing was negative. Open-labeled oral challenge tests, which were performed using 50 g (wet weight) of peach, failed to induce any allergic reactions. He showed no symptoms after ingestion of the peach, and a 20-minute treadmill test using the standard Bruce protocol was performed 60 minutes after food intake. Blood pressure and pulse rate were monitored during the challenge test. Ingestion of this food, followed by exercise, led to mild pruritus and small urticaria on the left arm. Forced expiratory volume in 1 second and forced vital capacity were measured before and after exercise, and there was no change in his lung function after exercise. Therefore, ingestion of peach followed by exercise did not induce anaphylaxis. We administered 500 mg of oral aspirin followed by peach 30 minutes later and a treadmill test 6 minutes after peach intake [3]. Aspirin and peach induced anaphylactic reactions (dyspnea, pruritus, diffuse erythematous rash). We treated the patient with an intramuscular injection of epinephrine antihistamine and corticosteroids. Five hours after ingestion, he had completely recovered. However, aspirin loading did not induce an allergic reaction. The patient was advised to avoid peach and has experienced no further reactions. We prescribed self-injectable epinephrine.

Aspirin is a known trigger of anaphylaxis in patients who experience FDEIA. Harada et al [3] first confirmed the

effects of aspirin on the induction of food anaphylaxis, even in patients with FDEIA who had no previous history of aspirin hypersensitivity caused by nonsteroidal anti-inflammatory drugs. This observation suggests 2 possible mechanisms in the elicitation of symptoms: aspirin could upregulate antigen uptake across the intestinal epithelium and into the bloodstream, and/or aspirin itself could activate mast cells in combination with IgE cross-linking through an unknown mechanism [4].

Shellfish is the most common allergen in the United States [5]. The most common specific food allergen in FDEIA is wheat [1], and, in particular, ω-5 gliadin. However, there have been few reports of this condition after peach ingestion in childhood [6]. The cause of FDEIA is not well understood, although cross-reactivity exists between pollen and Rosaceae fruit allergens that cause oral allergy syndrome. Thus, further studies are needed to establish the clinical significance of the observed cross-reactivity between aeroallergens and FDEIA. Our results confirm that peach can induce FDEIA.

References

1. Maulitz RM, Pratt DS, Schocket AL. Exercise-induced anaphylactic reaction to shellfish. *J Allergy Clin Immunol*. 1979;6:433-4.
2. Du Toit G. Food-dependent exercise-induced anaphylaxis in childhood. *Pediatr Allergy Immunol*. 2007;18:455-63.
3. Harada S, Horikawa T, Ashida M, Kamo T, Nishioka E, Ichihashi M. Aspirin enhances the induction of type I allergic symptoms when combined with food and exercise in patients with food-dependent exercise-induced anaphylaxis. *Br J Dermatol*. 2001;145:336-9.
4. Matsuo H, Morimoto K, Akaki T, Kaneko S, Kusatake K, Kuroda T, Niihara H, Hide M, Morita E. Exercise and aspirin increase levels of circulating gliadin peptides in patients with wheat-dependent exercise-induced anaphylaxis. *Clin Exp Allergy*. 2005;35:461-6.
5. Shadick NA, Liang MH, Partridge AJ, Bingham C, Wright E, Fossel AH, Sheffer AL. The natural history of exercise-induced anaphylaxis: survey results from a 10-year follow-up study. *J Allergy Clin Immunol*. 1999;104:123-7.
6. Romano A, Di Fonso M, Giuffreda F, Papa G, Artesani MC, Viola M, Venuti A, Palmieri V, Zeppilli P. Food-Dependent Exercise-Induced Anaphylaxis: Clinical and Laboratory Findings in 54 Subjects. *Int Arch Allergy Immunol*. 2001;125:264-72.

■ Manuscript received October 1, 2008; accepted for publication March 31, 2009.

Satoshi Sato

Department of Pediatrics
Tokyo Medical University
6-7-1 Nishishinjuku, Shinjuku-ku
Tokyo 160-0023, Japan
E-mail: sato115@tokyo-med.ac.jp

Eosinophilic Esophagitis Due To Profilin Allergy

J Domínguez-Ortega,¹ J Pérez-Bedmar,² B Rodríguez-Jiménez,¹ M Butrón,³ C Kindelan,¹ A Ledesma⁴

¹Allergology Unit, Hospital Universitario de Getafe, Madrid, Spain

²Digestive Medicine Department, Hospital Universitario de Getafe, Madrid, Spain

³Pathology Department, Hospital Universitario de Getafe, Madrid, Spain

⁴ALK-Abelló, Madrid, Spain

Key words: Profilin. Eosinophilic esophagitis. Fruit allergy.

Palabras clave: Profilina. Esofagitis eosinofílica. Alergia a frutas.

Eosinophilic esophagitis (EE) is characterized by the presence of a biopsy-proven inflammatory eosinophilic infiltrate in the esophageal mucosa [1]. Its presentation is similar to that of gastroesophageal reflux disease, and it responds poorly to antireflux treatment. In children, the commonest symptoms are abdominal pain and vomiting, whereas adults experience dysphagia and food impaction [2]. Over 60% of patients have a history of atopy, and sensitization to foods or aeroallergens is common, with clinical improvement after switching to an elementary or exclusion diet [3].

A 32-year-old man presented with a 10-year history of mild seasonal rhinoconjunctivitis for which he took only antihistamines as needed. He had never received immunotherapy. For the last 2 years, he had experienced oral pruritus after eating fresh, raw fruit and vegetables. However, as the pruritus was mild, he did not stop eating these foods. He tolerated cooked vegetables, jams, and pasteurized fruit juices. Furthermore, in the last year, he suffered dysphagia with solids. Omeprazole made no improvement to his symptoms, and gastroesophageal reflux disease was ruled out by pH monitoring.

Skin prick tests were performed with commercial standardized extracts of pollen, mites, danders, moulds, latex, *Anisakis simplex*, profilin, and standardized Pru p 3 peach extract (ALK-Abelló, Madrid, Spain), shellfish, molluscs, cephalopods, fruit, vegetables, fish, cereal flours, nuts, milk, egg, lentils, soya, and spices (Leti, Barcelona, Spain). The patient presented positive results for the following allergens (wheat size): grass pollen (10 mm), olive (4 mm), cat dander (4 mm), tomato (5 mm), melon (7 mm), orange (3 mm), and profilin (12 mm). Total immunoglobulin (Ig) E was 78 kU_A/L. Specific IgE was <0.35 kU_A/L in Ole e 1 and elevated for tomato (2.53 kU_A/L), grass pollen (6.44 kU_A/L) and profilin in *Phleum pratense* (5.96 kU_A/L) (CAP System, Phadia, Uppsala, Sweden), Mal d 4 (2.96 kU_A/L), Pho d 2 (9.59 kU_A/L), and Cuc m 2 (2.20 kU_A/L) (ADVIA-Centaur, Bayer HealthCare Diagnostics Division, Tarrytown, New York, USA). A complete blood count (January 2008) showed 490 eosinophils/ μ L, although the serum determination for eosinophil cationic protein (ECP) (CAP System) was clearly elevated (88.6 μ g/L). The results for the remaining biochemistry parameters and the complement and immunoglobulin studies were normal. Gastroendoscopy

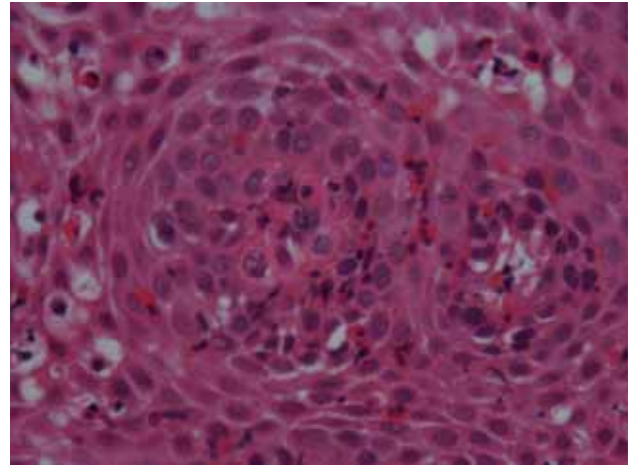


Figure. Highly magnified photomicrograph showing the esophageal epithelium infiltrated by a large number of polymorphonuclear eosinophils (more than 20 per high power field). Hematoxylin-eosin \times 400.

showed a morphologically normal esophageal mucosa with a nonstenotic mucous ring in the transition zone. Biopsy revealed a clear predominantly eosinophilic infiltrate (Figure).

Fruit and vegetables were only permitted if cooked. Four months later, the patient was asymptomatic and ECP serum levels had fallen to 40.1 μ g/L.

Although its origin is unknown, EE is an increasingly common entity in which food and aeroallergens appear to play a role [4]. This patient had already presented mild allergic rhinitis. This prior sensitization to grass pollen may explain the subsequent sensitization to profilins, as structural plant proteins show a large degree of homology and cross-reactivity, thus enabling them to act as panallergens [5]. Profilins cannot resist the action of gastric proteases, but are barely affected by saliva, which is why the patient only presented oral and esophageal symptoms, and no gastric or systemic involvement. Furthermore, profilins are heat-labile, hence the good response to cooked vegetables. Remission of the inflammatory infiltrate should have been confirmed by endoscopy; however, the patient rejected this option because he was feeling clinically well. The notable decrease in serum ECP [6], together with the disappearance of clinical symptoms, indicates that by simply strictly avoiding the allergen, as is the case in other allergic diseases, the clinical symptoms will disappear. Inhaled fluticasone could have accelerated the improvement, but it was considered unnecessary once the positive results of a change in diet had been observed.

In conclusion, this case of EE was probably associated with sensitization to profilin, although strict exclusion of foods containing the protein led to remission of symptoms. We believe that a meticulous allergy workup is fundamental to identify potential allergens in this condition.

References

1. Brown-Whitehorn T, Liacouras CA. Eosinophilic esophagitis. *Curr Opin Pediatr.* 2007;19:575-80.

2. Spergel JM. Eosinophilic esophagitis in adults and children: evidence for a food allergy component in many patients. *Curr Opin Allergy Clin Immunol.* 2007;7:274-8.
3. Spergel JM, Beausoleil JL, Mascarenhas M, Liacouras CA. The use of skin prick tests and patch tests to identify causative foods in eosinophilic esophagitis. *J Allergy Clin Immunol.* 2002;109:363-8.
4. Fogg MI, Ruchelli E, Spergel JM. Pollen and eosinophilic esophagitis. *J Allergy Clin Immunol.* 2003;112:796-7.
5. López-Torrejón G, Díaz-Perales A, Rodríguez J, Sánchez-Monge R, Crespo JF, Salcedo G, Palacios LF. An experimental and modelling-based approach to locate IgE epitopes of plant profiling allergens. *J Allergy Clin Immunol.* 2007;119:1481-8.
6. Venge P, Bystrom J, Carlson M, Hakansson L, Karawacjzyk M, Peterson C, Seveus L, Trulsson A. Eosinophil cationic protein

(ECP): molecular and biological properties and the use of ECP as a marker of eosinophil activation in disease. *Clin Exp Allergy.* 1999;29:1172-86.

■ Manuscript received December 3, 2008; accepted for publication April 8, 2009

Javier Domínguez Ortega

Unidad de Alergología
Hospital Universitario de Getafe
Carretera de Toledo, Km 12,500
28905 Getafe (Madrid)
Spain
E-mail: alergologia.hugf@salud.madrid.org

ERRATUM

Epidemiology of Allergic Rhinitis in Allergy Consultations in Spain: *Alergológica-2005*.

A Navarro, C Colas, E Anton, J Conde, I Dávila, MT Dordal, B Fernández-Parra, MD Ibáñez, M Lluch-Benal, V Matheu, J Montoro, C Rondon, MC Sánchez, A Valero [Rhinoconjunctivitis Committee of the SEAIC].

J Investig Allergol Clin Immunol 2009; Vol. 19, suppl. 2: 7-13.

The following are corrections for typographical errors that occurred in the article above.

Table 1

Diagnostic Test	2005	1992
Skin prick test	100	100
Diagnostic Test	2005	1992
Skin prick test	96	98

Treatment

– Immunotherapy was prescribed in 38% of patients with RA should read

– Immunotherapy was prescribed in 31% of patients with RA

Discussion

– Specific immunotherapy, ... was indicated in 38% of patients with AR. This figure is much lower than that from *Alergológica-92* where it was prescribed in 58%... should read

– Specific immunotherapy,... was indicated in 31% of patients with AR. This figure is much lower than that from *Alergológica-92* where it was prescribed in 45%...

Table 2.

Treatment	2005	1992
Nasal steroids	68	58
Specific immunotherapy	31	58
should read		
Treatment	2005	1992
Nasalsteroids	67	58
Specific immunotherapy	31	45