

Codeine-Induced Generalized Dermatitis and Tolerance to Other Opioids

P Iriarte Sotés,¹ R López Abad,¹ MT Gracia Bara,¹ M Castro Murga,¹ P Sesma Sánchez²

¹Allergy Unit, Hospital Arquitecto Marcide, Ferrol, Spain

²Internal Medicine, Hospital Arquitecto Marcide, Ferrol, Spain

Key words: Codeine. Cross-reactivity. Dermatitis. Opioids. Patch test.

Palabras clave: Codeína. Reactividad cruzada. Dermatitis. Opiáceos. Pruebas epicutáneas.

Codeine (methyl morphine) is a widely used opioid that is administered alone or in combination with other drugs, such as antihistamines, decongestants, and mild analgesics. There are few reports of generalized dermatitis induced by oral codeine and cross-reactivity with morphine [1-4].

A 43-year-old man experienced 3 episodes of generalized pruriginous rash after taking analgesic and antitussive preparations containing codeine. The rash developed several hours after taking Algidol (paracetamol 650 mg and codeine 10 mg), Bisolvon compositum (bromhexine, diphenhydramine, ephedrine, and codeine), and Fludeten (paracetamol and codeine 30 mg). The rash improved and disappeared by desquamation 2 to 3 weeks after beginning treatment with oral corticosteroids and antihistamines.

The patient subsequently tolerated Frenadol (paracetamol 650 mg, dextromethorphan, and chlorpheniramine) with no adverse effects. He also received fentanyl as an anesthetic with no further complications.

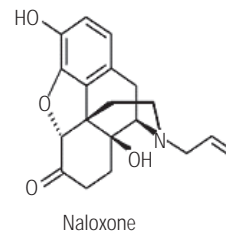
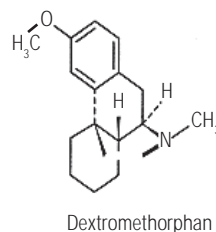
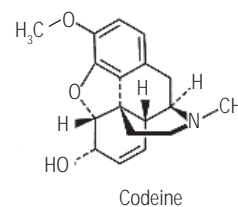
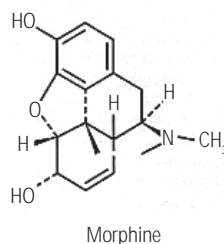
Patch tests were performed with opioids: codeine and morphine (0.1%-1% aq), tramadol (0.1%-1% aq and pet), meperidine (0.5%-5% pet), and naloxone (0.4 mg/mL aq). These were read after day (D) 2 and D4, and reactions were scored as recommended by the International Contact Dermatitis Research Group. Skin prick testing was performed with dilutions of commercial solutions of meperidine (5 mg/mL), tramadol (1 mg/mL), and undiluted naloxone (0.4 mg/mL), and intradermal testing was performed with meperidine (0.0005 mg/mL), tramadol (0.1 mg/mL), and naloxone (0.004 mg/mL). An immediate reading was obtained after 20 minutes and late readings at D1, D2, and D4. Patch testing with codeine and morphine gave positive results at all concentrations, and negative results to the other drugs tested. The immediate and late readings for the prick and intradermal tests were negative.

We describe a case of generalized dermatitis caused

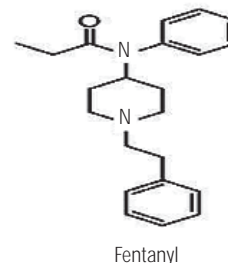
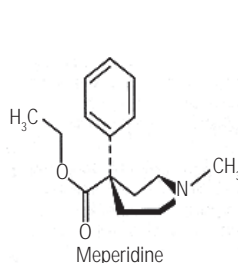
by codeine as a component of combination preparations. Positive patch test results and cross-reactivity with codeine and morphine have rarely been reported after systemic use of opium alkaloids [1-4].

On the basis of similarities in the chemical structures of phenanthrene derivatives, such as codeine and morphine, the safest approach is avoidance of all chemically related compounds in patients sensitized to any one of them (Figure). Dextromethorphan is the methylated dextrorotatory analog of levorphanol, which is a phenanthrene derivative. It is especially interesting to note that our patient was able to tolerate dextromethorphan (d-3-methoxymorphinan) following the reaction to codeine. The use of H₁ antihistamines could have attenuated the effects of nonspecific histamine release, but the association of chlorpheniramine with dextromethorphan

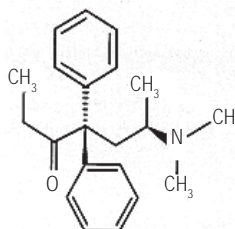
I. Phenanthrene Derivatives



II. Phenylpiperidine Derivatives



III. Diphenylheptane Derivatives



IV. Other

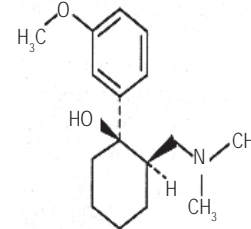


Figure. Structural classification of opioid analgesics.

does not prevent the triggering of a hypersensitivity reaction. In fact, both codeine and diphenhydramine were implicated in one of the episodes. Furthermore the good tolerance to fentanyl (phenylpiperidine) suggested that opioids that are structurally different to codeine and morphine congeners could be a safe alternative therapy [5].

In conclusion, we report a delayed-type hypersensitivity reaction to codeine with good tolerance to dextromethorphan and fentanyl. The reaction justifies performance of skin tests (patch, prick, and intradermal) with other opioids to identify those that are harmless for the patient.

References

- Rodríguez A, Barranco R, Latasa M, Ortiz de Urbina JJ, Estrada JL. Generalized dermatitis due to codeine. Cross-sensitization among opium alkaloids. *Contact Dermatitis*. 2005;53(4):240.
- Gastaminza G, Audicana M, Echenagusia MA, Uriel O, García-Gallardo MV, Velasco M, Fernández E, Muñoz D. Erythrodermia caused by allergy to codeine. *Contact Dermatitis*. 2005;52(4):227-8.
- Estrada JL, Alvarez Puebla MJ, Ortiz de Urbina JJ, Matilla B, Rodríguez Prieto MA, Gozalo F. Generalized eczema due to codeine. *Contact Dermatitis*. 2001;44(3):185.
- Rodríguez F, Fernández L, García-Abujeta JL, Maquieira E, Llaça H, Jerez J. Generalized dermatitis due to codeine. *Contact Dermatitis* 1995;32(2):120.
- Baumann TJ. Analgesic selection when the patient is allergic to codeine. *Clin Pharm*. 1991;10(9):658.

■ Manuscript received January 21, 2009; accepted for publication August 18, 2009.

Pilar Iriarte Sotés

Hospital Arquitecto Marcide
C/ San Pedro de Leixa, s/n
15404 Ferrol (A Coruña), Spain
E-mail: pilar.iriarte.sotes@sergas.es

Levocetirizine-Induced Iridocyclitis in a Patient With Allergic Rhinitis

GN Konstantinou,¹ M Ligerou,² MP Ligeros²

¹Department of Allergy and Clinical Immunology, 417 NIMTS Army Hospital, Athens, Greece

²Ophthalmology Department, 401 General Military Hospital of Athens, Greece

Key words: Allergic rhinitis. Case report. Iridocyclitis. Levocetirizine. Side effect.

Palabras clave: Rinitis alérgica. Caso clínico. Iridociclitis. Levocetirizina. Efecto secundario.

Second-generation oral H₁ antihistamines are recommended as first-line treatment of allergic rhinitis (AR) [1]. In mild AR, a single daily dose when symptoms appear is effective and has no major side effects. We describe a rare side effect attributed to levocetirizine in a patient with mild AR.

A 34-year-old man was admitted to the emergency department due to rapid-onset intense pain in his left eye accompanied by photophobia and blurred vision with halos around lights. The symptoms started in the morning, a few minutes after awakening. He denied any eye injury or any similar symptoms in the past. His medical history was unremarkable apart from a 5-year history of mild AR to house dust mites, with mild exacerbations during winter. The symptoms resolved with a single daily dose of 5 mg of levocetirizine, which he took for a few days before stopping. The last dose was taken the evening before onset of the presenting complaint. He denied having taken any other drugs.

Physical examination, complete blood count, and erythrocyte sedimentation rate were within the normal range. Ophthalmologic examination of the left eye revealed bulbar conjunctivitis and impaired visual acuity (8/10 vision). Slit lamp examination and fundoscopy revealed iridocyclitis. The left fundus oculi was normal with no signs of vasculitis. Eye movements and pupillary light reflexes were normal. The right eye was asymptomatic with no abnormal findings. No diplopia was reported.

The patient was treated with topical dexamethasone sodium phosphate (1 mg/mL, qid). Although there was no medical advice or indication to discontinue levocetirizine, the patient stopped on his own initiative.

The symptoms disappeared completely 4 days after treatment was started. Follow-up at 7 days revealed full recovery of visual acuity, with no signs of iridocyclitis or bulbar conjunctivitis. Consequently, topical dexamethasone was stopped.

Ten days later, the patient took another tablet of levocetirizine at 10 PM. The following morning, he experienced exactly the same symptoms. He was advised to restart treatment with dexamethasone sodium phosphate. However, as he had no access to the medication, application of cool compresses for symptomatic relief was recommended. On this occasion, levocetirizine was considered to have caused the symptoms and was discontinued. The symptoms followed exactly the same course and disappeared after 4 days. A week later, the results of the physical and ophthalmologic examination were normal.

The lack of an association between the symptoms and an underlying infectious or autoimmune disease, trauma, or administration of an irritant-toxic topical or systemic substance suggests that levocetirizine was the cause of iridocyclitis. Moreover, the reappearance of symptoms and the self-limiting spontaneous recovery after discontinuation reinforce the suggested association.

Naranjo et al [2] proposed 7 criteria to establish causality of adverse events by drugs. In our case, 4 of these 7 criteria were met (recovery upon withdrawal of the drug, exclusion of other causes, objectively documented event, and reoccurrence on rechallenge). There is no evidence that the reaction would become more severe if the dose was increased, or that similar signs or symptoms will occur with other antihistamines in the

future; therefore, a further two criteria are fulfilled. The criteria met in this case are equal or superior to the evidence of causality in uveitis with topical agents (eg, miotics), systemic agents (eg, diethylcarbamazine, contraceptives), and intracameral agents (eg, antibiotics, cidofovir) [3]. Therefore, it seems highly likely that iridocyclitis was induced by levocetirizine.

The duration of the symptoms was consistent with the pharmacodynamic effect of levocetirizine on the skin, irrespective of its plasma half-life [4]. However, an underlying pathogenic mechanism cannot be proposed or even speculated [3].

To our knowledge, this is the first report of iridocyclitis induced by an antihistamine. Since the last episode, the patient has taken desloratadine and rupatadine, with no reoccurrence of symptoms or side effects.

References

1. Bousquet J, Khaltaev N, Cruz AA, Denburg J, Fokkens WJ, Togias A, Zuberbier T, Baena-Cagnani CE, Canonica GW, van Weel C, Agache I, Ait-Khaled N, Bachert C, Blaiss MS, Bonini S, Boulet LP, Bousquet PJ, Camargos P, Carlsen KH, Chen Y, Custovic A, Dahl R, Demoly P, Douagui H, Durham SR, van Wijk RG, Kalayci O, Kaliner MA, Kim YY, Kowalski ML, Kuna P, Le LT, Lemiere C, Li J, Lockey RF, Mavale-Manuel S, Meltzer EO, Mohammad Y, Mullol J, Naclerio R, O' Hehir RE, Ohta K, Ouedraogo S, Palkonen S, Papadopoulos N, Passalacqua G, Pawankar R, Popov TA, Rabe KF, Rosado-Pinto J, Scadding GK, Simons FE, Toskala E, Valovirta E, van Cauwenberge P, Wang DY, Wickman M, Yawn BP, Yorgancıoğlu A, Yusuf OM, Zar H, Annesi-Maesano I, Bateman ED, Ben Kheder A, Boakye DA, Bouchard J, Burney P, Busse WW, Chan-Yeung M, Chavannes NH, Chuchalin A, Dolen WK, Emuzyte R, Grouse L, Humbert M, Jackson C, Johnston SL, Keith PK, Kemp JP, Klossek JM, Larenas-Linnemann D, Lipworth B, Malo JL, Marshall GD, Naspitz C, Nekam K, Niggemann B, Nizankowska-Mogilnicka E, Okamoto Y, Orru MP, Potter P, Price D, Stoloff SW, Vandenplas O, Viegi G, Williams D. Allergic Rhinitis and its Impact on Asthma (ARIA) 2008 update (in collaboration with the World Health Organization, GA(2)LEN and AllerGen). *Allergy*. 2008;63 Suppl 86:8-160.
2. Naranjo CA, Busto U, Sellers EM, Sandor P, Ruiz I, Roberts EA, Janecek E, Domecq C, Greenblatt DJ. A method for estimating the probability of adverse drug reactions. *Clin Pharmacol Ther*. 1981;30:239-45.
3. Moorthy RS, Valluri S, Jampol LM. Drug-induced uveitis. *Surv Ophthalmol*. 1998;42:557-70.
4. Simons FE, Simons KJ. Clinical pharmacology of H1-antihistamines. *Clin Allergy Immunol*. 2002;17:141-78.

■ Manuscript received June 26, 2009; accepted for publication August 19, 2009.

Dr George N Konstantinou, MD, MSc
 Department of Allergy and Clinical Immunology
 417 NIMTS Army Hospital,
 70, Sappous Str.
 Amarousion 151 26
 Athens, Greece
 Email: gkonstantinou@gmail.com

Safety of a 2-Visit Cluster Schedule of Venom Immunotherapy in Outpatients at Risk of Life-threatening Anaphylaxis

I Sánchez-Machín,¹ C Moreno,² R González,¹ J Iglesias-Souto,¹ E Pérez,¹ V Matheu^{1,3,4}

¹Allergy Service, Hospital Universitario NS Candelaria, Santa Cruz de Tenerife, Spain

²Hospital Reina Sofía, Córdoba, Spain

³Research Unit, Hospital Universitario NS Candelaria, Santa Cruz de Tenerife, Spain

⁴Department of Clinical Sciences-Division IV, Lund University, Lund, Sweden

Key words: Honeybee. Insect allergy. Venom immunotherapy. Anaphylaxis.

Palabras clave: Abeja. Alergia a insectos. Inmunoterapia a veneno. Anafilaxia.

The prevalence of systemic reactions to Hymenoptera venom in Europe and the United States is around 3% [1]. Venom immunotherapy (VIT) protects susceptible patients from subsequent life-threatening reactions [2,3]. In a conventional VIT build-up schedule, injections are administered once weekly for 12 weeks to reach the maintenance dose (usually 100 µg of protein extract) capable of providing protection against a new sting [2]. Since VIT must be administered in hospitals with the appropriate resources and experience, costs are high because of frequent visits, travel time, and waiting time. These drawbacks diminish adherence, although they can be overcome using schedules with a rapid build-up phase [4] based on cluster schedules [5] and depot extracts [6]. Our objective was to determine the safety of a cluster schedule comprising 6 doses over 2 weeks in the build-up phase of VIT in patients who experience systemic reactions for 1 year.

From April 2008 to April 2009, we included patients with a new diagnosis of bee venom allergy and indication for immunotherapy: history of grade I to IV systemic reactions [7] after a bee sting, risk of a new exposure, and positive serum immunoglobulin (Ig) E to bee venom (CAP, Phadia, Uppsala, Sweden) with or without a positive skin test result (Pharmalgen, Alk-Abelló, Spain) [8].

We used *Apis mellifera* venom depot extract (Pharmalgen) in a 2-day, 6-dose induction cluster schedule. On day 0, patients received subcutaneous injections (5 µg, 10 µg, 20 µg, 20 µg) of *Apis mellifera* venom extract on alternate arms at 30-minute intervals. After the last injection, patients were kept under observation for 2 hours. On day 7, each patient received 2 subcutaneous injections with 50 µg on alternate arms at 30-minute intervals and was kept under observation for 2 hours. This was followed by monthly administration of 100 µg of venom extract. All the patients received information about this protocol and gave their written informed consent. Patients were pretreated with 6 mg of dexchlorpheniramine [9].

Fifty-four patients (17 females and 37 males; mean age, 40.4 years [range, 7-66 years]) who had experienced a systemic

Table. Results of Systemic Reactions With a 6-Dose Cluster Schedule of Venom Immunotherapy in Patients With Systemic Reaction After Bee Sting

Diagnosis			Treatment With Venom Immunotherapy				
Grade of reaction	No. of patients	Positive skin test result	No. of doses	Systemic reaction	%	Local reaction	%
I	7	5	42	0	0	6	14
II	10	9	60	0	0	12	20
II ^a	26	14	156	1	0.64	28	18
III	10	5	60	3 ^b	5	9	15
IV	1	1	6	0	0	3	50
Total	54	34	324	4	1.23	58	17.9

^aWith bronchospasm

^bAll in the same patient

reaction were included (Table). Skin prick test results were positive in 14 patients and intradermal test results were positive in a further 20 patients. Mean specific IgE to *Apis mellifera* was 22.09 kU_A/L (range, 0.58-100 kU_A/L; median, 8.74 kU_A/L). Of the 324 doses administered, immediate local reactions were seen in 22 patients, all of them on the first day. These were treated with ice and did not require the initial schedule to be changed. Delayed local reaction was seen in only 1 patient. Only 4 systemic reactions (urticaria) were observed. After the build-up phase, 3 patients were re-stung spontaneously, 2 of them with good tolerance. The third patient suffered a local reaction.

Bee VIT is effective at preventing new systemic events [2]. Increasing the flexibility of immunization schedules can improve adherence to potentially life-saving treatment. Rueff and Przybilla [9] showed that administration of VIT with aqueous extracts in inpatients is sometimes recommendable and indispensable. However, the frequency of systemic effects is lower if depot extracts are used, as shown by our results. Although local reactions were observed in most patients, they were mild and did not have to be treated with drugs and did not require the initial schedule to be changed. Furthermore, local effects were absent on day 7. No severe anaphylactic reactions were observed, and none of our patients required treatment with epinephrine. In conclusion, our data demonstrate the safety of our 6-dose VIT protocol with a depot extract of bee venom. Studies with wasp and yellow jacket venom depot extracts will also be necessary.

Acknowledgments

Víctor Matheu holds a grant from Fondo de Investigaciones Sanitarias "Convenio Instituto de Salud Carlos III - Comunidad Autónoma de Canarias (Programa de Intensificación de la Actividad Investigadores Clínicos 2007-2008-2009).

References

- Bilo BM, Bonifazi F. Epidemiology of insect-venom anaphylaxis. *Curr Opin Allergy Clin Immunol*. 2008;8:330-7.
- Golden DBK. Insect allergy; in Adkinson NF, Brochner, BS, Busse, WW, Holgate, ST, Lemanske, RF, Simons, FER. (ed Middleton's Allergy, 7th edition: Principles and practice, Elsevier Inc., 2009, vol 2, pp. 1005-17.
- Bernstein JA, Kagen SL, Bernstein DI, Bernstein IL. Rapid venom immunotherapy is safe for routine use in the treatment of patients with hymenoptera anaphylaxis. *Ann Allergy*. 1994;73:423-8.
- Moreno C, Cuesta-Herranz J, Fernandez-Tavora L, Alvarez-Cuesta E. Immunotherapy safety: A prospective multi-centric monitoring study of biologically standardized therapeutic vaccines for allergic diseases. *Clin Exp Allergy*. 2004;34:527-31.
- Parmiani S, Fernandez Tavora L, Moreno C, Guardia P, Rico P. Clustered schedules in allergen-specific immunotherapy. *Allergol Immunopathol (Madr)* 2002;30:283-91.
- Cox L. Accelerated immunotherapy schedules: Review of efficacy and safety. *Ann Allergy Asthma Immunol*. 2006;97:126-37; quiz 137-40, 202.
- Wuthrich B. Classification of sting insect sensitivity. *J Investig Allergol Clin Immunol*. 2001;11:132.
- Golden DB, Kagey-Sobotka A, Norman PS, Hamilton RG, Lichtenstein LM. Insect sting allergy with negative venom skin test responses. *J Allergy Clin Immunol*. 2001;107:897-901.
- Rueff F, Przybilla B. Venom immunotherapy. Side effects and efficacy of treatment. *Hautarzt*. 2008;59:200-5.

■ Manuscript received May 28, 2009; accepted for publication August 28, 2009.

Victor Matheu, MD, PhD

Hospital Universitario NS Candelaria
38010 Santa Cruz de Tenerife, Spain
E-mail: victor.matheu@med.lu.se