

**MATERIAL SUPPLEMENTARY**

**Figure 1.** Ultrasound image of the neck in Patient #7, after the ICM re-exposure. (A) Right submandibular gland and (B) left submandibular gland ultrasound show enlarged glands and hypoechoic linear streaks (white arrows in A and B) within the glands and the subcutaneous tissue compatible with edema. There is also subcutaneous edema in the submental region (white arrows in C). (D) Color Doppler images of the submandibular glands also shows increased parenchyma

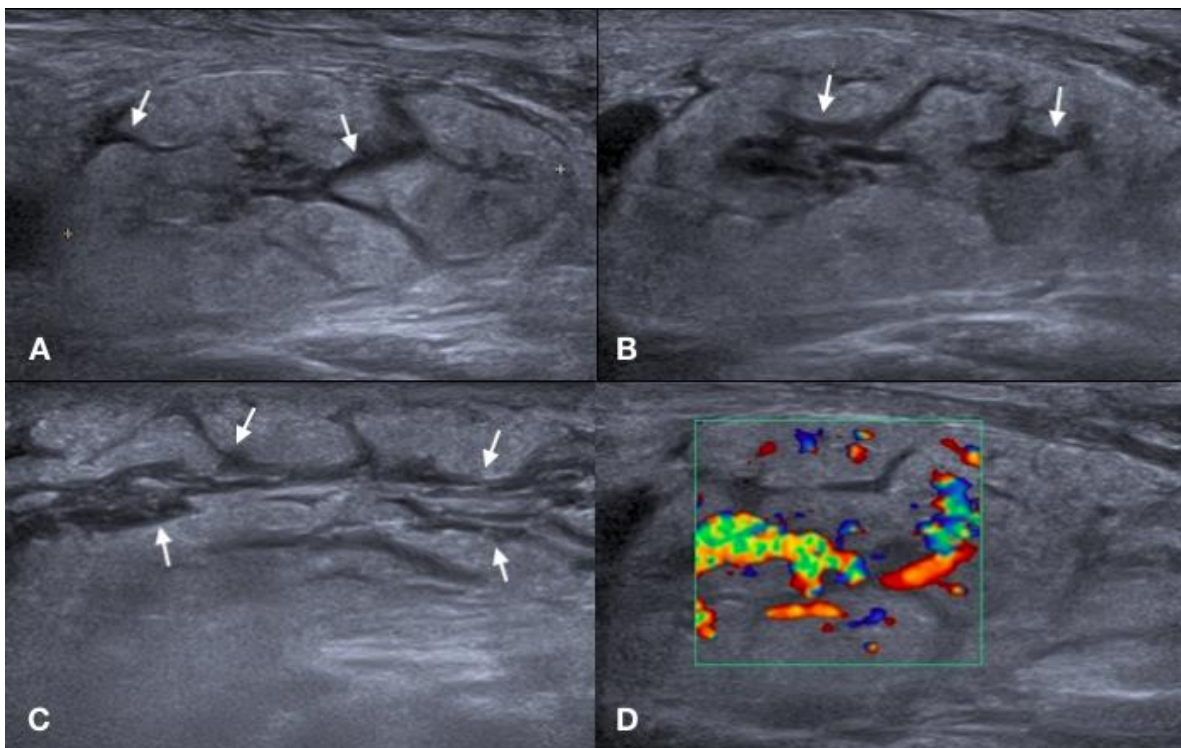


Figure 2.

