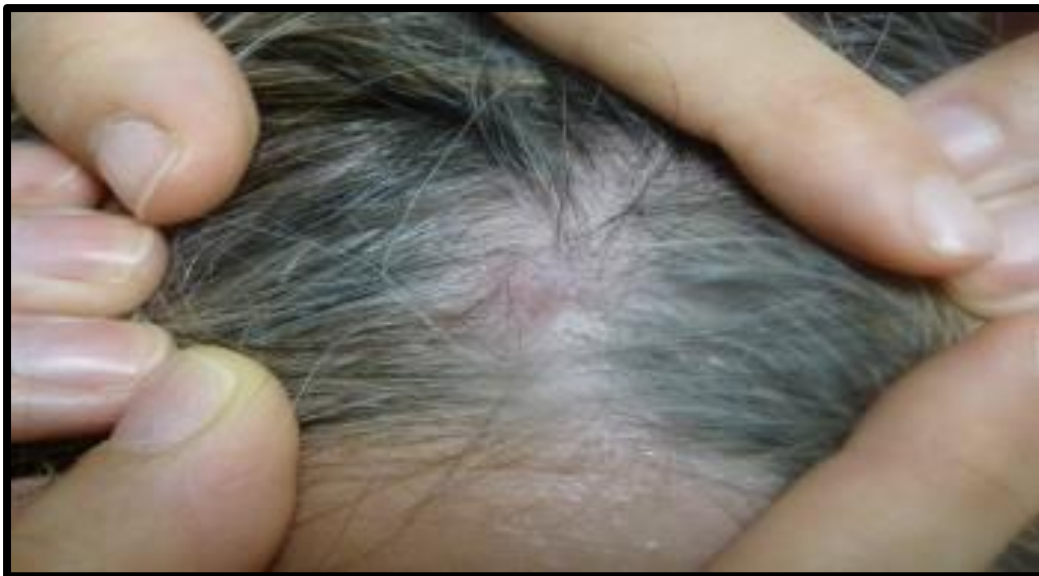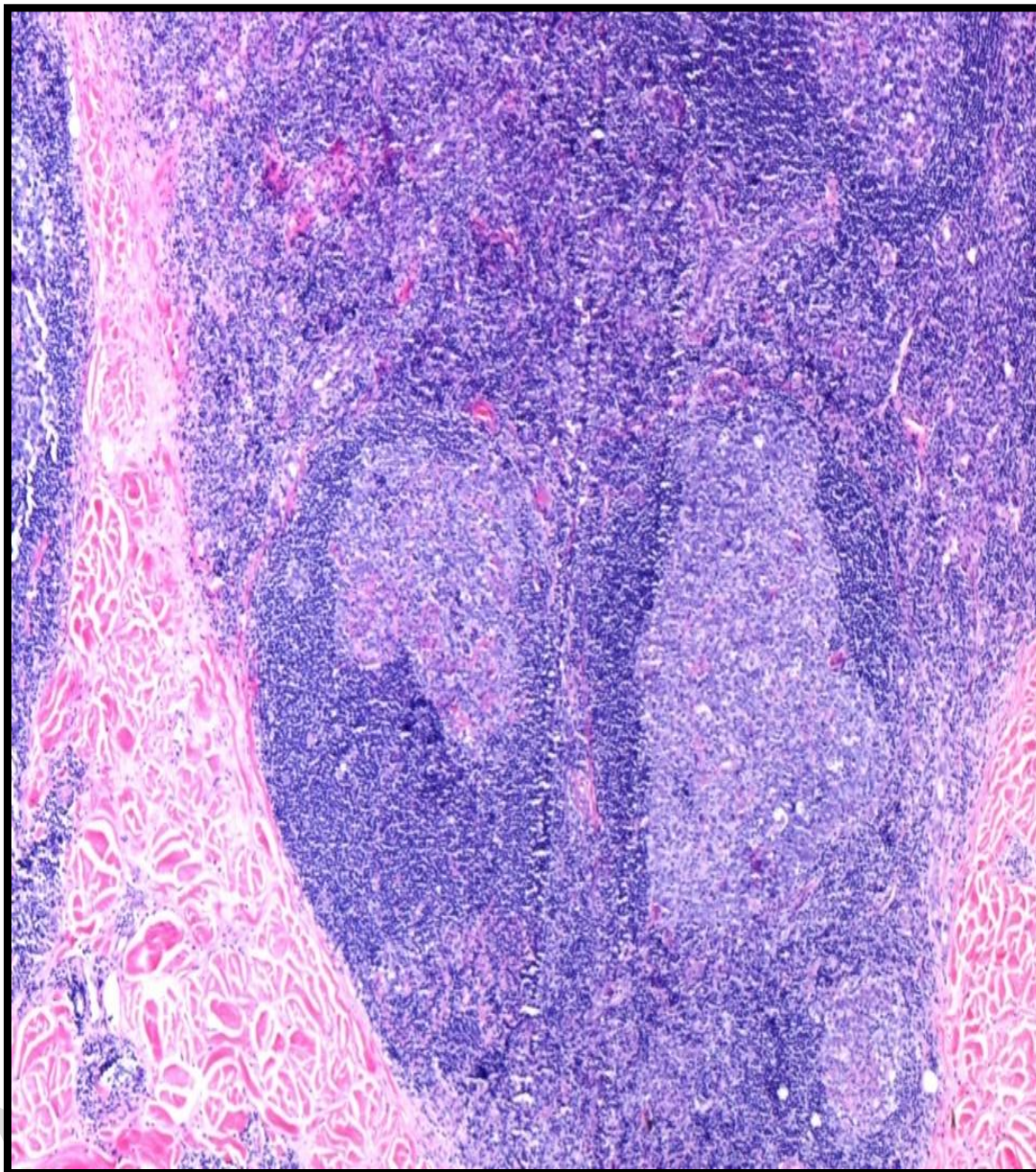


SUPPLEMENTARY MATERIAL

Supplementary figure 1: scalp lesions.



Supplementary Figure 2. Histology of the arm and scalp lesions: dense infiltrate of lymphocytes with the presence of lymphoid follicles with a reactive terminal center in the deep dermis (HE 40x).



Supplementary Figure 3. Immunohistochemical techniques show the predominance of B lymphocytes (CD20+, 40x).

