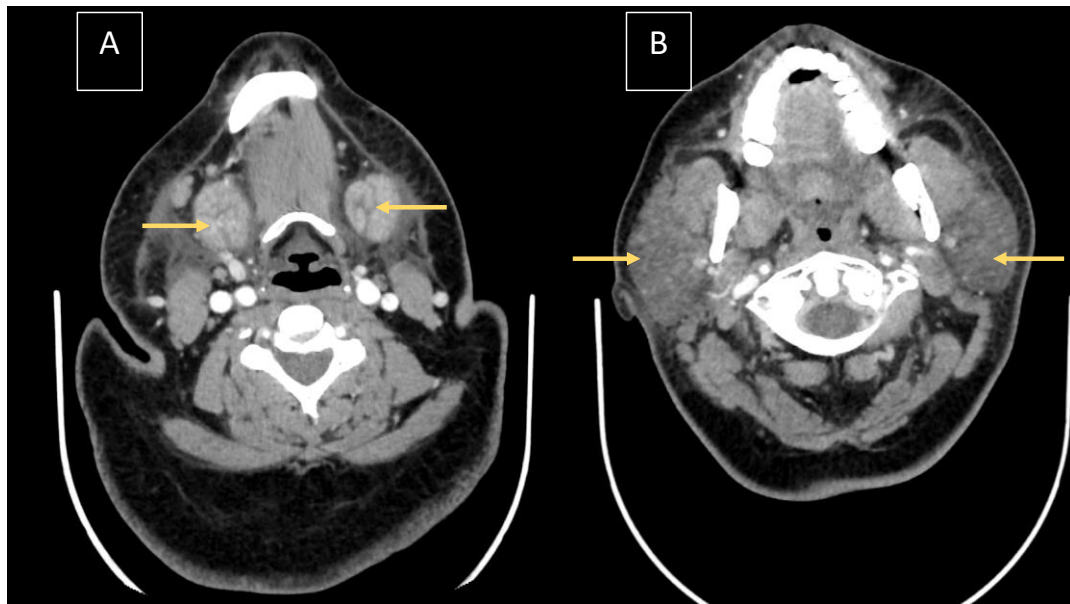
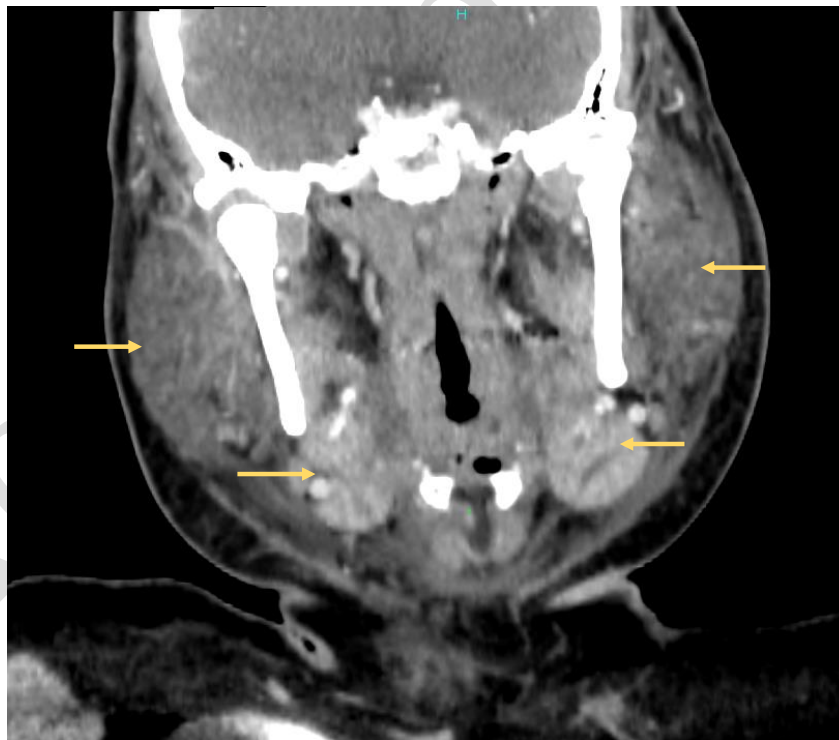


SUPPLEMENTARY MATERIAL



Supplementary figure 1 : CT scan showing (A) the swelling of the submandibular glands (left : 27*27*39 mm , right : 28*27*26 mm), and (B) the swelling of the parotid glands (left : 46*70*79mm , right : 62*36*66mm).



Supplementary figure 2 : Coronal view of the submandibular and the parotid glands (already shown in the axial view on fig.1)