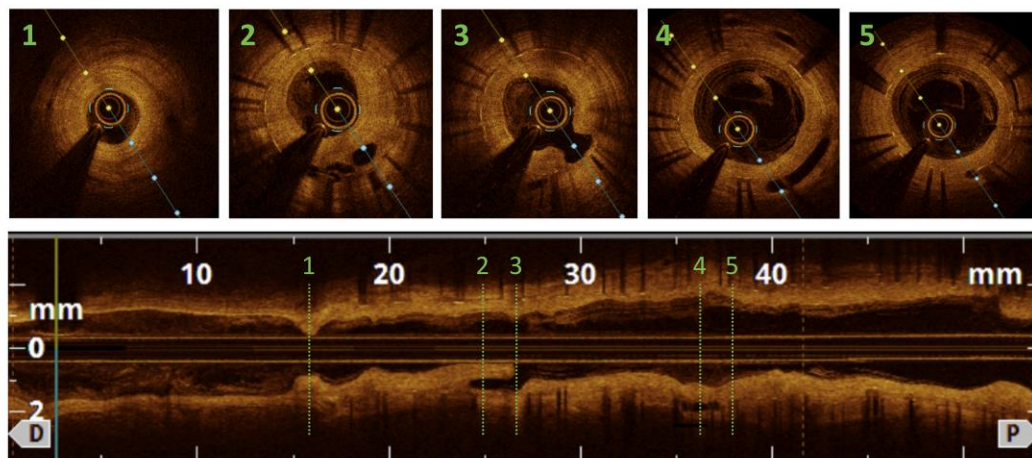


SUPPLEMENTARY MATERIAL

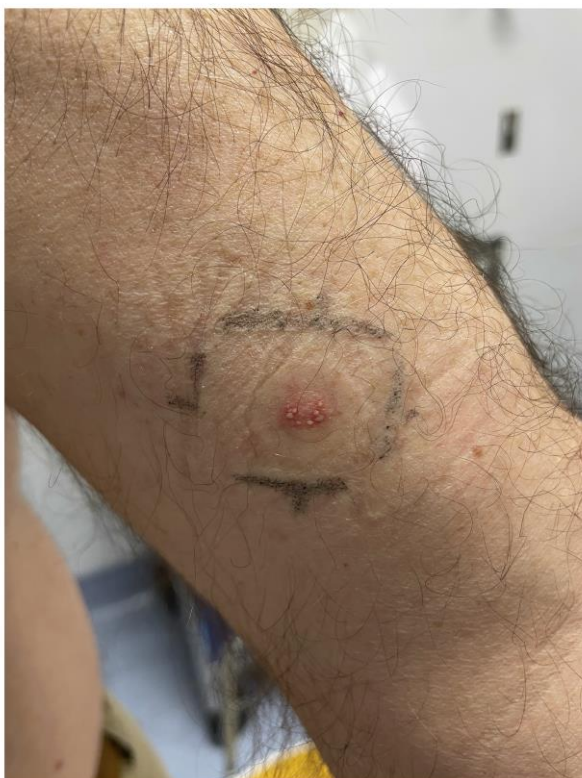Supplementary file 1. Optical-coherence tomography.

Axial and longitudinal images from optical coherence tomography intracoronary interrogation showing in-stent severe restenosis. Cross-section 1 shows minimal luminal area (1.0 mm^2) with bright, homogeneous, severe neointimal formation. Cross-sections 2 and 3 depict a confined cavity on the neointimal tissue, and cross-section 4 shows less severe in-stent neointimal formation. Cross-section 5: mild-moderate neointimal formation in proximal stented segment.



Supplementary file 2. Patch test with vanadium.

Intense erythema, infiltrate and coalescing vesicles (+++) to vanadium (III) chloride 1% at 96 hours reading.



Supplementary file 3. Cell stimulation index according to metal salts and mTOR concentration.

