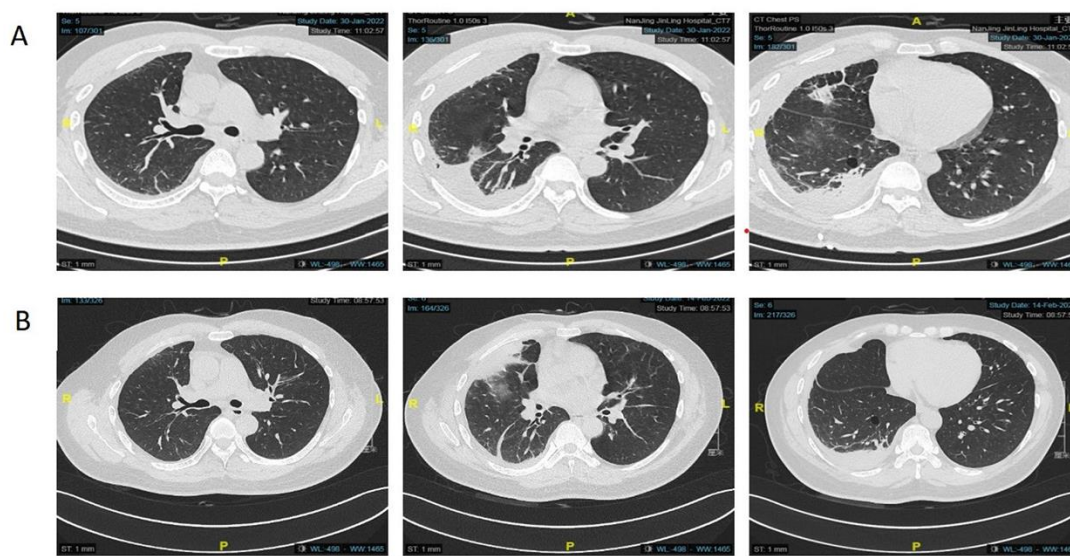


## SUPPLEMENTARY MATERIAL

## Supplementary Figure 1.



**Supplementary Figure 1** Computed tomography (CT) images on admission of the patient showed multiple cords in both lungs and right lower lung atelectasis with right pleural effusion (A), and CT images after 15 days of anti-infection treatment showed significant improvement of the lung lesions in comparison (B).

## Supplementary Figure 2.

