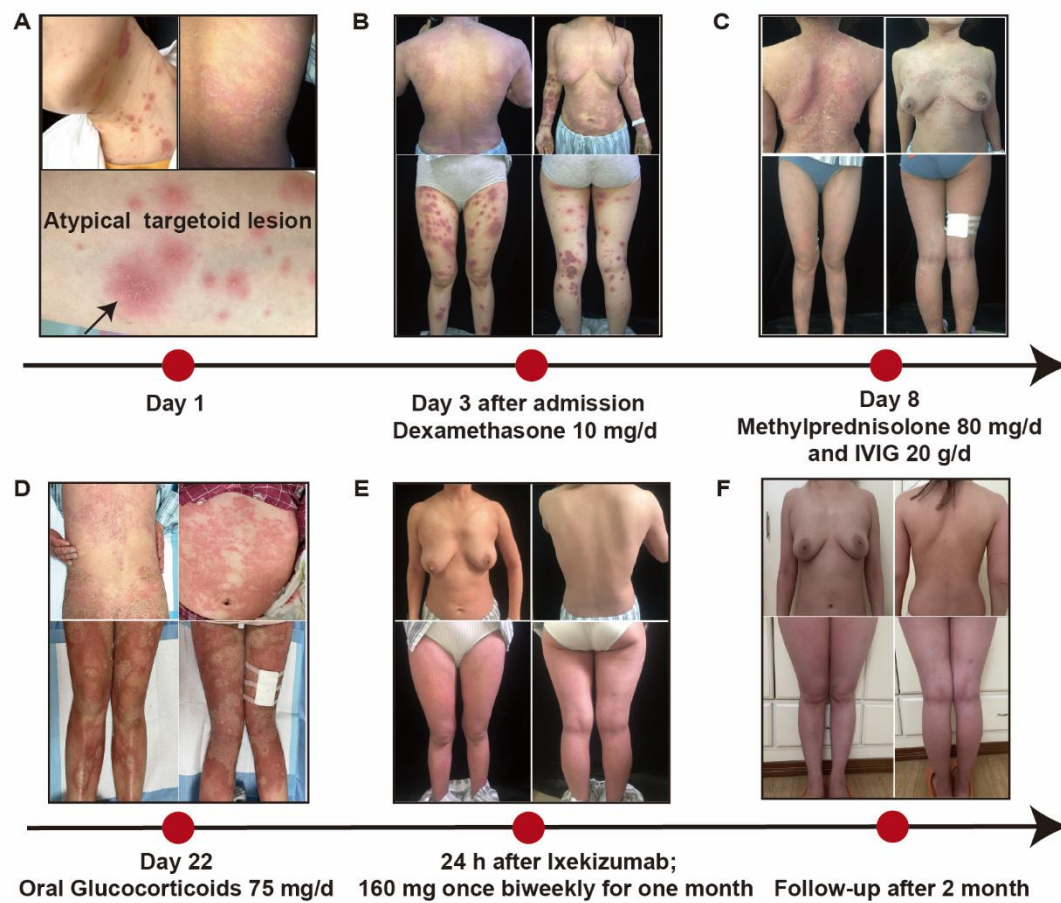


## SUPPLEMENTARY MATERIAL

Supplemental Figure 1. Detailed time line and strategy for the therapeutic process.



**Supplemental Figure 2.** (A) Histopathologic analysis of the skin infiltrates. Hematoxylin-eosin, IL-17A and TNF- $\alpha$  staining of different patients. The AGEP patient without targetoid lesions was a 67 years old male who was successfully treated by dexamethasone 10 mg/day in our department. (B) Comparison of the ratios of corticosteroid-sensitive patients in AGEP with or without targetoid lesions induced by HCQ.

