

Clinical Practice Guidelines for Diagnosis and Management of Hypersensitivity Reactions to Quinolones

Doña I¹, Blanca-López N², Boteanu C³, Cueva-Oliver B⁴, Fernández-Sánchez FJ⁵, Gajate P⁶, García-Avilés MC⁷, García-Núñez I^{8,9}, Lobera T¹⁰, Moreno E¹¹, Rojas P¹², Rosado A¹³

¹Allergy Unit, Hospital Regional Universitario de Málaga, Allergy Research Group, Instituto de Investigación Biomédica de Málaga-IBIMA, Hospital Regional Universitario de Málaga, Málaga, Spain

²Allergy Service, Infanta Leonor University Hospital, Madrid, Spain

³Allergy Service, Hospital Central De la Cruz Roja San José y Santa Adela, Madrid, Spain

⁴Allergy Section, Hospital General Universitario de Alicante, ISABIAL, Alicante, Spain

⁵Allergy Section, Hospital General Universitario de Alicante, UMH-ISABIAL, Alicante, Spain

⁶Allergy Service, Hospital Rey Juan Carlos, Móstoles (Madrid), Spain

⁷Allergy Unit, Hospital Universitario Moncloa, Madrid, Spain

⁸Allergy and Pulmonology Department, Hospital Quirón Salud Campo de Gibraltar, Cádiz, Spain

⁹Allergy Department, Hospital Quirónsalud Córdoba, Córdoba, Spain

¹⁰Department of Allergy, San Pedro University Hospital, Logroño (La Rioja), Spain

¹¹Allergy Service, University Hospital of Salamanca, Institute for Biomedical Research of Salamanca (IBSAL), Salamanca, Spain

¹²Allergy Service, Hospital General Universitario Gregorio Marañón, Madrid, Spain

¹³Allergy Unit, Hospital Universitario Fundación Alcorcón, Madrid, Spain

J Investig Allergol Clin Immunol 2021; Vol. 31(4): 292-307

doi: 10.18176/jiaci.0669

■ Abstract

The consumption of quinolones as first-line treatment has increased in recent years, leading to an increase in the incidence of hypersensitivity reactions (HSRs) to this antibiotic group. Both diagnosis and management of HSRs to quinolones are complex and controversial. These practical guidelines aim to provide recommendations for effective clinical practice. The recommendations were drafted by an expert panel that reviewed the literature regarding HSRs to quinolones and analyzed controversies in this area.

Most HSRs to quinolones are immediate and severe. The risk for HSRs is higher in patients who report allergy to β -lactams, moxifloxacin-induced anaphylaxis, and immediate reactions than in patients who report reactions to quinolones inducing other symptoms. The usefulness of skin tests in diagnosing HSRs to quinolones is controversial, with sensitivity and specificity varying between studies. Most *in vitro* tests are produced in-house, with no validated commercial options. The basophil activation test has proven useful for diagnosing immediate reactions, albeit with diverse results regarding sensitivity. Drug provocation testing is currently the gold standard for confirming or excluding the diagnosis and for finding safe alternatives, although it is contraindicated in patients with severe reactions. Cross-reactivity between quinolones has proven controversial in several studies, with the lowest cross-reactivity reported for levofloxacin. Desensitization may be considered in allergy to quinolones when no other alternatives are available.

Key words: Drug allergy. Quinolones. Anaphylaxis. Skin test. Drug provocation test. Basophil activation test.

■ Resumen

En los últimos años ha aumentado el consumo de quinolonas como tratamiento de primera línea, lo que ha dado lugar a un aumento de la incidencia de reacciones de hipersensibilidad (RHS) a este grupo de antibióticos. Tanto el diagnóstico como el manejo de las RHS a las quinolonas son complejos y controvertidos. Esta guía tiene como objetivo ofrecer recomendaciones para una práctica clínica eficaz. Con este propósito, un panel de expertos ha revisado la literatura sobre las RHS a quinolonas y ha analizado las controversias en esta área.

La mayoría de las RHS a estos fármacos son inmediatas y graves, siendo el riesgo de sufrir una RHS más alto en los sujetos que reportaron alergia a betalactámicos, anafilaxia inducida por moxifloxacino y reacciones inmediatas en comparación con otras quinolonas y otros síntomas. En lo que respecta al diagnóstico de las RHS a quinolonas, la utilidad de las pruebas cutáneas es controvertida, ya que la sensibilidad y la especificidad varían de un estudio a otro. La mayoría de las pruebas *in vitro* se producen en cada centro, sin que existan pruebas comerciales validadas, y aunque la prueba de activación de basófilos es útil para el diagnóstico de las reacciones inmediatas, los resultados obtenidos son diversos en cuanto a sensibilidad. La prueba de provocación es hoy en día el patrón de oro para confirmar o excluir el diagnóstico, así como para encontrar alternativas seguras. Existen controversias con respecto a la reactividad cruzada entre las quinolonas en los diferentes estudios, siendo el levofloxacino la que induce menor reactividad cruzada. En los pacientes con diagnóstico de RHS confirmada a quinolonas, se puede considerar la desensibilización cuando no existe ninguna otra alternativa.

Palabras clave: Alergia a medicamentos. Quinolonas. Anafilaxia. Tests cutáneos. Test de provocación. Test de activación de basófilos.

Prologue

The objective of these guidelines is to provide useful information to ensure efficient and effective clinical practice in the diagnosis and management of hypersensitivity reactions (HSRs) to quinolones. The guidelines were developed by a group of expert allergy specialists from the Drug Allergy Committee of the Spanish Society of Allergy and Clinical Immunology (SEAIC). All of the specialists have considerable experience in the evaluation and management of drug-induced HSRs and extensive experience in research. A bibliographic search for studies on HSRs to quinolones was performed and included available scientific evidence up to September 2020. The main sources for the search included electronic databases (MEDLINE and PubMed), electronic libraries (Science Direct, OVID), and a systematic review database (Cochrane Library). We considered prevalence, pathogenesis, clinical manifestations, diagnosis, and treatment of HSRs to quinolones. The key words used were quinolone, the name of each quinolone (*ciprofloxacin*, *levofloxacin*, *moxifloxacin*, *norfloxacin*, *lomefloxacin*, *gatifloxacin*, *oxolinic acid*, *nalidixic acid*, and *pipemidic acid*), as well as the terms *allergy*, *hypersensitivity*, *anaphylaxis*, *immediate reactions (IRs)*, *non-immediate reactions (NIRs)*, *delayed reactions*, *skin test (ST)*, *skin prick test (SPT)*, *intradermal test (IDT)*, *in vitro test*, *drug provocation test (DPT)*, and *desensitization*. From the articles found, we selected only original articles and systematic reviews. We excluded nonsystematic reviews, commentaries, and other types of studies. Grades of recommendation were discussed by the whole group and defined according to the Scottish Intercollegiate Guidelines Network [1]. Lack of evidence was resolved by consensus.

Introduction

Quinolones have proven increasingly useful, given their wide range of antibacterial activity and easy administration. Several epidemiological studies show that, in recent years, the consumption of this group of antibiotics as first-line treatment has grown [2-4].

Quinolones are generally well-tolerated, although HSRs and phototoxicity have been reported. Indeed, the incidence of HSRs involving quinolones has increased 10-fold in recent years [5-7], to the extent that they are currently one of the most frequent causes of consultation for suspected allergic reactions to medications [6,8]. This has become an important health problem, as 70% of HSRs can be severe, including anaphylactic reactions and toxic epidermal necrolysis (TEN) [2,9-12]. Quinolone-induced anaphylaxis has been reported to account for 4.5% of cases of drug-induced anaphylaxis [13].

Diagnosis is challenging, as the clinical history is often unreliable and STs and *in vitro* tests have important limitations [2]. Therefore, DPT is considered the gold standard for diagnosis, despite not being a risk-free procedure [2,14].

HSRs to quinolones have also been associated with β -lactam allergy, thus reducing options for a safe alternative in affected patients [15].

Therefore, given such a complex scenario, it is essential for the allergist to become familiar with the peculiarities of diagnosis and treatment of HSRs to quinolones.

Classification, Chemical Structure, and Mechanism of Action

Quinolones form drug-enzyme-DNA complexes, in which the DNA is broken by direct inhibition of 2 bacterial enzymes: DNA gyrase and topoisomerase IV [16,17]. They have fast bactericidal and dose-dependent activity. Structurally, quinolones are composed of the 4-oxo-1,4-dihydroquinoline ring core with a nitrogen atom at position 1, a carbonyl at position 4, and a carboxyl at position 3. Several structural changes have been introduced since the molecule was first synthesized [18], thus improving antimicrobial effectiveness and broadening the antibacterial spectrum, with better bioavailability, greater tissue penetration, and, consequently, longer half-life [19]. Quinolones have been classified into 4 groups based on their chemical structure and their antibacterial spectra [19-21] (Figure 1). The first-generation quinolones (oxolinic acid, nalidixic acid, cinoxacin, and pipemidic acid) are active against enterobacteria and some gram-negative bacteria. They are mainly administered orally, reaching low systemic levels and high concentrations in urine; hence their use as urinary tract antiseptics. The introduction of the fluorine atom at position C-6 led to the development of the fluoroquinolones, or second-generation quinolones (ciprofloxacin, norfloxacin, ofloxacin, pefloxacin, fleroxacin, lomefloxacin, enoxacin), which have potent broad-spectrum antibacterial activity, including activity against gram-negative bacteria, and an alkylated pyrrolidine or piperazine at C7, which increases serum half-life and potency against gram-positive bacteria. A halogen (F or Cl) at position 8 (third-generation quinolones: levofloxacin and gatifloxacin) improves oral absorption and activity against *Pseudomonas aeruginosa*, gram-positive bacteria, and anaerobes [22]. Finally, the fourth group (moxifloxacin, gemifloxacin, and trovafloxacin) is more active against gram-positive bacteria and anaerobes owing to a double ring derived from the pyrrolidone ring at position 7 and a methoxy group at position 8, although this decreases its activity against *P. aeruginosa*.

Pathogenesis of HSRs to Quinolones

HSRs to quinolones can be classified into IRs and NIRs, depending on the time interval between drug intake and the onset of the reaction [2,23]. Typically, IRs occur within the first hour following the first administration of a new course of treatment, although in terms of pathophysiology, this interval can extend to 6 hours after administration [23]. NIRs may occur any time from 1 hour after the initial administration and commonly occur after many days of treatment [23].

IRs are the most common reactions [2,10,12,15,24] and include urticaria, angioedema, and anaphylaxis, suggesting an IgE-mediated response resulting from mast cell and/or basophil degranulation triggered by cross-linking of IgE/Fc ϵ RI. Indeed, IgE antibodies to ciprofloxacin and other quinolones in serum have been detected in 30%-55% of patients with confirmed allergic IRs to these drugs. These antibodies have demonstrated high specificity to quinolones, as confirmed by inhibition assays [9,25]. It is important to take into account that an HSR may occur in the absence of previous exposure to quinolones

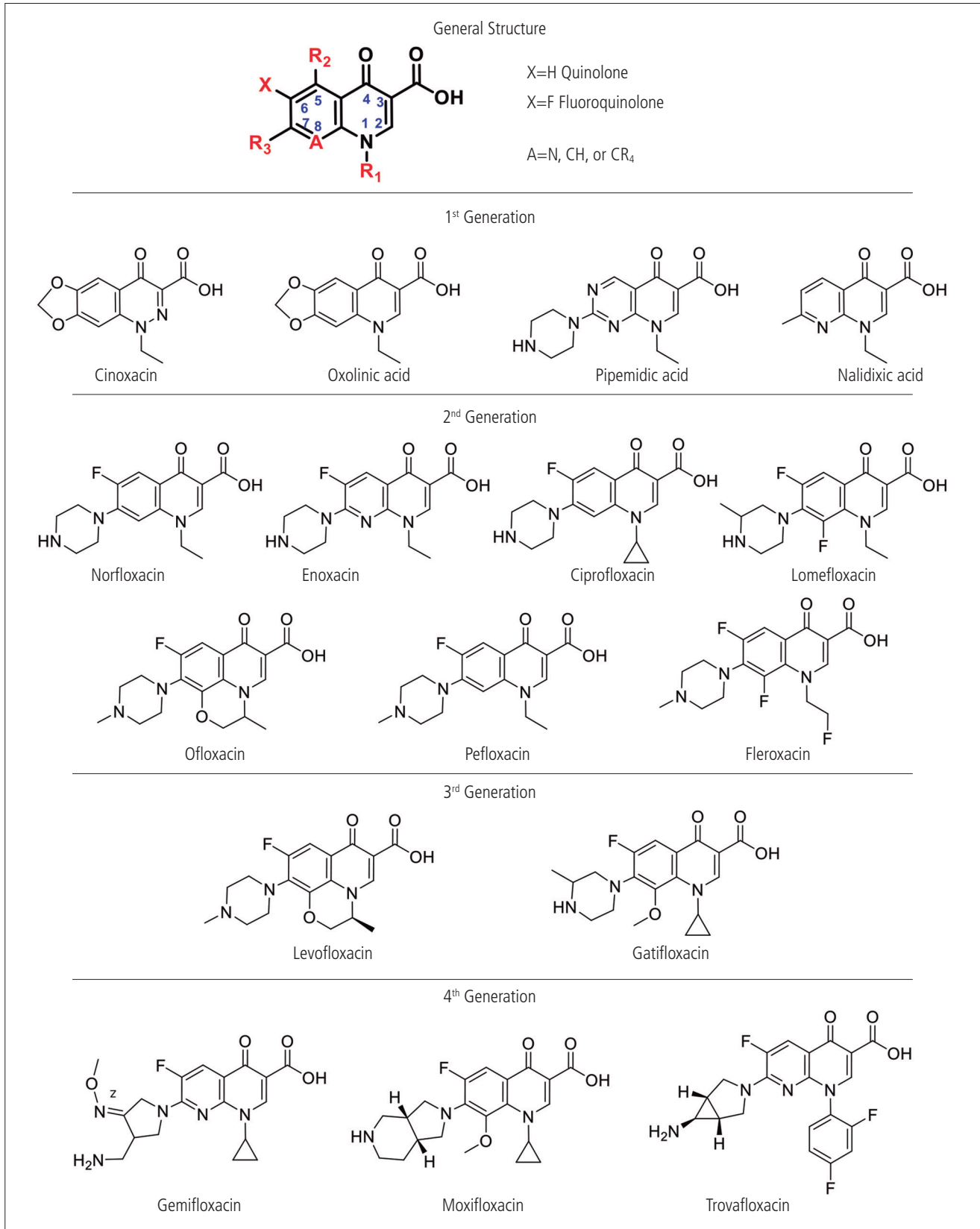


Figure 1. Chemical structures of quinolones according to generation.

if the patient is previously sensitized by exposure to apparently unrelated chemical compounds, as has been reported for neuromuscular blocking agents (NMBAs) [26]. Specific IgE (sIgE) against quaternary ammonium has been reported in 53% of patients with confirmed IRs to quinolones [27]; therefore, it could be hypothesized that this component is involved in the origin of IgE to quinolones in naïve patients who experience HSR. However, this possibility has not been confirmed, and the *in vivo* relevance of these findings remains unclear.

Not all IRs are IgE-mediated, although the clinical symptoms are indistinguishable from those that are. An increasing number of studies have demonstrated and/or speculated on the ability of quinolones and other drugs to trigger mast cell activation and degranulation via occupation of the mast-related G-protein receptor X2 (MRGPRX2) [28-35]. *In vivo* and *in vitro* experimental models have demonstrated the capacity of fluoroquinolones for activating mast cells and inducing release of mediators in wild type mice, although this is reduced in MrgprB2^{MUT} mice [28]. Moreover, activation by ciprofloxacin can be inhibited by an MRGPRX2 antagonist, the tripeptide QWF (glutaminy-D-tryptophylphenylalanine), as demonstrated in *in vitro* and animal models [29,36]. This off-target alternative mechanism of mast cell activation may explain the positive STs seen in healthy controls [22,37], thus potentially reflecting the potent nonspecific release of mediators [38-40].

It was recently reported that MRGPRX2 is expressed not only on mast cells, but also on basophils and eosinophils, and that ciprofloxacin might mediate its effect by enhancing MRGPRX2 surface expression on basophils and eosinophils and inducing degranulation through binding to this receptor [41]. In this case, the evaluation of these reactions using BAT can produce false-positive results. However, other authors indicate that basophils barely express MRGPRX2, and HSRs resulting from MRGPRX2 occupancy will probably yield negative BAT results [33].

In any case, BAT seems not to be the best tool for evaluating MRGPRX2-mediated reactions, in contrast with IgE-mediated reactions [35,42]. Additionally, cases with positive responses in both STs and BAT are more likely to be IgE/FcεRI-dependent reactions [9,15,29,32,43-48].

It is noteworthy that despite the involvement of this receptor in fluoroquinolone-induced mast cell activation, the fact that it is present in the human body and that, nevertheless, very few patients experience HSR to this drug class indicates that other factors must be involved in predisposed individuals. This predisposition to immediate drug-induced reactions may be related to single-nucleotide polymorphisms resulting in hyperactivation by changing the structure of the MRGPRX2 receptor and receptor binding sites [35]. It may also be associated with epigenetic modifications due to environmental influences [35], posttranscriptional modifications resulting in synthesis of MRGPRX2 variants (temporarily or constitutively altering surface expression), and even the influence of cofactors [35].

Despite the mechanisms involved in mast cell/basophil degranulation, the steps for diagnosing and managing patients who experience a reaction after intake of quinolones are similar, although we must be aware of the false-positive ST results and false-negative BAT results that may be produced by MRGPRX2-mediated activation.

NIRs are thought to be T cell-mediated. However, the immunogenicity of quinolones for T cells has not yet been studied in detail [49-51]. Two models describe how quinolones, as small molecular compounds (≤ 1000 Da), might interact with immune proteins to elicit T-cell reactivity. In the first, the hapten model, the drug is thought to bind covalently to a macromolecular carrier, such as a larger endogenous peptide or protein, to generate a neoantigen that stimulates a T-cell response [52,53]. In the second, the P-I model, a small molecule is thought to bind noncovalently to HLA to directly stimulate T cells [48,54,55], resulting in the presentation of novel peptide ligands that elicit an immune response.

IRs and NIRs to quinolones can be induced by the relevant quinolone without the need for metabolism or processing. However, the possibility that quinolone metabolites can induce an HSR cannot be excluded, although to our knowledge, no evidence has been published to date.

Epidemiology and Risk Factors

Although HSRs to quinolones are considered unusual, their incidence is increasing [10,56,57], due in part to their increasingly frequent prescription [4,5] and the introduction of potentially more immunogenic quinolones such as moxifloxacin [12,15,24,57,58]. In Spain in particular, frequency increased from 0.53% in 2005 to 5.96% in 2009 [6]. In the case of children, the estimated risk of suspected adverse reactions to quinolones has been reported to be 0.046% [45]. These agents now rank as the third cause of confirmed HSRs to drugs, with non- β -lactam antibiotics being the most frequently involved in HSRs [6]. Among hospitalized patients, quinolones are the second most commonly reported group of antibiotics in drug alerts and intolerance [59].

Based on spontaneous reports of quinolone-induced anaphylaxis, incidence has been estimated at 1.8-2.3 cases per 10 000 000 days of treatment, ie, 4.5% of cases of anaphylaxis caused by drugs [13]. In fact, the risk of developing HSRs may differ between quinolones and has been reported to be 96 times higher in persons who reported moxifloxacin-induced anaphylaxis and 18 times higher in those reporting IRs, compared with patients who experience clinical conditions induced by quinolones other than moxifloxacin and NIRs [12]. The risk of an IR to quinolones is up to 4 times greater when moxifloxacin is the culprit, compared with other quinolones [12,60]. Ciprofloxacin has been associated with a 6-fold increased risk of having a severe delayed skin reaction [60], and norfloxacin, ofloxacin, and ciprofloxacin with an increased risk of acute generalized exanthematous pustulosis (AGEP) [2,60,61]. In addition, quinolones in general have been associated with a high risk of Stevens-Johnson syndrome (SJS) and TEN [62]. Old age, concomitant levothyroxine treatment, and HIV infection have been reported to be associated with poorer prognosis in SJS and TEN [60]. Moreover, HIV-infected adult patients more frequently experience reactions to ciprofloxacin, including anaphylaxis [56]. There is also a risk of hepatotoxicity by quinolones, especially in patients with excessive alcohol intake [63].

It has been reported that 21% of patients who are allergic to β -lactams develop allergy to other antibiotics such as

quinolones, compared with 1% who are not allergic to β -lactams [64]. Furthermore, it has been estimated that having an IR to β -lactams increases the risk of an HSR to quinolones 23-fold [15] (level of evidence, 2+). It is not clear whether there is an individual predisposition to HSRs to drugs or whether patients with previous allergy to β -lactams are more likely to be prescribed a quinolone. Therefore, more studies are needed to clarify the mechanisms involved in this association. Given that quinolones can induce MRGPRX2-mediated mast cell degranulation, patients with mastocytosis have an increased risk of HSR (up to 50%) [34].

Clinical Symptoms

Table 1. Clinical Manifestations and Tests Used to Confirm the Diagnosis of Hypersensitivity Reactions to Quinolones

Type of Reaction	Index Reaction	Confirmatory Testing and Result	Grade of Evidence
IR	Urticaria/angioedema	BAT [12,15,46] SPT [12,46,68,70] IDT [46,68,70] DPT [9,12,15,46,68,70]	2+
	Anaphylaxis	BAT [12,15,46,68] SPT [12,46,68,70] IDT [46,68,70] DPT [12,15]	2+
	Kounis syndrome	BAT [67] Specific IgE [67]	3
NIR	Urticaria	Delayed-reading IDT [70] PT [12] DPT [12,15,70]	2+
	MPE	LTT [70] Delayed-reading IDT [70] PT [69] DPT [12,15,68,69]	2+
	FDE	PT [12,71,72] DPT [12,72,73]	3
	AGEP	Histology [61,75] PT [69] LTT [61]	3
	SJS/TEN	Histology [78,79,81]	3
	Vasculitis	Histology [89,90]	3
	Bullous pemphigoid	Histology [91,92]	3
	Hypersensitivity pneumonitis	Histology [93,94]	3
	Interstitial nephritis	Histology [96]	3
	Hepatitis	Histology [97-99]	3

Abbreviations: AGEP, acute generalized exanthematous pustulosis; BAT, basophil activation test; DPT, drug provocation test; FDE, fixed drug eruption; IDT, intradermal test; IR, immediate reaction; LTT, lymphocyte transformation test; MPE, maculopapular exanthema; NIR, nonimmediate reaction; PT, patch test; SJS, Stevens-Johnson syndrome; SPT, skin prick test; TEN, toxic epidermal necrolysis.

IRs to quinolones are the most common type of HSRs to these drugs [2,10,12,15,24,57] and are characterized mainly by the presence of urticaria/angioedema (31.6%-85%), anaphylaxis (32.8%-62.5% of cases), and anaphylactic shock (13%-26.3%) [9,12,25,37,46,58] (Table 1) (level of evidence, 2+). Although all quinolones can induce IRs, the rate of reactions to moxifloxacin is higher than to other quinolones, specifically anaphylactic reactions [10,12,15,24,58]. In fact, 70% of reactions induced by moxifloxacin are anaphylactic [12] (level of evidence, 2+). Cases of Kounis syndrome induced by ciprofloxacin [65], cinoxacin [66], and levofloxacin [67] have also been reported (level of evidence, 3).

NIRs to quinolones are less frequent than IRs [2,12]. Delayed urticaria and maculopapular exanthema (MPE) are the most common NIRs, although they are usually not severe [12,15,37,68,69] (Table 1) (level of evidence, 2+). While ciprofloxacin is reported to be the main culprit [12], other quinolones may be involved [12,15,68-70] (level of evidence, 2+). Another common type of NIR is fixed drug eruption (FDE) [12,68], which has been reported with ciprofloxacin [12,71], norfloxacin [12,72], levofloxacin [73], moxifloxacin [12], and gemifloxacin [37]. Potential cross-reactivity between these agents has been observed [71-74] (level of evidence, 3). Cases of drug reaction with eosinophilia and systemic symptoms (DRESS) syndrome and AGEP induced by various quinolones have been published [61,68,69,75] (level of evidence, 3). Less frequent entities such as SJS and TEN have also been reported [76], with quinolones described as a causative agent in 8.48% [76] (level of evidence, 3). Ciprofloxacin has been reported to be the most frequent quinolone involved in SJS-TEN [77-80], although cases have also been associated with other quinolones such as levofloxacin [81,82], ofloxacin [83], moxifloxacin [84], and trovafloxacin [85] (level of evidence, 3).

Quinolones are among the most frequent photosensitivity-inducing drugs [86,87], leading to both phototoxic and photoallergic reactions [87] (level of evidence, 3). Their ability to elicit photosensitivity varies between the different quinolones, with pefloxacin and fleroxacin thought to be the most potent inducers of photoallergy, while enoxacin, norfloxacin, and ofloxacin are less able to induce these reactions [88] (level of evidence, 3).

Quinolone-associated vasculitis syndromes have been reported [89,90], with most induced by ciprofloxacin [89,90] (level of evidence, 3). Other skin reactions include bullous pemphigoid triggered by ciprofloxacin [91] and levofloxacin [92] (level of evidence, 3).

Hypersensitivity pneumonitis [93,94], interstitial nephritis [95,96], and hepatitis [97-99] associated with quinolone therapy have also been described (level of evidence, 3). A publication of the Drug-Induced Liver Injury Network described 12 cases of fluoroquinolone-induced liver injury, most of which were induced by ciprofloxacin [97] (level of evidence, 3).

Diagnosis

The diagnostic work-up for HSRs to quinolones should include a clinical history, STs, in vitro testing, and DPT [14,100,101].

Diagnosis is complex owing to several factors: heterogeneous clinical picture, insufficient understanding of the pathogenesis of HSRs, and the limitations and lack of standardization in current *in vivo* and *in vitro* diagnostic tests [57].

The diagnostic procedure must address 2 phases, namely, the acute phase and remission:

1. During the acute phase, the main question is whether or not symptoms are caused by an HSR. A detailed history of previous exposure and tolerance to the culprit drug is essential, as is a detailed description of the clinical picture. For IRs, it is important to assess the cells involved and mediators released during the reaction (eg, tryptase) [42,102,103]. Determination of peak serum tryptase level 30-120 minutes after onset of symptoms should be followed by a comparison of baseline levels [42,103-105]. The minimal clinically significant elevation has been reported to be $\geq 20\%$ above baseline plus 2 $\mu\text{g/L}$ [106] (level of evidence, 2+; grade of recommendation, C). For NIRs, determination of enzyme levels indicating liver or kidney involvement and the presence of eosinophilia are sometimes sufficient to indicate an HSR to drugs [107]. Skin biopsy and viral serology may also be useful for confirming the diagnosis and ruling out other possible causes [103,108,109] (level of evidence, 3; grade of recommendation, D).
2. After remission of the acute reaction, patients may require a further allergology work-up in order to determine which of the different drugs taken may have caused the reaction. This can take the form of specific *in vitro* tests, STs, or DPT.

Clinical History

A detailed clinical history is crucial for determining whether specific symptoms reflect HSRs to drugs and for identifying the eliciting drug. However, the appearance of similar symptoms does not confirm the underlying cause, which may involve quite different immune and even nonimmune mechanisms [110,111]. The data to be recorded are

as follows [101]: demographic data (eg, age, sex, occupation, race); personal and family history, focusing on drug allergy and other conditions; a detailed description of symptoms; the interval between the last drug administration and the onset of the reaction; cofactors (eg, fever, viral infection, photosensitivity, stress, exercise); quinolone involved in the reaction; other drugs taken at the time of the reaction; reason for quinolone intake; dose and route of administration; previous tolerance to quinolones; time between onset of the reaction and resolution; and treatment administered for resolution of the reaction (level of evidence, 4; grade of recommendation, D).

Skin Tests

The diagnosis of HSRs to quinolones by STs is controversial, based on clinical experience and previous studies.

For IRs, the procedure generally begins with SPTs and, if these are negative, IDTs [100]. The usual doses for SPTs and IDTs are shown in Table 2 (level of evidence, 2-; grade of recommendation, C).

However, since the earliest publications on this matter, the usefulness of STs has been controversial [112], as most studies show that quinolones can induce false-positive results owing to the capacity of some agents to directly induce histamine release because of mast cell activation [9,68]. Depending on the authors, ST results are considered nonspecific [9,38-40,68,113] or confirmed as allergic [114-120] (level of evidence, 2-), with DPT being the only diagnostic method to reveal the culprit drug or an alternative quinolone [37,46]. It has been suggested that the presence of a positive ST to any of the components of the group indicates mast cell activation (either by an IgE-dependent mechanism or by the MRGPRX2 pathway). While this hypothesis should be confirmed by DPT, a positive DPT result cannot distinguish between the 2 mast cell activation mechanisms [121] (level of evidence, 4).

The sensitivity of STs is estimated to range from 41% to 80%, with specificity ranging from 46.5% for all STs to 29% for IDTs [12,37,70,122,123] (level of evidence, 2-). The positive predictive value has been reported to range from 14.8% for all STs to 12% for IDTs [45,123,125] and the negative predictive value from 94%-95.2% for all STs to 90% for IDTs [45,123], as reported elsewhere [37,70,122,123] (level of evidence, 2-). Given that most study populations are small, quinolones generate many false-positive results attributed to nonspecific histamine release, mainly by IDTs [38,40], and a negative ST result is important when deciding to perform DPTs (grade of recommendation, C), we recommend including only SPTs and not IDTs in the diagnostic approach for IRs to quinolones, as negative results are useful for evaluating the introduction of alternative quinolones (level of evidence, 4; grade of recommendation, D).

For NIRs, the evaluation includes delayed-reading IDTs and patch tests (PTs) [100]. Positive PT results have been reported [125,126] (level of evidence, 3; grade of recommendation, D). When photosensitivity reactions are suspected, photopatch testing with UV-A exposure can be performed [127]. However, photopatch testing is usually negative in most publications [128,129] (level of evidence, 3), probably because of the false-negative results

Table 2. Drug Concentrations Recommended in Skin Tests

Drug	SPT	IDT
Ciprofloxacin	2 mg/mL [68,123]	0.02 mg/mL [123]
Levofloxacin	5 mg/mL [68,123]	0.05 mg/mL [38,123]
Moxifloxacin	1.6 mg/mL [40,68] Tablet 400 mg [123] suspended in saline solution	
Norfloxacin	Tablet 400 mg [123] suspended in saline solution	
Ofloxacin	2 mg/mL [68] 5 mg/mL [123] Tablet 400 mg [121] suspended in saline solution	0.05 mg/mL [123]

Abbreviations: IDT, intradermal test; SPT, skin prick test.

generated by the inadequate concentration of the drug used, type of vehicle, or poor skin absorption. The introduction of technical variations, such as scarified photopatch testing, could increase sensitivity [130] (level of evidence, 3; grade of recommendation, D). Cross-reactivity between lomefloxacin, ciprofloxacin, and fleroxacin has been observed in studies reporting positive test results [131] (level of evidence, 3).

In FDE, the results of PTs in the affected area are usually negative. Positive PT results to ofloxacin and ciprofloxacin include a reaction to ofloxacin in 20% pet [132], positive PT to levofloxacin in the affected area, and cross-reactivity with ofloxacin in a case of reaction to levofloxacin [133]. Positive PT results were also observed with ofloxacin 2% in dimethyl sulphoxide in healthy skin [134] (level of evidence, 3). Negative results have been reported in Spanish studies, in which dimethyl sulfoxide was used as a vehicle and with quinolones at a concentration of 10% [51,135]. Preparations of the drug in 10% pet are more usual, although variable concentrations of 5%-20% have also yielded negative results [50,72,73,136,137] (level of evidence, 3; grade of recommendation, D).

Vasculitis, purpura, exudative erythema, and TEN hamper performance of *in vivo* tests owing to the high risk of inducing the original reaction or an even worse reaction after the new contact with the drug. Therefore, PT can be considered in SJS and TEN, if there is a benefit from the diagnostic information obtained, although delayed-reading IDT is contraindicated [138] (level of evidence, 4; grade of recommendation, D).

In Vitro Tests

Most *in vitro* tests for identification of the culprit quinolone are produced in-house owing to the lack of validated commercial options.

For IRs, *in vitro* tests include the basophil activation test (BAT) and immunoassays for detecting quinolone sIgE. These are potentially useful for diagnosis [139] (grade of recommendation, C) and also for deciding whether to carry out a DPT.

sIgE to quinolones has been determined using radioimmunoassay based on a quinolone coupled to epoxy-activated Sepharose 6B as the solid phase, with high specificity and a lower sensitivity (30%-55%) confirmed in an inhibition assay [9,25] (level of evidence, 2-). The quinolone involved, the severity of the reaction, and the interval between the reaction and the study may account for the differences in sensitivity found in both studies cited above. Therefore, better results have been reported when ciprofloxacin is the culprit, in less severe reactions, and when the test was performed close to the reaction [9,25], since a loss of sensitivity over time has been identified for IgE-mediated HSRs to other drugs, such as β -lactams [140], dipyrone [141], and NMBAs [142] (level of evidence, 2-).

The BAT has been also found to be useful for *in vitro* evaluation of IRs to quinolones, albeit with very different results regarding sensitivity and reliability [9,12,43,47] (level of evidence, 2-). Reported sensitivity ranges widely (from

0% [47,68] to 90% [12]), as does specificity (from 80% [9] to 100% [47]). It is noteworthy that not all IRs induced by quinolones are IgE-dependent; they may also result from alternative IgE-independent effector cell activation, such as through off-target occupation of the MRGPRX2 receptor [34,35]. Because basophils barely express MRGPRX2, they do not respond in steady-state conditions of the classic BAT [33]. Therefore, it is not known whether a negative BAT result reflects insufficient sensitivity of the method, or whether a reaction is mediated by MRGPRX2 and is undetectable by measuring CD63/CD203c expression [35].

As mentioned above with radioimmunoassay, the sensitivity of the BAT is also related to the culprit quinolone, the severity of the reaction, and the interval between the reaction and performance of the test. It is also associated with the use of additional quinolones [12,43] (level of evidence, 2-; grade of recommendation, C). Indeed, if moxifloxacin is involved, the sensitivity of the BAT was 41.7% when only moxifloxacin was used, increasing to 79.2% when both moxifloxacin and ciprofloxacin were included in the tests [9]. However, when ciprofloxacin was the culprit, the inclusion of moxifloxacin in the test did not improve sensitivity. These findings may be due to the chemical structure and photodegradation of the molecules. Moxifloxacin is associated with a higher rate of photodegradation than ciprofloxacin [44], reducing the positivity of the test from 35.7% to 17.9% when the BAT was not carried out in darkness [44]. Moreover, the activation marker used in the test can also affect sensitivity, as ciprofloxacin preferentially upregulates CD63, whereas moxifloxacin induces greater upregulation of CD203c [43]. This could be related to the severity of the reactions, as moxifloxacin induces anaphylaxis more frequently than other quinolones [10,12,24,43,58]. Furthermore, upregulation of CD203c has been reported in patients who experienced anaphylactic shock, as has upregulation of CD63 in patients with anaphylaxis and urticaria [43,143-145]. The BAT response to quinolones is mainly IgE-mediated, as it is inhibited by the phosphatidylinositol 3-kinase (PI3K) inhibitor wortmannin [9]. PI3K has been shown to be one of the important kinases activated by the Fc ϵ RI receptor cross-linking involved in IgE-mediated stimulation of human basophils [146]; therefore, if basophil activation is inhibited by wortmannin, activation of basophils is IgE-mediated [9]. However, some reports indicate that the enzyme PI3K could be also involved in activation by MRGPRX2 [147]. Consequently, the results of wortmannin inhibition assays must be interpreted with caution. In any case, the negligible expression of MRGPRX2 in basophils could hamper its activation via this pathway.

For NIRs, most studies use the lymphocyte transformation test (LTT) to confirm T-cell involvement in the pathogenesis of NIRs such as MPE and AGEP [69,86,148] (level of evidence, 3; grade of recommendation, D). LTT is more sensitive than PTs, probably because of the complex inflammatory response in the skin, the low capacity of quinolones to penetrate the skin, or the use of low quinolone concentrations in PT [69,149] (level of evidence, 3).

Recent years have seen the use of other *in vitro* tests, such as ELISpot, which measures the number of cells producing IFN- γ or IL-4. However, in the only report of ciprofloxacin-induced exanthema to our knowledge, the result

Table 3. Doses of Quinolones Used in Drug Provocation Tests at Intervals of 60 Minutes [12,15,37,46]

	Doses for IR, mg	Doses for NIR, mg	Follow-up Doses in IR and NIR, mg ^a
Ciprofloxacin	5-50-100-150-200	1 st day: 5, 20, 100. 2 nd day: 125, 125, 250 mg	500
Levofloxacin	5-50-100-150-200	1 st day: 5, 20, 100. 2 nd day: 125-125-250	500
Moxifloxacin	5-50-100-100-150	1 st day: 5, 30, 65 2 nd day: 100-100-200	400
Ofloxacin	5-25-50-100-200	1 st day: 5, 25, 50 2 nd day: 100-100-200	400
Gemifloxacin	4-20-40-80-180	1 st day: 4, 20, 40 2 nd day: 80-80-160	320
Norfloxacin	5-50-100-100-150	1 st day: 5, 30, 65 2 nd day: 100-100-200	400

Abbreviations: IR, immediate reaction; NIR, nonimmediate reaction.

^aAt least 2 days of follow-up.

of testing was negative [150] (level of evidence, 3, grade of recommendation, D).

Further proof of the involvement of T cells in NIRs can be obtained by assessing whether peripheral blood mononuclear cells photo-modified with quinolones using UV-A light are able to stimulate homologous cell proliferation, as demonstrated in photoallergy studies [148,151] (level of evidence, 3; grade of recommendation, D).

Drug Provocation Testing

DPT is defined as the controlled administration of a drug in order to diagnose HSRs [14]. It is considered the gold standard for confirming or ruling out a diagnosis of HSR to quinolones when no other test is available [2,14] (level of evidence, 4; grade of recommendation, D). It is also useful to choose alternative quinolones and to evaluate cross-reactivity [2,14,15,70] (level of evidence, 2+; grade of recommendation, C).

DPT is not a risk-free procedure and must be performed under medical surveillance by trained personnel in a clinical setting where adequate treatment can be administered if a reaction occurs [14]. DPT after negative in vitro and STs should only be considered after balancing the risks and benefits for the individual patient [14,153] (level of evidence, 4; grade of recommendation, D). Various authors agree that DPT with the culprit or structurally/pharmacologically related quinolones is not indicated in anaphylaxis or in severe reactions [14,152-154] (level of evidence, 4; grade of recommendation, D). Therefore, taking into account the high incidence of severe HSRs induced by quinolones, the role of DPT in confirming/excluding the diagnosis of HSR to quinolones is limited. In most studies with quinolones, DPT is single-blind and placebo-controlled. The doses and number of steps used in DPT vary depending on the study, although doses usually escalate until the full therapeutic dose is achieved in 1 or 2 days [12,15,37,46,155]. Nevertheless, there are procedures with only 2 doses, ie, 1/10

and 9/10 of the full therapeutic doses in nonanaphylactic reactions [152]. In NIRs, full therapeutic doses are used for several days afterwards [152] (level of evidence, 2+; grade of recommendation, C) (Table 3). The duration of DPT protocols for NIRs is controversial, as reported for β -lactams. Prolonged DPT cycles at home yield higher negative predictive values than shorter ones [156-160], although with more adverse effects and a greater impact on health and costs related to disturbances of the intestinal microbiota in children [161] and risk of microbial resistance [162].

The procedure must be stopped when cutaneous and/or respiratory symptoms or changes in vital signs appear after a test dose. After evaluation, symptoms must be treated [2]. However, we have to take into account that in NIRs, symptoms may appear ≥ 24 hours after the initial dose [68,152]. In these cases, photographs and detailed descriptions are essential [152] for further evaluation by the allergist (level of evidence, 4; grade of recommendation, D).

The frequency of positive results in DPT in IRs depends on whether other tests have previously been carried out [163]. Therefore, DPT was shown to be positive in 32.8% of cases with a negative BAT result [15], in 35.3% of cases with a negative sIgE result [25], in 12% of patients with negative ST results [68], and in 27.3% of cases not previously assessed using other tests [163].

Cross-reactivity is detected in up to 50% of cases in DPT with alternative quinolones [36], with levofloxacin being the safest drug [46] (level of evidence, 2+; grade of recommendation, C), although published data are limited [152].

In many of the local reactions that occurred after intravenous administration, the drug was subsequently tolerated [12], suggesting a toxic/irritative mechanism or the implication of a mechanism involving mast cell degranulation via occupation of MRGPRX2, as can occur in other non-IgE-mediated reactions [33].

Patients with IgE-mediated reactions can lose sensitivity without re-exposure [140-142] (level of evidence, 2+; grade of recommendation C). Therefore, the interval between the

suspected HSR and the DPT can affect the outcome of the test. Evidence from a small number of studies [68,70,163] of patients with IRs to quinolones who underwent DPT with the culprit drug shows that most patients tolerated the drug upon re-exposure (level of evidence, 2-; grade of recommendation, C).

Cross-reactivity

Cross-reactivity between quinolones is controversial and remains unresolved [57]. Data from case reports and series based on few quinolones suggest that cross-reactivity is common, reaching 50% [12,37], while other studies focusing on larger series show it to be less frequent [46,117] (level of evidence, 3).

Cross-reactivity between quinolones seems to be related to the common molecular ring, which may act as the antigenic determinant [164]. In addition, changes at positions C-1, C-5, C-7, and C-8 that differ between quinolones may also affect cross-reactivity [46].

There are no general rules to predict cross-reactivity between quinolones, and different patterns of cross-reactivity have been reported for IRs and NIRs. The degree of cross-reactivity between quinolones differs with generation in IRs. A high degree of cross-reactivity has been reported between first-generation agents (nalidixic acid) and second-generation agents (norfloxacin, ciprofloxacin) [112], and a low degree of cross-reactivity has been seen with third-generation quinolones such as levofloxacin [46,165] and newer quinolones such as moxifloxacin [121,166] (level of evidence, 3), probably because of the different metabolites. Levofloxacin is the levogyre form of ofloxacin, which results in a specific cross-reactivity pattern [46] (level of evidence, 3). In vitro studies for IRs also suggest a high degree of cross-reactivity between fluoroquinolones [9,25] (level of evidence, 3).

sIgE to more than 1 quinolone was found in 63.6%-80% of cases when using radioimmunoassay and in 48.2% of cases when using BAT. While these percentages are high, we must remember that cross-reactivity demonstrated by in vitro testing can be overestimated, as only 16% of patients reported a reaction to more than 1 quinolone [9,25].

Different degrees of cross-reactivity are also found between quinolones of different generations in NIRs. Quinolones can interact with a wide variety of human T-cell receptors. Some are highly specific for a single compound, while others show marked cross-reactivity, which might be the basis for the cross-reactivity observed [167] (level of evidence, 3). The 3 different reactivity patterns (seen through 3 different T-cell clones) are clones reacting exclusively with the eliciting drug, clones with limited cross-reactivity, and clones with broad cross-reactivity [167]. In the case of photoallergic reactions, cross-reactivity between quinolones has been demonstrated in a murine model, which suggested the existence of a common epitope recognized by quinolone-specific T-cells [168].

HSRs to quinolones have also been associated with allergic reactions to NMBAs, as IgE against quaternary ammonium has been observed in 53% of patients with IRs to quinolones [27], although the in vivo relevance of these findings remains

unclear (level of evidence, 3). More studies are needed on cross-reactivity with these drugs and with others.

Management

The management of HSR to quinolones is based on discontinuation of the offending agent, initiation of an alternative agent, and supportive care (adrenaline, corticosteroids, antihistamines, fluid replacement, or short acting β -adrenergic agonists depending on the clinical severity of the manifestation) [57,169].

Patients must avoid quinolones when HSR is diagnosed, and alternative drugs must be offered (grade of recommendation, D). When therapeutic alternatives do not exist, it is important to assess cross-reactivity to other quinolones (grade of recommendation, D), especially in patients with a previous history of HSRs to antibiotics, for whom the number of therapeutic alternatives is decreased. Desensitization may be indicated when a specific quinolone is the only therapeutic option available (grade of recommendation, D). However, it is not possible to establish a standard protocol, as very few reports have been published. In 3 IRs induced by ciprofloxacin confirmed by DPT or ST, the drug was administered orally [170,171] and intravenously [172], with the full therapeutic dose reached in 4-6 hours. In 2 cases of NIRs induced by ciprofloxacin, the full dose was reached in 6 days [173], and a case of ciprofloxacin-induced FDE was managed using a 10-day protocol to achieve the total dose previously used for cotrimoxazole [174]. In another report, a levofloxacin-allergic patient underwent a 24-hour protocol for desensitization by continuous intravenous infusion [175]. More recently, a patient underwent rapid oral desensitization to moxifloxacin [176], eventually tolerating the drug for 4 months despite pruritus affecting the thighs and trunk, although this was controlled with oral antihistamines.

Algorithm

The recommended diagnostic algorithm is provided in Figure 2. After the clinical history has been taken, reactions compatible with HSRs can be classified as IRs or NIRs, depending on whether the interval between drug intake and the onset of the reaction is shorter or longer than 6 hours, respectively. If the reaction is not suggestive of HSR, DPT with the culprit drug is recommended; if it is suggestive of HSR, the first approach is to perform in vitro tests when available (BAT for IRs and LTT for NIRs). Despite the high specificity of sIgE to quinolones, we did not include this determination in the algorithm owing to the low sensitivity detected in the few reported articles and because it is not routinely performed in daily clinical practice. For IRs, SPTs should be performed with the wider battery of available quinolones, and readings should be taken 15-20 minutes after application. In the case of NIRs, delayed-reading IDTs and PTs should be carried out, except in SJS and TEN, in which delayed-reading IDT is contraindicated and PT can be considered if the diagnostic information obtained is beneficial. If the interval between drug intake and onset of

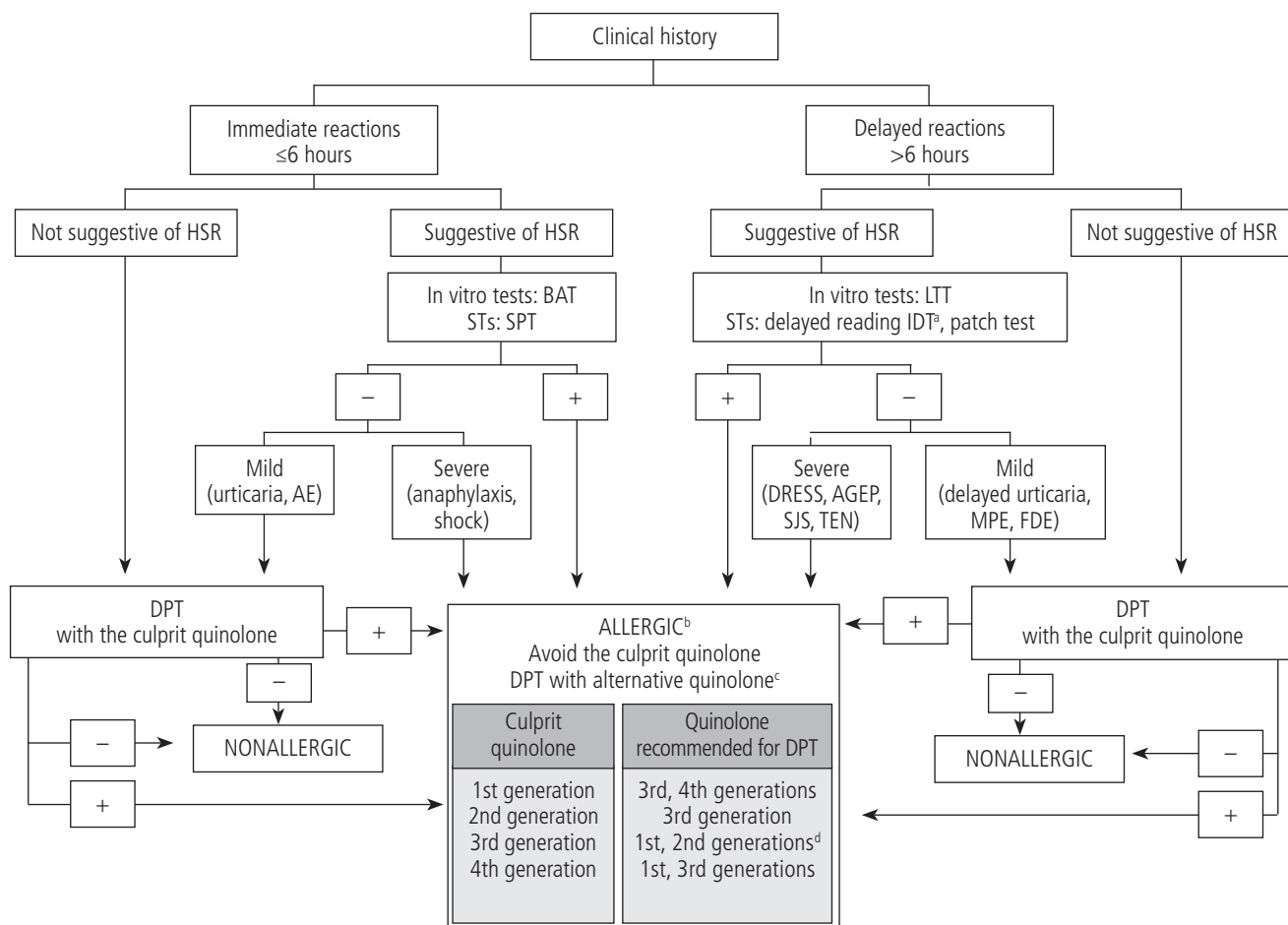


Figure 2. Diagnostic algorithm for diagnosis and management of HSRs to quinolones. Typically, immediate reactions occur within the first hour following the first administration of a new course of treatment, although in terms of pathophysiology, this interval can reach 6 hours after administration of the quinolone. AE indicates angioedema; AGEP, acute generalized exanthematous pustulosis; BAT, basophil activation test; DPT, drug provocation test; DRESS, drug reaction with eosinophilia and systemic symptoms syndrome; FDE, fixed drug eruption; HSR, hypersensitivity reaction; LTT, lymphocyte transformation test; MPE, maculopapular exanthema; SJS, Stevens-Johnson syndrome; SPT, skin prick test; TEN, toxic epidermal necrolysis.

^aContraindicated in SJS/TEN

^bIf culprit quinolone is required, desensitization may be indicated.

^cAfter analysis of the risk-benefit ratio.

^dExcept ofloxacin due to potential cross-reactivity with levofloxacin.

the reaction is not recorded, the symptoms may provide clues about the type of reaction: if the patient reports anaphylaxis/shock, the reaction may be considered to be an IR, whereas if the reported reaction is MPE/FDE/DRESS/AGEP or SJS/TEN, it may be considered to be an NIR. The case of urticaria is controversial. We suggest performing the tests recommended for both IRs and NIRs. In the case of negative ST and in vitro test results with the culprit quinolone, DPT can be performed after careful analysis of the potential risks and benefits. DPT is recommended with the culprit drug, except for severe and life-threatening reactions (anaphylaxis, shock, AGEP, DRESS, SJS, TEN). DPT with alternative quinolones is recommended in cases with a positive result in DPT with the culprit agents, if STs or in vitro tests are positive with the culprit quinolone, and in severe or life-threatening reactions (always after performing a risk-benefit analysis).

Desensitization may be considered when HSR is confirmed and the culprit quinolone is the only therapeutic option available.

Acknowledgments

We thank Professor María José Torres and Dr Cristobalina Mayorga for their in-depth review of our manuscript.

Funding

The authors declare that no funding was received for the present study.

Conflicts of Interest

The authors declare that they have no conflicts of interest.

References

- Harbour R, Miller J. A new system for grading recommendations in evidence based guidelines. *BMJ*. 2001;323:334-6.
- Dona I, Moreno E, Perez-Sanchez N, Andreu I, Hernandez Fernandez de Rojas D, et al., Update on Quinolone Allergy. *Curr Allergy Asthma Rep*. 2017;17(8):56.
- Corcoy M, Dursteler C, Arbones E, Comps O, Escolano F. [Intraoperative anaphylactic reaction after ciprofloxacin administration]. *Rev Esp Anesthesiol Reanim*. 1999;46(9):419-20.
- Solensky R, Earl HS, Gruchalla RS. Clinical approach to penicillin-allergic patients: a survey. *Ann Allergy Asthma Immunol*. 2000;84(3):329-33.
- Dona I, Torres MJ, Montanez MI, Fernandez TD. In Vitro Diagnostic Testing for Antibiotic Allergy. *Allergy Asthma Immunol Res*. 2017;9(4):288-98.
- Dona I, Blanca-Lopez N, Torres MJ, Garcia-Campos J, Garcia-Nunez I, Gomez F, et al. Drug hypersensitivity reactions: response patterns, drug involved, and temporal variations in a large series of patients. *J Investig Allergol Clin Immunol*. 2012;22(5):363-71.
- Lapi F, Tuccori M, Motola D, Pugi A, Vietri M, Montanaro N, et al. Safety profile of the fluoroquinolones: analysis of adverse drug reactions in relation to prescription data using four regional pharmacovigilance databases in Italy. *Drug Saf*. 2010;33(9):789-99.
- Ojeda P, Sastre J, Olaguibel JM, Chivato T, investigators participating in the National Survey of the Spanish Society of A, Clinical Immunology A. *Alergologica 2015: A National Survey on Allergic Diseases in the Adult Spanish Population*. *J Investig Allergol Clin Immunol*. 2018;28(3):151-64.
- Aranda A, Mayorga C, Ariza A, Doña I, Rosado A, Blanca-Lopez N, et al. In vitro evaluation of IgE-mediated hypersensitivity reactions to quinolones. *Allergy*. 2011; 66(2):247-54.
- Sachs B, Riegel S, Seebeck J, Beier R, Schichler D, Barger A, et al. Fluoroquinolone-associated anaphylaxis in spontaneous adverse drug reaction reports in Germany: differences in reporting rates between individual fluoroquinolones and occurrence after first-ever use. *Drug Saf*. 2006;29(11):1087-100.
- Chang B, Knowles SR, Weber E. Immediate hypersensitivity to moxifloxacin with tolerance to ciprofloxacin: report of three cases and review of the literature. *Ann Pharmacother*. 2010;44(4):740-5.
- Doña I, Perez-Sanchez N, Salas M, Barrionuevo E, Ruiz-San Francisco A, Hernandez Fernandez de Rojas D, et al. Clinical Characterization and Diagnostic Approaches for Patients Reporting Hypersensitivity Reactions to Quinolones. *J Allergy Clin Immunol Pract*. 2020; 8(8):2707-14 e2.
- Renaudin JM, Beaudouin E, Ponvert C, Demoly P, Moneret-Vautrin DA. Severe drug-induced anaphylaxis: analysis of 333 cases recorded by the Allergy Vigilance Network from 2002 to 2010. *Allergy*. 2013;68(7):929-37.
- Aberer W, Bircher A, Romano A, Blanca M, Campi P, Fernandez J, et al. Drug provocation testing in the diagnosis of drug hypersensitivity reactions: general considerations. *Allergy*. 2003;58(9):854-63.
- Blanca-Lopez N, Ariza A, Dona I, Mayorga C, Montanez MI, Garcia-Campos J, et al. Hypersensitivity reactions to fluoroquinolones: analysis of the factors involved. *Clin Exp Allergy*. 2013;43(5):560-7.
- Drlica K, Malik M. Fluoroquinolones: action and resistance. *Curr Top Med Chem*. 2003; 3(3):249-82.
- Drlica K, Malik M, Kerns RJ, Zhao X. Quinolone-mediated bacterial death. *Antimicrob Agents Chemother*. 2008;52(2):385-92.
- Leshner GY, Froelich EJ, Gruett MD, Bailey JH, Brundage RP. 1,8-Naphthyridine Derivatives. A New Class of Chemotherapeutic Agents. *J Med Pharm Chem*. 1962;91:1063-5.
- Sousa J, Alves G, Fortuna A, Falcao A. Third and fourth generation fluoroquinolone antibacterials: a systematic review of safety and toxicity profiles. *Curr Drug Saf*. 2014;9(2):89-105.
- Koga H, Itoh A, Murayama S, Suzue S, Irikura T. Structure-activity relationships of antibacterial 6,7- and 7,8-disubstituted 1-alkyl-1,4-dihydro-4-oxoquinoline-3-carboxylic acids. *J Med Chem*. 1980;23(12):1358-63.
- Mohammed HHH, Abuo-Rahma G, Abbas SH, Abdelhafez EMN. Current Trends and Future Directions of Fluoroquinolones. *Curr Med Chem*. 2019;26(17):3132-49.
- Dalhoff A, Schmitz FJ. In vitro antibacterial activity and pharmacodynamics of new quinolones. *Eur J Clin Microbiol Infect Dis*. 2003;22(4):203-21.
- Demoly P, Adkinson NF, Brockow K, Castells M, Chiriac AM, Greenberger PA, et al. International Consensus on drug allergy. *Allergy*. 2014;69(4):420-37.
- Jones SC, Budnitz DS, Sorbello A, Mehta H. US-based emergency department visits for fluoroquinolone-associated hypersensitivity reactions. *Pharmacoepidemiol Drug Saf*. 2013;22(10):1099-106.
- Manfredi M, Severino M, Testi S, Macchia D, Ermini G, Pichler WJ, et al. Detection of specific IgE to quinolones. *J Allergy Clin Immunol*. 2004;113(1):155-60.
- Baldo BA, Fisher MM, Pham NH. On the origin and specificity of antibodies to neuromuscular blocking (muscle relaxant) drugs: an immunochemical perspective. *Clin Exp Allergy*. 2009;39(3):325-44.
- Rouzaire P, Nosbaum A, Mullet C, Diot N, Dubost R, Bienvenu F, et al. Immediate allergic hypersensitivity to quinolones associates with neuromuscular blocking agent sensitization. *J Allergy Clin Immunol Pract*. 2013;1(3):273-9.
- McNeil BD, Pundir P, Meeker S, Han L, Udem BJ, Kulka M, et al. Identification of a mast-cell-specific receptor crucial for pseudo-allergic drug reactions. *Nature*. 2015;519(7542):237-41.
- Azimi E, Reddy VB, Shade KC, Anthony RM, Talbot S, Pereira PJS, et al. Dual action of neurokinin-1 antagonists on Mas-related GPCRs. *JCI Insight*. 2016;1(16):e89362.
- Lansu K, Karpiak J, Liu J, Huang XP, McCorry JD, Kroeze WK, et al. In silico design of novel probes for the atypical opioid receptor MRGPRX2. *Nat Chem Biol*. 2017;13(5):529-36.
- Spoerl D, D'Incau S, Roux-Lombard P, Harr T, Czarnetzki C. Non-IgE-Dependent Hypersensitivity to Rocuronium Reversed by Sugammadex: Report of Three Cases and Hypothesis on the Underlying Mechanism. *Int Arch Allergy Immunol*. 2016;169(4):256-62.
- Azimi E, Reddy VB, Lerner EA. Brief communication: MRGPRX2, atopic dermatitis and red man syndrome. *Itch (Phila)*. 2017;2(1):e5.

33. Van Gasse AL, Sabato V, Uyttebroek AP, Elst J, Faber MA, Hagendorens MM, et al. Immediate moxifloxacin hypersensitivity: Is there more than currently meets the eye? *Allergy*. 2017;72(12):2039-43.
34. Giavina-Bianchi P, Goncalves DG, Zanandrea A, Borges de Castro R, Garro LS, Kalil J, et al. Anaphylaxis to quinolones in mastocytosis: Hypothesis on the mechanism. *J Allergy Clin Immunol Pract*. 2019;7(6):2089-90.
35. Porebski G, Kwicien K, Pawica M, Kwitniewski M. Mas-Related G Protein-Coupled Receptor-X2 (MRGPRX2) in Drug Hypersensitivity Reactions. *Front Immunol*. 2018;9:3027.
36. Elst J, Sabato V, Faber MA, Bridts CH, Mertens C, Van Houdt M, et al. MRGPRX2 and Immediate Drug Hypersensitivity: Insights from Cultured Human Mast Cells. *J Investig Allergol Clin Immunol*, 2020:0. doi: 10.18176/jiaci.0557.
37. Demir S, Gelincik A, Akdeniz N, Aktas-Cetin E, Olgac M, Unal D, et al. Usefulness of In Vivo and In Vitro Diagnostic Tests in the Diagnosis of Hypersensitivity Reactions to Quinolones and in the Evaluation of Cross-Reactivity: A Comprehensive Study Including the Latest Quinolone Gemifloxacin. *Allergy Asthma Immunol Res*. 2017;9(4):347-59.
38. Empedrad R, Darter AL, Earl HS, Gruchalla RS. Nonirritating intradermal skin test concentrations for commonly prescribed antibiotics. *J Allergy Clin Immunol*. 2003; 112(3):629-30.
39. Broz P, Harr T, Hecking C, Grize L, Scherer K, Jaeger KA, et al. Nonirritant intradermal skin test concentrations of ciprofloxacin, clarithromycin, and rifampicin. *Allergy*. 2012;67(5):647-52.
40. Uyttebroek AP, Sabato V, Bridts CH, De Clerck LS, Ebo DG. Moxifloxacin hypersensitivity: Uselessness of skin testing. *J Allergy Clin Immunol Pract*. 2015;3(3):443-5.
41. Wedi B, Gehring M, Kapp A. The pseudoallergen receptor MRGPRX2 on peripheral blood basophils and eosinophils: Expression and function. *Allergy*. 2020;75(9):2229-42.
42. Mayorga C, Ebo DG, Lang DM, Pichler WJ, Sabato V, Park MA, et al., Controversies in drug allergy: In vitro testing. *J Allergy Clin Immunol*. 2019;143(1):56-65.
43. Fernandez TD, Ariza A, Palomares F, Montanez MI, Salas M, Martin-Serrano A, et al. Hypersensitivity to fluoroquinolones: The expression of basophil activation markers depends on the clinical entity and the culprit fluoroquinolone. *Medicine (Baltimore)*. 2016;95(23):e3679.
44. Mayorga C, Andreu I, Aranda A, Dona I, Montanez MI, Blanca-Lopez N, et al. Fluoroquinolone photodegradation influences specific basophil activation. *Int Arch Allergy Immunol*. 2013;160(4):377-82.
45. Rouzairé P, Nosbaum A, Denis L, Bienvenu F, Berard F, Cozon G, et al. Negativity of the basophil activation test in quinolone hypersensitivity: a breakthrough for provocation test decision-making. *Int Arch Allergy Immunol*. 2012;157(3):299-302.
46. Lobera T, Audicana MT, Alarcon E, Longo N, Navarro B, Munoz D. Allergy to quinolones: low cross-reactivity to levofloxacin. *J Investig Allergol Clin Immunol*. 2010;20(7):607-11.
47. Ben Said B, Berard F, Bienvenu J, Nicolas JF, Rozieres A. Usefulness of basophil activation tests for the diagnosis of IgE-mediated allergy to quinolones. *Allergy*. 2010;65(4):535-6.
48. Schnyder B, Mauri-Hellweg D, Zanni M, Bettens F, Pichler WJ. Direct, MHC-dependent presentation of the drug sulfamethoxazole to human alpha beta T cell clones. *J Clin Invest*. 1997;100(1):136-41.
49. Roujeau JC, Stern RS. Severe adverse cutaneous reactions to drugs. *N Engl J Med*. 1994;331(19):1272-85.
50. Fernandez-Rivas M. Fixed drug eruption (FDE) caused by norfloxacin. *Allergy*. 1997;52(4):477-8.
51. Alonso MD, Martin JA, Quirce S, Davila I, Lezaun A, Sanchez Cano M. Fixed eruption caused by ciprofloxacin with cross-sensitivity to norfloxacin. *Allergy*. 1993;48(4):296-7.
52. Pichler WJ. Delayed drug hypersensitivity reactions. *Ann Intern Med*. 2003;139(8):683-93.
53. von Greeyer S, Burkhart C, Pichler WJ. Molecular basis of drug recognition by specific T-cell receptors. *Int Arch Allergy Immunol*. 1999;119(3):173-80.
54. Zanni MP, von Greeyer S, Schnyder B, Brander KA, Frutig K, Hari Y, et al. HLA-restricted, processing- and metabolism-independent pathway of drug recognition by human alpha beta T lymphocytes. *J Clin Invest*. 1998;102(8):1591-8.
55. Pichler WJ. Pharmacological interaction of drugs with antigen-specific immune receptors: the p-i concept. *Curr Opin Allergy Clin Immunol*. 2002;2(4):301-5.
56. Kuyucu S, Mori F, Atanaskovic-Markovic M, Caubet JC, Terreehorst I, Gomes E, et al. Hypersensitivity reactions to non-beta lactam antibiotics in children: an extensive review. *Pediatr Allergy Immunol*. 2014;25(6):534-43.
57. McGee EU, Samuel E, Boronea B, Dillard N, Milby MN, Lewis SJ. Quinolone Allergy. *Pharmacy (Basel)*. 2019;7(3):97.
58. Salvo F, Polimeni G, Cutroneo PM, Leone R, Conforti A, Moretti U, et al. Allergic reactions to oral drugs: A case/non-case study from an Italian spontaneous reporting database (GIF). *Pharmacol Res*. 2008;58(3-4):202-7.
59. Gonzalez-Gregori R, Dolores Hernandez Fernandez De Rojas M, Lopez-Salgueiro R, Diaz-Palacios M, Garcia AN. Allergy alerts in electronic health records for hospitalized patients. *Ann Allergy Asthma Immunol*. 2012;109(2):137-40.
60. Neuman MG, Cohen LB, Nanau RM. Quinolones-induced hypersensitivity reactions. *Clin Biochem*. 2015;48(10-11):716-39.
61. Sidoroff A, Dunant A, Viboud C, Halevy S, Bavinck JN, Naldi L, et al. Risk factors for acute generalized exanthematous pustulosis (AGEP)-results of a multinational case-control study (EuroSCAR). *Br J Dermatol*. 2007;157(5):989-96.
62. Mockenhaupt M, Viboud C, Dunant A, Naldi L, Halevy S, Bouwes Bavinck JN, et al. Stevens-Johnson syndrome and toxic epidermal necrolysis: assessment of medication risks with emphasis on recently marketed drugs. The EuroSCAR-study. *J Invest Dermatol*. 2008;128(1):35-44.
63. Lagoudianakis E, Pappas A, Koronakis N, Dallianoudis I, Kotzadimitriou K, Chrysikos J, et al. Recurrent erythema multiforme after alcohol ingestion in a patient receiving ciprofloxacin: a case report. *Cases J*. 2009;2:7787.
64. Sullivan TJ RC, Ong MD., Gillian LK. Studies of the multiple drug allergy syndrome. *J Allergy Clin Immunol Pract*. 1989;83:270.
65. Almeida J, Ferreira S, Malheiro J, Fonseca P, Caeiro D, Dias A, et al. A rare cause of acute coronary syndrome: Kounis syndrome. *Rev Port Cardiol*. 2016;35(12):699 e1-699 e4.
66. Quercia O, Rafanelli S, Emiliani F, Stefanini GF. Anaphylactic reaction to cinoxacin: report of one case associated with inferior acute myocardial infarction. *Eur Ann Allergy Clin Immunol*. 2003;35(2):61-3.

67. Garcia Nunez I, Algaba Marmol MA, Barasona Villarejo MJ, Suarez Vergara M, Espinola Gonzalez F, Reina Ariza E. Kounis Syndrome After Levofloxacin Intake: A Clinical Report and Cross-reactivity Study. *J Investig Allergol Clin Immunol*. 2016;26(5):335-6.
68. Seitz CS, Bocker EB, Trautmann A. Diagnostic testing in suspected fluoroquinolone hypersensitivity. *Clin Exp Allergy*. 2009;39(11):1738-45.
69. Schmid DA, Depta JP, Pichler WJ. T cell-mediated hypersensitivity to quinolones: mechanisms and cross-reactivity. *Clin Exp Allergy*. 2006;36(1):59-69.
70. Venturini Diaz M, Lobera Labairu T, del Pozo Gil MD, Blasco Sarramian A, Gonzalez Mahave I. In vivo diagnostic tests in adverse reactions to quinolones. *J Investig Allergol Clin Immunol*. 2007;17(6):393-8.
71. Rodriguez-Morales A, Llamazares AA, Benito RP, Cocera CM. Fixed drug eruption from quinolones with a positive lesional patch test to ciprofloxacin. *Contact Dermatitis*. 2001;44(4):255.
72. Sanchez-Morillas L, Rojas Perez-Ezquerro P, Gonzalez Morales ML, Mayorga C, Gonzalez-Mendiola R, Laguna Martinez JJ. Fixed drug eruption due to norfloxacin and cross-reactivity with other quinolones. *Allergol Immunopathol (Madr)*. 2013;41(1):60-1.
73. Ponce Guevara LV, Yges EL, Gracia Bara MT, Gonzalez Ruiz AM, Rodilla EM. Fixed drug eruption due to amoxicillin and quinolones. *Ann Allergy Asthma Immunol*. 2013;110(1):61-2.
74. Hager JL, Mir MR, Hsu S. Fluoroquinolone-induced generalized fixed drug eruption. *Dermatol Online J*. 2009;15(12):8.
75. Foti C, Romita P, Zanframundo G, Mastrodonardo M, Angelini G, Calogiuri G, et al. Ciprofloxacin induced acute generalised exanthematous pustulosis. *Indian J Pharmacol*. 2017;49(1):119-120.
76. Patel TK, Barvaliya MJ, Sharma D, Tripathi C. A systematic review of the drug-induced Stevens-Johnson syndrome and toxic epidermal necrolysis in Indian population. *Indian J Dermatol Venereol Leprol*. 2013;79(3):389-98.
77. Tham TC, Allen G, Hayes D, McGrady B, Riddell JG. Possible association between toxic epidermal necrolysis and ciprofloxacin. *Lancet*. 1991;338(8765):522.
78. Jongen-Lavrencic M, Schneeberger PM, van der Hoeven JG. Ciprofloxacin-induced toxic epidermal necrolysis in a patient with systemic lupus erythematosus. *Infection*. 2003;31(6):428-9.
79. Hallgren J, Tengvall-Linder M, Persson M, Wahlgren CF. Stevens-Johnson syndrome associated with ciprofloxacin: a review of adverse cutaneous events reported in Sweden as associated with this drug. *J Am Acad Dermatol*. 2003;49(5 Suppl):S267-9.
80. Yerasi AB, Oertel MD. Ciprofloxacin-induced toxic epidermal necrolysis. *Ann Pharmacother*. 1996;30(3):297.
81. Uzun R, Yalcin AD, Celik B, Bulut T, Yalcin AN. Levofloxacin Induced Toxic Epidermal Necrolysis: Successful Therapy with Omalizumab (Anti-IgE) and Pulse Prednisolone. *Am J Case Rep*. 2016;17:666-71.
82. Varma SK, Sutradhar S, Misra AK. Levofloxacin and furazolidone induced toxic epidermal necrosis. *Indian J Pharmacol*. 2013;45(6):625-6.
83. Yoon SY, Bae YJ, Cho YS, Moon HB, Kim TB. Toxic epidermal necrolysis induced by ofloxacin. *Acta Derm Venereol*. 2010;90(5):550-1.
84. Howard-Thompson A, Cartmell B, Suda KJ. Toxic epidermal necrolysis reaction associated with the use of moxifloxacin. *Int J Antimicrob Agents*. 2014;44(2):178-9.
85. Matthews MR, Caruso DM, Phillips BJ, Csontos LG. Fulminant toxic epidermal necrolysis induced by trovafloxacin. *Arch Intern Med*. 1999;159(18):2225.
86. Scherer K, Bircher AJ. Hypersensitivity reactions to fluoroquinolones. *Curr Allergy Asthma Rep*. 2005;5(1):15-21.
87. Tokura Y. Quinolone photoallergy: photosensitivity dermatitis induced by systemic administration of photohaptenic drugs. *J Dermatol Sci*. 1998;18(1):1-10.
88. Vassileva SG, Mateev G, Parish LC. Antimicrobial photosensitive reactions. *Arch Intern Med*. 1998;158(18):1993-2000.
89. Reano M, Vives R, Rodriguez J, Daroca P, Canto G, Fernandez J. Ciprofloxacin-induced vasculitis. *Allergy*. 1997;52(5):599-600.
90. Pons R, Escutia B. [Ciprofloxacin-induced vasculitis with cutaneous and renal involvement]. *Nefrologia*. 2001;21(2):209-12.
91. Cozzani E, Chinazzo C, Burlando M, Romagnoli M, Parodi A. Ciprofloxacin as a Trigger for Bullous Pemphigoid: The Second Case in the Literature. *Am J Ther*. 2016;23(5):e1202-4.
92. Ma HJ, Hu R, Jia CY, Yang Y, Song LJ. Case of drug-induced bullous pemphigoid by levofloxacin. *J Dermatol*. 2012;39(12):1086-7.
93. Dan M, Aderka D, Topilsky M, Livni E, Levo Y. Hypersensitivity pneumonitis induced by nalidixic acid. *Arch Intern Med*. 1986;146(7):1423-4.
94. Steiger D, Bubendorf L, Oberholzer M, Tamm M, Leuppi JD. Ciprofloxacin-induced acute interstitial pneumonitis. *Eur Respir J*. 2004;23(1):172-4.
95. Lomaestro BM. Fluoroquinolone-induced renal failure. *Drug Saf*. 2000;22(6):479-85.
96. Muriithi AK, Leung N, Valeri AM, Cornell LD, Sethi S, Fidler ME, et al. Biopsy-proven acute interstitial nephritis, 1993-2011: a case series. *Am J Kidney Dis*. 2014;64(4):558-66.
97. Orman ES, Conjeevaram HS, Vuppalanchi R, Freston JW, Rochon J, Kleiner DE, et al. Clinical and histopathologic features of fluoroquinolone-induced liver injury. *Clin Gastroenterol Hepatol*. 2011;9(6):517-23.
98. Lucena MI, Andrade RJ, Rodrigo L, Salmeron J, Alvarez A, Lopez-Garrido MJ, et al. Trovafloxacin-induced acute hepatitis. *Clin Infect Dis*. 2000;30(2):400-1.
99. Bataille L, Rahier J, Geubel A. Delayed and prolonged cholestatic hepatitis with ductopenia after long-term ciprofloxacin therapy for Crohn's disease. *J Hepatol*. 2002;37(5):696-9.
100. Brockow K, Romano A, Blanca M, Ring J, Pichler W, Demoly P. General considerations for skin test procedures in the diagnosis of drug hypersensitivity. *Allergy*. 2002;57(1):45-51.
101. Demoly P, Kropf R, Bircher A, Pichler WJ. Drug hypersensitivity: questionnaire. EAACI interest group on drug hypersensitivity. *Allergy*. 1999;54(9):999-1003.
102. Sanz ML, Gamboa PM, Garcia-Figueroa BE, Ferrer M. In vitro diagnosis of anaphylaxis. *Chem Immunol Allergy*. 2010;95:125-40.
103. Mayorga C, Celik G, Rouzaire P, Whitaker P, Bonadonna P, Rodrigues-Cernadas J, et al. In vitro tests for drug hypersensitivity reactions: an ENDA/EAACI Drug Allergy Interest Group position paper. *Allergy*. 2016;71(8):1103-34.

104. Mertes PM, Laxenaire MC, Alla F, Groupe d'Etudes des Reactions Anaphylactoides P. Anaphylactic and anaphylactoid reactions occurring during anesthesia in France in 1999-2000. *Anesthesiology*. 2003;99(3):536-45.
105. Dybendal T, Guttormsen AB, Elsayed S, Askeland B, Harboe T, Florvaag E. Screening for mast cell tryptase and serum IgE antibodies in 18 patients with anaphylactic shock during general anaesthesia. *Acta Anaesthesiol Scand*. 2003;47(10):1211-8.
106. Valent P, Bonadonna P, Hartmann K, Broesby-Olsen S, Brockow K, Butterfield JH, et al. Why the 20% + 2 Tryptase Formula Is a Diagnostic Gold Standard for Severe Systemic Mast Cell Activation and Mast Cell Activation Syndrome. *Int Arch Allergy Immunol*. 2019;180(1):44-51.
107. Roujeau JC, Haddad C, Paulmann M, Mockenhaupt M. Management of nonimmediate hypersensitivity reactions to drugs. *Immunol Allergy Clin North Am*. 2014;34(3):473-87, vii.
108. Paulmann M, Mockenhaupt M. Severe drug-induced skin reactions: clinical features, diagnosis, etiology, and therapy. *J Dtsch Dermatol Ges*. 2015;13(7):625-45.
109. Mayorga C, Pena RR, Blanca-Lopez N, Lopez S, Martin E, Torres MJ. Monitoring the acute phase response in non-immediate allergic drug reactions. *Curr Opin Allergy Clin Immunol*. 2006;6(4):249-57.
110. Blanca M, Romano A, Torres MJ, Fernandez J, Mayorga C, Rodriguez J, et al. Update on the evaluation of hypersensitivity reactions to betalactams. *Allergy*. 2009;64(2):183-93.
111. Pichler WJ, Hausmann O. Classification of Drug Hypersensitivity into Allergic, p-i, and Pseudo-Allergic Forms. *Int Arch Allergy Immunol*. 2016;171(3-4):166-79.
112. Davila I, Díez ML, Quirce S, Fraj J, De La Hoz B, Lazaro M. Cross-reactivity between quinolones. Report of three cases. *Allergy*. 1993;48(5):388-90.
113. Gonzalez-Mancebo E, Cuevas M, Gonzalez Gonzalez E, Lara Catedra C, Dolores Alonso M. Simultaneous drug allergies. *Allergy*. 2002;57(10):963-4.
114. Liñana Santafé JJ, Muñoz Pamplona MP, Lanuza Rubio MD, Hernández MD, Giner Valero A, Basomba Riba A. Reacciones adversas por quinolonas: estudio de 23 casos. *Rev Esp Alergol Inmunol Clin*. 1997;12(Suppl 6):66.
115. Lizarza S AE, Álvarez-Fernández JA, Gala G, Díez ML. Hipersensibilidad a quinolonas. *Rev Esp Alergol Inmunol Clin*. 1997;12(Suppl 2):67.
116. Scala E, Giani M, Pirrotta L, Guerra EC, De Pita O, Puddu P. Multiple drug allergy syndrome: severe anaphylactic reaction due to topical rifamycin SV in a patient with hypersensitivity to ciprofloxacin. *Int J Dermatol*. 2001;40(9):603-4.
117. Gonzalez-Mancebo E, Fernandez-Rivas M. Immediate hypersensitivity to levofloxacin diagnosed through skin prick test. *Ann Pharmacother*. 2004;38(2):354.
118. García MM, Pineda F, Varela S, Menéndez M, González C. Alergia a quinolonas. Caso clínico. *Rev Esp Alergol Inmunol Clin*. 2004;19(Extr. 2):360.
119. Ferrer Franco A, Bruno Carlos K, Uixera Marzal S, Doménech Witeck J, Lanuza Rubio MD, Gutiérrez Vall de Cabres V. Obstrucción al flujo aéreo inducida por moxifloxacin oral. *Rev Esp Alergol Inmunol Clin*. 2004;19(Extr. 2):389.
120. Fukushima K, Nakatsubo M, Noda M, Uenami T, Hayama Y, Tsuruta N, et al. Anaphylaxis due to intravenous levofloxacin with tolerance to garenoxacin. *Intern Med*. 2012;51(13):1769-72.
121. Gonzalez I, Lobera T, Blasco A, del Pozo MD. Immediate hypersensitivity to quinolones: moxifloxacin cross-reactivity. *J Investig Allergol Clin Immunol*. 2005;15(2):146-9.
122. Lobera Labairu T, Blasco Sarramián A, González Mahave I. In Vivo Diagnostic Tests in Quinolone Adverse Reactions. *Allergy*. 2005;1(Suppl 1):164.
123. Perez E, Callero A, Martínez-Tadeo JA, Hernandez G, Rodriguez-Plata E, Almeida Z, et al. Are skin tests useful in fluoroquinolone hypersensitivity diagnosis? *Ann Allergy Asthma Immunol*. 2013;111(5):423-5.
124. Baldo BA, Pham NH, Zhao Z. Chemistry of drug allergenicity. *Curr Opin Allergy Clin Immunol*. 2001;1(4):327-35.
125. Silvestre JF, Alfonso R, Moragon M, Ramon R, Botella R. Systemic contact dermatitis due to norfloxacin with a positive patch test to quinoline mix. *Contact Dermatitis*. 1998;39(2):83.
126. Charfi O, Lakhoua G, Sahnoun R, Badri T, Daghfous R, El Aidli S, et al. DRESS Syndrome Following Levofloxacin Exposure With Positive Patch-test. *Therapie*. 2015;70(6):547-9.
127. Holzle E, Neumann N, Hausen B, Przybilla B, Schauder S, Honigsmann H, et al. Photopatch testing: the 5-year experience of the German, Austrian, and Swiss Photopatch Test Group. *J Am Acad Dermatol*. 1991;25(1 Pt 1):59-68.
128. Izu R, Gardeazabal J, Gonzalez M, Landa N, Raton JA, Diaz-Perez JL. Enoxacin-induced photosensitivity: study of two cases. *Photodermatol Photoimmunol Photomed*. 1992;9(2):86-8.
129. Oliveira HS, Goncalo M, Figueiredo AC. Photosensitivity to lomefloxacin. A clinical and photobiological study. *Photodermatol Photoimmunol Photomed*. 2000;16(3):116-20.
130. Kurumaji Y, Shono M. Scarified photopatch testing in lomefloxacin photosensitivity. *Contact Dermatitis*. 1992;26(1):5-10.
131. Kimura M, Kawada A. Photosensitivity induced by lomefloxacin with cross-photosensitivity to ciprofloxacin and fleroxacin. *Contact Dermatitis*. 1998;38(3):180.
132. Kawada A, Hiruma M, Noguchi H, Banba K, Ishibashi A, Banba H, et al. Fixed drug eruption induced by ofloxacin. *Contact Dermatitis*. 1996;34(6):427.
133. Ben Fredj N, Aouam K, Chaabane A, Braham D, Boughattas NA. Fixed drug eruption: levofloxacin, another culprit drug. *J Clin Pharmacol*. 2012;52(5):775-7.
134. Chivato T SI, Laguna R. Exantema fijo medicamentoso por ciprofloxacin. *Rev Esp Alergol Inmunol Clin*. 1997;12(Extr. 2):112.
135. Lozano Ayllon M, Gomez Martinez M, Mosquera MR, Laguna Martinez JJ, Orta Martiartu M, Fernandez de Miguel C. Fixed eruption caused by ciprofloxacin without cross-sensitivity to norfloxacin. *Allergy*. 1995;50(7):598-9.
136. Kawada A, Hiruma M, Morimoto K, Ishibashi A, Banba H. Fixed drug eruption induced by ciprofloxacin followed by ofloxacin. *Contact Dermatitis*. 1994;31(3):182-3.
137. Miyake M, Oiso N, Yoshinaga E, Kawada A. Fixed drug eruption due to garenoxacin mesilate hydrate. *Eur J Dermatol*. 2013;23(1):111-2.

138. Phillips EJ, Bigliardi P, Bircher AJ, Broyles A, Chang YS, Chung WH, et al. Controversies in drug allergy: Testing for delayed reactions. *J Allergy Clin Immunol*. 2019;143(1):66-73.
139. Decuyper, II, Mangodt EA, Van Gasse AL, Claesen K, Uyttebroeck A, Faber M, et al. In Vitro Diagnosis of Immediate Drug Hypersensitivity Anno 2017: Potentials and Limitations. *Drugs R D*. 2017;17(2):265-78.
140. Fernandez TD, Torres MJ, Blanca-Lopez N, Rodriguez-Bada JL, Gomez E, Canto G, et al. Negativization rates of IgE radioimmunoassay and basophil activation test in immediate reactions to penicillins. *Allergy*. 2009;64(2):242-8.
141. Gomez E, Blanca-Lopez N, Torres MJ, Requena G, Rondon C, Canto G, et al. Immunoglobulin E-mediated immediate allergic reactions to dipyrone: value of basophil activation test in the identification of patients. *Clin Exp Allergy*. 2009;39(8):1217-24.
142. Kvedariene V, Kamey S, Ryckwaert Y, Rongier M, Bousquet J, Demoly P, et al. Diagnosis of neuromuscular blocking agent hypersensitivity reactions using cytofluorimetric analysis of basophils. *Allergy*. 2006;61(3):311-5.
143. Buhning HJ, Streble A, Valent P. The basophil-specific ectoenzyme E-NPP3 (CD203c) as a marker for cell activation and allergy diagnosis. *Int Arch Allergy Immunol*. 2004;133(4):317-29.
144. MacGlashan D, Jr. Expression of CD203c and CD63 in human basophils: relationship to differential regulation of piecemeal and anaphylactic degranulation processes. *Clin Exp Allergy*. 2010;40(9):1365-77.
145. MacGlashan D, Jr. Marked differences in the signaling requirements for expression of CD203c and CD11b versus CD63 expression and histamine release in human basophils. *Int Arch Allergy Immunol*. 2012;159(3):243-52.
146. Miura K, MacGlashan DW. Phosphatidylinositol-3 kinase regulates p21ras activation during IgE-mediated stimulation of human basophils. *Blood*. 2000;96(6):2199-205.
147. Olivera A, Beaven MA, Metcalfe DD. Mast cells signal their importance in health and disease. *J Allergy Clin Immunol*. 2018;142(2):381-93.
148. Campi P, Pichler WJ. Quinolone hypersensitivity. *Curr Opin Allergy Clin Immunol*. 2003;3(4):275-81.
149. Lucena MI, Andrade RJ, Sanchez-Martinez H, Perez-Serrano JM, Gomez-Outes A. Norfloxacin-induced cholestatic jaundice. *Am J Gastroenterol*. 1998;93(11):2309-11.
150. Polak ME, Belgi G, McGuire C, Pickard C, Healy E, Friedmann PS, et al. In vitro diagnostic assays are effective during the acute phase of delayed-type drug hypersensitivity reactions. *Br J Dermatol*. 2013;168(3):539-49.
151. Tokura Y, Seo N, Ohshima A, Yagi H, Furukawa F, Takigawa M. Lymphocyte stimulation test with drug-photomodified cells in patients with quinolone photosensitivity. *J Dermatol Sci*. 1999;21(1):34-41.
152. Solensky R. Hypersensitivity reactions to fluoroquinolones. In: *UpToDate*, Post TW (Ed), *UpToDate*, Waltham, MA (Accessed on April 29, 2018).
153. Executive summary of disease management of drug hypersensitivity: a practice parameter. Joint Task Force on Practice Parameters tAAoA, Asthma and Immunology, the American Academy of Allergy, Asthma and Immunology, and the Joint Council of Allergy, Asthma and Immunology. *Ann Allergy Asthma Immunol*. 1999;83(6 Pt 3):665-700.
154. Wolkenstein P, Revuz J. Drug-induced severe skin reactions. Incidence, management and prevention. *Drug Saf*. 1995;13(1):56-68.
155. Ball P. Quinolone generations: natural history or natural selection? *J Antimicrob Chemother*. 2000;46 Suppl T1:17-24.
156. Van Gasse AL, Ebo DG, Chiriach AM, Hagendorens MM, Faber MA, Coenen S, et al. The Limited Value of Prolonged Drug Challenges in Nonimmediate Amoxicillin (Clavulanic Acid) Hypersensitivity. *J Allergy Clin Immunol Pract*. 2019;7(7):2225-9.
157. Labrosse R, Paradis L, Lacombe-Barrios J, Samaan K, Graham F, Paradis J, et al. Efficacy and Safety of 5-Day Challenge for the Evaluation of Nonsevere Amoxicillin Allergy in Children. *J Allergy Clin Immunol Pract*. 2018;6(5):1673-80.
158. Mori F, Cianferoni A, Barni S, Pucci N, Rossi ME, Novembre E. Amoxicillin allergy in children: five-day drug provocation test in the diagnosis of nonimmediate reactions. *J Allergy Clin Immunol Pract*. 2015;3(3):375-80.
159. Hjortlund J, Mortz CG, Skov PS, Bindslev-Jensen C. Diagnosis of penicillin allergy revisited: the value of case history, skin testing, specific IgE and prolonged challenge. *Allergy*. 2013;68(8):1057-64.
160. Confino-Cohen R, Rosman Y, Meir-Shafir K, Stauber T, Lachover-Roth I, Hershko A, et al. Oral Challenge without Skin Testing Safely Excludes Clinically Significant Delayed-Onset Penicillin Hypersensitivity. *J Allergy Clin Immunol Pract*. 2017;5(3):669-75.
161. Brunser O, Gotteland M, Cruchet S, Figueroa G, Garrido D, Steenhout P. Effect of a milk formula with prebiotics on the intestinal microbiota of infants after an antibiotic treatment. *Pediatr Res*. 2006;59(3):451-6.
162. Gibson MK, Crofts TS, Dantas G. Antibiotics and the developing infant gut microbiota and resistome. *Curr Opin Microbiol*. 2015;27:51-6.
163. Messaad D, Sahla H, Benahmed S, Godard P, Bousquet J, Demoly P. Drug provocation tests in patients with a history suggesting an immediate drug hypersensitivity reaction. *Ann Intern Med*. 2004;140(12):1001-6.
164. Nishijima S, Nakagawa M. Fixed drug eruption caused by tosylloxacin tosylate. *J Int Med Res*. 1997;25(6):359-63.
165. Blanca-Lopez N, Andreu I, Torres Jaen MJ. Hypersensitivity reactions to quinolones. *Curr Opin Allergy Clin Immunol*. 2011;11(4):285-91.
166. Sanchez-Morillas L, Rojas Perez-Ezquerria P, Reano-Martos M, Laguna-Martinez JJ, Gomez-Tembleque P. Systemic anaphylaxis caused by moxifloxacin. *Allergol Immunopathol (Madr)*. 2010;38(4):226-7.
167. Schmid DA, Campi P, Pichler WJ. Hypersensitivity reactions to quinolones. *Curr Pharm Des*. 2006;12(26):3313-26.
168. Tokura Y, Seo N, Yagi H, Furukawa F, Takigawa M. Cross-reactivity in murine fluoroquinolone photoallergy: exclusive usage of TCR Vbeta13 by immune T cells that recognize fluoroquinolone-photomodified cells. *J Immunol*. 1998;160(8):3719-28.
169. Moghaddam S, Connolly D. Photo-induced Stevens-Johnson syndrome. *J Am Acad Dermatol*. 2014;71(3):e82-3.
170. Lantner RR. Ciprofloxacin desensitization in a patient with cystic fibrosis. *J Allergy Clin Immunol*. 1995;96(6 Pt 1):1001-2.

171. Gea-Banacloche JC, Metcalfe DD. Ciprofloxacin desensitization. *J Allergy Clin Immunol*. 1996;97(6):1426-7.
172. Erdem G, Staat MA, Connelly BL, Assa'ad A. Anaphylactic reaction to ciprofloxacin in a toddler: successful desensitization. *Pediatr Infect Dis J*. 1999;18(6):563-4.
173. Bircher AJ, Rutishauser M. Oral "desensitization" of maculopapular exanthema from ciprofloxacin. *Allergy*. 1997;52(12):1246-8.
174. Garcia Rodriguez R, Galindo Bonilla PA, Feo Brito FJ, Gomez Torrijos E, Borja Segade J, Lara de la Rosa P, et al. Chronic desensitization to quinolones in fixed drug eruption. *J Investig Allergol Clin Immunol*. 2011;21(1):76-7.
175. Nelson MR, Loesevitz AW, Engler RGM. Emergent levofloxacin desensitization in acute myelogenous leukemia. *J Allergy Clin Immunol*. 2001;107(2):S331.
176. Benken ST, Nyenhuis SM, Dunne S. Sequential rapid oral desensitization to rifampin and moxifloxacin for the treatment of active mycobacterium tuberculosis. *J Allergy Clin Immunol Pract*. 2017;5(1):195-7.

■ *Manuscript received July 5, 2020; accepted for publication January 13, 2021.*

■ **Inmaculada Doña Díaz**

Allergy Unit, pabellón 6, primera planta
Hospital Regional Universitario de Málaga (Pabellon C)
Plaza del Hospital Civil
29009 Malaga, Spain
E-mail: inmadd@hotmail.com