
Unusual Secretion of Eosinophil Mediators Induced by Benralizumab

Cañas JA^{1,2,*}, Valverde-Monge M^{3,*}, Rodríguez-Nieto MJ⁴, González-Mangado N^{2,4}, Sastre J^{2,3}, del Pozo V^{1,2}

¹*Immunology Department, Instituto de Investigación Sanitaria (IIS) Fundación Jiménez Díaz, Madrid, Spain*

²*CIBER de Enfermedades Respiratorias (CIBERES), Madrid, Spain*

³*Allergy Unit, Hospital Universitario Fundación Jiménez Díaz, Madrid, Spain*

⁴*Pneumology Unit, Hospital Universitario Fundación Jiménez Díaz, Madrid, Spain*

**Both authors contributed equally to this work.*

J Investig Allergol Clin Immunol 2021; Vol. 31(6): 513-515
doi: 10.18176/jiaci.0684

Key words: Benralizumab. Eosinophils. Eosinophil cationic protein. Major basic protein. Cytokines.

Palabras clave: Benralizumab. Eosinófilos. Proteína catiónica eosinofílica. Proteína básica mayor. Citoquinas.

Asthma affects 5%-10% of the world's population. It is estimated that 40%-60% of asthmatics have eosinophilic airway inflammation, which is associated with severe eosinophilic asthma, thus increasing the risk of severe exacerbations, worsening of symptoms, and poor control [1]. Eosinophils, which contain cytotoxic granule proteins, including major basic protein (MBP) and eosinophil cationic protein (ECP), play a key role in asthma.

Various strategies are available for maintenance therapy in patients with asthma. Benralizumab is indicated as additional maintenance treatment in adult patients with severe uncontrolled eosinophilic asthma despite administration of high doses of inhaled corticosteroids and long-acting β_2 -agonists [2]. Benralizumab is a humanized IgG1 κ , afucosylated, monoclonal antibody that binds to IL-5 receptor α on the surface of human eosinophils and basophils [3]. It induces rapid and complete depletion of blood eosinophils through antibody-dependent cell-mediated cytotoxicity; the number of exacerbations is reduced and lung function improved in patients with severe asthma. Indeed, eosinophil apoptosis is induced by proapoptotic proteins, thus avoiding eosinophil degranulation and secretion of granule proteins.

Previous studies have shown adverse reactions to benralizumab, such as headaches and pharyngitis, and, less frequently, hypersensitivity reactions, mainly in the form of immediate reactions (appearing within the first 2 hours after administration) [4].

Here, we report the case of a patient who experienced a reaction to benralizumab caused by unusual secretion of eosinophil mediators immediately after the first dose. The patient was a 51-year-old woman diagnosed with severe eosinophilic asthma in 1996 who had at least 4 exacerbations

per year. Her asthma has been controlled since 2006 (baseline spirometry revealed an FEV₁/FVC ratio of 69% and a positive bronchodilator test result of 18% of FEV₁). Findings from 4 chest radiographs were normal. Determination of antineutrophil cytoplasmic antibodies and antimyeloperoxidase has repeatedly yielded negative results. She is not obese, and diffusion and plethysmography test results were normal. Initiated in 2016, treatment with omalizumab had not improved asthma control, persistent obstruction (FEV₁/FVC <70%), or low FEV₁ (<70%). Other diagnoses were ruled out following the recommendations of the Global Initiative for Asthma (GINA) [5]. On the day that she received her first dose of benralizumab, she reported no flu-like symptoms and was negative for SARS-CoV-2. Her vital signs were the following: heart rate, 90 bpm; blood pressure (BP), 115/78 mmHg; and peripheral O₂, 94%. One hour after administration, she developed chills, nausea, myalgia, and general discomfort with a heart rate, 112 bpm; body temperature, 37.4°C; and BP, 136/96 mmHg. Paracetamol 1 g was administered orally. She remained in observation for the following 3 hours, with fever (38.6°C) and tachycardia; BP and O₂ remained stable. The patient was discharged 4 hours later; all symptoms had resolved, and vital signs had improved (body temperature, 37.80°C; heart rate, 104 bpm; BP, 109/63 mmHg; and peripheral O₂, 94%). Successive benralizumab doses were well tolerated. She experienced no subsequent reactions to benralizumab or its components. In addition, the low peripheral eosinophil count suggests no further secretion of eosinophil products.

We studied the causes of the reaction induced by benralizumab using ELISA to evaluate cytokines (IL-10, IL-33, transforming growth factor- β 1 [TGF- β 1], thymic stromal lymphopoietin [TSLP], and periostin) and eosinophil granule proteins (ECP and MBP) in serum before and after benralizumab injection. Hematological and biochemical parameters were also evaluated immediately before administration of benralizumab and 2 hours after injection (Supplementary Table 1). Fully detailed methods can be consulted in the Supplementary Material. The study followed the guidelines set by the Declaration of Helsinki and was approved by the local ethics committee. The patient was properly advised in writing and provided her signed informed consent.

Laboratory data collected before the first benralizumab dose showed high values for leukocytes, eosinophils, and total IgE (Supplementary Table 1). Two hours later, peripheral blood eosinophils and the remaining white blood cells decreased dramatically, and total serum IgE increased (Supplementary Table 1), as reported in other hypereosinophilic syndromes treated with benralizumab [6]. Tryptase, B-factor, and complement proteins were normal before and after administration, except for C2, which reached values higher than the normal range (Supplementary Table 1).

As for cytokines and eosinophil-derived mediators in serum, we observed that ECP and MBP were increased more than 2-fold after administration of benralizumab (36.23 [6.55] vs 86.16 [17.94] ng/mL and 34.06 [7.60] vs 77.80 [14.97]) (Figure). Similarly, IL-10 was higher after injection (undetectable vs 0.11 ng/mL, Figure). In contrast, we observed

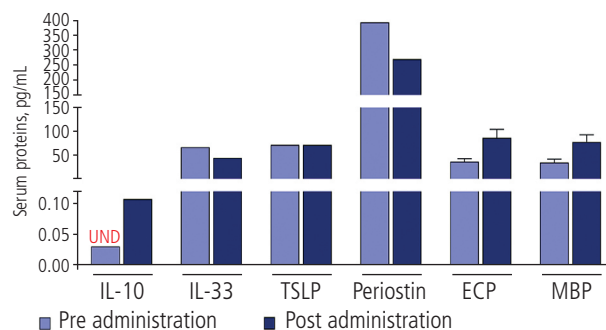


Figure. Serum protein before and after administration of benralizumab. Eosinophil-derived proteins (ECP and MBP) were augmented in serum after administration, as was IL-10. Other cytokine values decreased (IL-33, periostin) or remained unchanged (TSLP) in serum. The protein concentration was determined by ELISA. ECP indicates eosinophil cationic protein; IL, interleukin; MBP, major basic protein; TSLP, thymic stromal lymphopoietin; UND, undetectable.

a reduction in the serum periostin concentration (392.47 vs 270.09 ng/mL) (Figure) and a slight decrease in IL-33 levels (66.73 vs 44.38 ng/mL, Figure) after administration of benralizumab. The remaining cytokine values did not change (TSLP, Figure) or were undetectable (TGF- β 1, data not shown).

According to the literature and the abnormally high values of peripheral blood eosinophils, the patient's symptoms could be produced by the adverse effects (AEs) of drug administration, which are also found in hypereosinophilic conditions treated with benralizumab [6]. In a recent clinical phase 2 trial by Kuang et al [6], which included symptomatic adults with platelet-derived growth factor receptor α -negative hypereosinophilic syndrome, the authors reported several AEs, including fever, chills, headache, nausea, and fatigue, approximately 6 hours after the first dose of benralizumab, but not in subsequent doses [6], as in the case we report.

Although benralizumab is beneficial and safe for uncontrolled severe eosinophilic asthma [7], there are still many unanswered questions regarding AEs in patients with rare diseases after long-term therapy. Indeed, some studies have described AEs during treatment with benralizumab in eosinophilic asthma. For example, in 2019, Liu et al [9] performed a systematic review of all studies that reported AEs associated with benralizumab in severe asthmatics [8].

Based on the literature regarding AEs with benralizumab, we believe this could be caused by lysis of eosinophils, probably resulting from degranulation of eosinophils and secretion of eosinophil cationic proteins. In addition, the number of apoptotic eosinophils may have been extremely high, and secondary necrosis could have occurred because of limited phagocytic capacity. With respect to the pharmacodynamics of benralizumab, the European Medicines Agency has reported the rapid, near complete depletion of blood eosinophils by cell apoptosis not associated with the increase in ECP and eosinophil-derived neurotoxin [9]. Indeed, there is no evidence that benralizumab could induce activation of eosinophils. Nevertheless, we observed an unexpected increase in ECP and MBP in serum 2 hours after administration. The increased serum values of these cytotoxic proteins is a marker of

eosinophil activation and degranulation, which are associated with inflammatory processes [10]. Likewise, IL-10 has been reported to be an eosinophilic secretory product [11].

In summary, we report the case of a patient with an immediate adverse reaction to benralizumab that suggests secretion of eosinophil mediators. Although benralizumab sometimes causes AEs and does not induce activation of eosinophils, the most probable cause of the clinical features observed was degranulation of eosinophils with secretion of eosinophil-derived proteins..

Funding

This work was supported by the following: Fondo de Investigación Sanitaria (FIS) (grant number: PI18/00044); Ciber de Enfermedades Respiratorias (CIBERES); Ministerio de Ciencia, Innovación y Universidades (grant number: RTC-2017-6501-1); and FEDER funds (Fondo Manuscript Europeo de Desarrollo Regional).

Conflicts of Interest

JS reports the following: having served as a consultant to ThermoFisher, MEDA, Novartis, Sanofi, Leti, Faes Farma, Mundipharma, and GSK; having been paid lecture fees by Novartis, GSK, Stallergenes, Leti, and Faes Farma; and having received grant support for research from ThermoFisher, Sanofi, and ALK. MJRN reports receiving a grant support for research from Astra Zeneca and GSK, serving as a consultant to Astra Zeneca and GSK, and receiving payments for lectures by Astra Zeneca and GSK. VdP reports having served as a consultant to Astra Zeneca and GSK and having been paid lectures fees by Astra Zeneca and GSK. JAC has been paid for lecture by Astra Zeneca. The remaining authors declare that they have no conflicts of interest.

References

1. Rehman A, Amin F, Sadeeqa S. Prevalence of asthma and its management: A review. *J Pak Med Assoc.* 2018;68:1823-7.
2. GEMA 5.0, la nueva guía española para el manejo del asma. Barcelona: Sociedad Española de Neumología y Cirugía Torácica (SEPAR);2020. Available at: <https://www.separ.es/node/1812>. Accessed January 7, 2021.
3. Izumo T, Tone M, Kuse N, Awano N, Tanaka A, Jo T, et al. Effectiveness and safety of benralizumab for severe asthma in clinical practice (J-BEST): a prospective study. *Ann Transl Med.* 2020;8:438.
4. Benralizumab (fasenra) for severe eosinophilic asthma. *JAMA.* 2018;319:1501-2.
5. Global Initiative for Asthma. Global Strategy for Asthma Management and Prevention. Available online: www.ginasthma.org. Accessed January 31, 2020.
6. Kuang FL, Legrand F, Makiya M, Ware J, Wetzler L, Brown T, et al. Benralizumab for PDGFRA-Negative Hypereosinophilic Syndrome. *N Engl J Med.* 2019;380:1336-46.
7. Busse WW, Bleecker ER, FitzGerald JM, Ferguson GT, Barker P, Sproule S, et al. Long-term safety and efficacy of benralizumab in patients with severe, uncontrolled asthma: 1-year results from the BORA phase 3 extension trial. *Lancet Respir Med.* 2019;7:46-59.
8. Liu W, Ma X, Zhou W. Adverse events of benralizumab in moderate to severe eosinophilic asthma: A meta-analysis. *Medicine (Baltimore).* 2019;98:e15868.
9. Assessment report, fasenra. Amsterdam: Committee for Medicinal Products for Human Use; 2017. Available at: https://www.ema.europa.eu/en/documents/assessment-report/fasenra-epar-public-assessment-report_en.pdf. Accessed September 25, 2020.
10. Gleich GJ. Mechanisms of eosinophil-associated inflammation. *J Allergy Clin Immunol.* 2000;105:651-63.
11. Melo RCN, Weller PF. Piecemeal degranulation in human eosinophils: A distinct secretion mechanism underlying inflammatory responses. *Histol Histopathol.* 2010;25:1341-54.

■ Manuscript received November 18, 2020; accepted for publication March 1, 2021.

Victoria del Pozo

Immunology Department
IIS-Fundación Jiménez Díaz
Avenida Reyes Católicos, 2
28040 Madrid, Spain
E-mail: vpozo@fjd.es