

---

### Salt-Dependent Aquagenic Urticaria, Challenge Test, and Histological Features: Case Report

---

Laiseca García J<sup>1</sup>, González Bravo L<sup>1</sup>, Gomez de la Fuente E<sup>2</sup>, Tristán Martín B<sup>3</sup>, Sarró Fuentes C<sup>2</sup>, Rosado A<sup>1</sup>

<sup>1</sup>Allergy Unit, Hospital Universitario Fundación Alcorcón, Alcorcón, Madrid, Spain

<sup>2</sup>Dermatology Unit, Hospital Universitario Fundación Alcorcón, Alcorcón, Madrid, Spain

<sup>3</sup>Pathology Department, Hospital Universitario Fundación Alcorcón, Alcorcón, Madrid, Spain

---

J Investig Allergol Clin Immunol 2022; Vol. 32(3): 230-231

doi: 10.18176/jiaci.0735

---

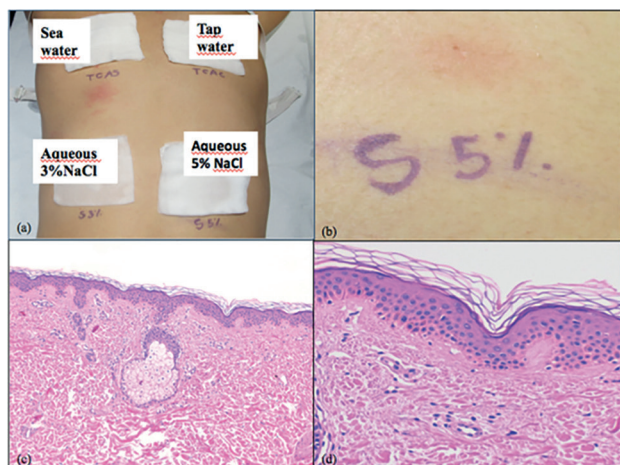
**Key words:** Salt-dependent aquagenic urticaria. Histological features. Water challenge test. Biopsy. Pathophysiology.

**Palabras clave:** Urticaria acuagénica dependiente de sal. Características histológicas. Test de exposición con agua. Biopsia. Fisiopatología.

---

Aquagenic urticaria is an uncommon but well-documented type of physical urticaria that mainly affects young women. Salt-dependent aquagenic urticaria (SDAU) is a particular subtype of aquagenic urticaria characterized by very small and itchy wheals commonly located on areas where saltwater contacts the skin. It occurs immediately or within a few minutes of contact with salt water and is not related to other factors such as sunlight, heat, or cold [1]. The underlying pathogenic mechanisms of SDAU are not clearly understood, and although the pathologic features of aquagenic urticaria have been described, microscopic data have not yet been reported for SDAU [2]. We hypothesized that histopathology data could help to better characterize this subtype of urticaria.

We report the case of a 34-year-old woman, with a past medical history of seasonal rhinitis and asthma who complained of pruritic, erythematous wheals distributed on the neck, nape, face, neckline, back, and arms a few minutes after swimming in the sea. These episodes were not reported with freshwater, swimming pool water, and rainwater, and were not associated with temperature. Systemic symptoms were not documented. Symptoms were replicated using challenge tests performed on the patient's back with sterile gauzes soaked in seawater (brought by the patient from her vacation place), saline solution at different concentrations (3% and 5%), and hypertonic glucose 10 g/20 mL (50% concentration, 2770 mOsm/L). Testing revealed a well-defined urticarial response consisting of very small and pruritic hives in the region that came into contact with seawater and with saline solution at both concentrations; in contrast, this phenomenon was not seen on the skin after contact with tap water or hypertonic glucose. A control test using a gauze soaked in tap water was negative. Dermographism was observed. Biopsy of a wheal on the posterior part of the thorax after the challenge test revealed a superficial perivascular lymphocytic infiltrate with slightly increased interspersed mast cells and no



**Figure.** A, Water challenge test. B, Positive challenge test revealing a 2-mm erythematous wheal with 5% NaCl solution. C and D, Histopathology with hematoxylin and eosin shows perivascular and interstitial infiltration of lymphocytes and a slight increase in interspersed mast cells. The overlying epidermis remained unaffected.

involvement of the overlying epidermis (Figure). The patient received antihistamines (loratadine 10 mg), which were to be taken half an hour before contact with seawater. The response was favorable, with no further symptoms.

Reports of similar cases enable us to classify, describe, and manage this singular type of aquagenic urticaria. While the pathogenic process remains controversial, the reaction seems to depend exclusively on the salt content and/or osmolality [2]. Our data support an association with salt content rather than osmolality, as the challenge test with hypertonic glucose was negative. SDAU mainly affects young women, although it has also been reported in children who swam in the sea [2]. Lesions affect the collar area and lower part of the face, thus suggesting the role of a local factor in this region. Mast cell hyperreactivity in this region has been hypothesized [2]. It is noteworthy that in the present case, lesions were more extended, affecting the arms and back as well, perhaps indicating a more severe form of SDAU.

Management of SDAU is based on avoidance, by minimizing the duration of contact with seawater. Treatment consists of antihistamines taken half an hour before contact, although the response and effectiveness may vary between patients. Barrier creams, and even preparations containing capsaicin, can also be used [3,4]. SDAU is very rare, is probably underdiagnosed, and should be considered in all patients reporting small pruritic wheals after seabathing [2,3]. The histological features we report are nonspecific and comparable to features observed in other types of aquagenic urticaria described in the literature [4]. Therefore, we do not think that a histology work-up provides additional information in this subtype of aquagenic urticaria.

In conclusion, we report the case of a young woman who presented with a local aquagenic urticarial reaction caused exclusively by seawater that is a specific form of physical urticaria. Its characteristics were typical of aquagenic urticaria in its mode of presentation, the morphology of the lesions, and the histopathology findings. Future research is needed to

clarify the pathogenesis of this condition, which seems to be dependent on salt content. To our knowledge, this is the first report on the pathological, yet nonspecific, features of this form of aquagenic urticaria.

#### Funding

The authors declare that no funding was received for the present study.

#### Conflicts of Interest

The authors declare that they have no conflicts of interest.

#### References

- Vieira M, Rosmaninho I, Lopes I, Guilherme A, Moreira da Silva JP. Localized salt dependent aquagenic urticaria, a rare subtype of urticaria: a case report. *Eur Ann Allergy Clin Immunol.* 2018 May;50(3):141-4.
- Gallo R, Gonçalo M, Cinotti E, Cecchi F, Parodi A. Localized salt-dependent aquagenic urticaria: a subtype of aquagenic urticaria? *Clin Exp Dermatol.* 2013 Oct;38(7):754-7.
- Margerin F, Wettlé C, Merklen-Djafri C, Cribier B. Urticaire aquagénique localisée à l'eau de mer [Localized salt-dependent aquagenic urticaria: A case report]. *Ann Dermatol Venereol.* 2015 Dec;142(12):771-5.
- Fukayama M, Domoto Y, Sato S, Asano Y. Case of aquagenic urticaria: Case report and the results of histopathological examination. *J Dermatol.* 2021 Jan;48(1):88-91. doi:10.1111/1346-8138.15615. Epub 2020 Sep 17. PMID: 32940373.
- Napolitano M, Gallo R, Donnarumma M, Patruno C. Salt-dependent aquagenic urticaria in children: Report of two cases. *Pediatr Allergy Immunol.* 2018 May;29(3):324-6.

■ *Manuscript received April 13, 2021; accepted for publication July 8, 2021.*

**Jimena Laiseca García**

Hospital Universitario Fundación Alcorcón.  
Calle Budapest 1  
28922 Alcorcón (Madrid), Spain  
Allergy Unit  
E-mail: jimenalaiseca91@gmail.com